

ABSTRACTS



SVIN 2020
VIRTUAL CONFERENCE

NOVEMBER 18-21 • ON DEMAND SESSIONS AVAILABLE NOVEMBER 21-28

Platform 1

RNA Expression Identifying Ischemic Stroke In Acute Hospital Setting: Interim Analysis From BASE Clinical Trial

Daniel J Miller, MD¹

¹*Department of Neurology, Henry Ford Hospital, Detroit, Michigan, United States of America*

Introduction:

Blood testing panels in the acute setting to determine (i) if a stroke occurred, (ii) differentiation cause between cardioembolic stroke (CES) or large artery atherosclerosis stroke (LAA), and (iii) separately detect the presence of atrial fibrillation (AF) would be of significant clinical utility. Using the Biomarkers of Acute Stroke Etiology (BASE) trial (NCT02014896) dataset, our purpose was to utilize blood gene expression signatures as a panel approach for accurately identifying if a stroke occurred compared to a control subject, differentiating LAS from CES acute stroke etiologies, and separately identify AF.

Methods:

The BASE trial enrolled suspected stroke patients presenting to 20 hospitals within 24 hrs of symptom onset and age, race, gender, smoking, comorbidity match controls. Final gold standard diagnosis and stroke etiology were determined by an adjudication committee using all hospital data but blinded to RNA test results. Whole blood, obtained in PAX tubes, was frozen at -20C within 72 hrs and analyzed at a core lab (Ischemia Care, Dayton, OH) using Affymetrix HTA microarrays. Genes on the HTA microarray were filtered to eliminate genes with low expression or high CV (> 10%) when run on replicate samples leaving 9,513 potential signature genes. A two-way random forest classifier was built through cross validation of the training data resulting in three distinct diagnostic signatures based upon 23 genes for a panel of three separate tests.

Results:

This is a planned interim cohort study of the 1700 patients enrolled in the BASE trial that does not include lacunar strokes, cryptogenic strokes, TIA, or stroke mimics. Overall, 224 patients were enrolled with NIHSS \geq 5, 59 (26%) with LAS, 165 (74%) with CES, and 66 control subjects; 56% were male, and median (IQR) age was 72.9 yrs (63.7, 82.9). Median (IQR) time from symptom onset to blood collection was 487 (321, 1129) minutes. Coexistent pathology at presentation included atrial fibrillation 120 (54%), hypertension 186 (83%), hyperlipidemia 186 (48%), diabetes 74 (33%), and coronary artery disease 78 (35%). Patients were randomly divided into training (132) and validation (92). The diagnostic 12 gene signature results distinguished stroke from control; C-statistic 0.86, sensitivity of 0.91, specificity of .61. The diagnostic 3 gene signature results distinguished CES from LAA C-statistic 0.70, sensitivity of 0.85, specificity of 0.49. The diagnostic 8 gene signature results distinguished AF from (a) cardioembolic stroke not due to atrial fibrillation and (b) LAA, C-statistic 0.69, sensitivity of 0.70, specificity of 0.59.

Conclusions:

Targeted panels of RNA expression markers may be used together or separately to determine if a stroke occurred, stratification into CE and LAA causes, and presence of AF, and may have triage, interventional, therapeutic, and secondary prevention implications.

Keywords: Acute Stroke, Ischemic Stroke, Acute Ischemic Stroke Intervention, New Innovation, Inflammation

Financial Disclosures: The authors had no disclosures.

Grant Support: None.

Platform 2

Closely Sizing the Catheter to Vessel Enables Flow-Arrest and Flow-Reversal During Aspiration in the MCA

Raul G Nogueira, Professor¹, David Ryan, Mr², Liam Mullins, PhD³, John Thornton, FFR RCSI⁴, Sean G Fitzgerald, PhD²

¹Grady Memorial Hospital and Emory University, Atlanta, Georgia, United States of America; ²National University of Ireland Galway, Galway, Ireland; ³Perfuzo Ltd, Galway, Ireland; ⁴Beaumont Hospital, Dublin, Ireland

Introduction:

Delgado Almandoz et al. established catheter size as an independent predictor of successful revascularization (mTICI 2b/3) when using A Direct Aspiration First-Pass Thrombectomy (ADAPT) technique¹. Several studies have also demonstrated a trend towards higher rates of successful reperfusion with larger bore catheters and with larger catheter-to-vessel diameter ratio^{2, 3}. While Balloon Guide Catheters (BGCs) are used to achieve flow control and larger bore catheters are known to increase aspiration force, little is known about distal flow patterns during aspiration. Our objective was to establish flow patterns in terms of distal flow control using various aspiration catheter sizes, with and without the use of BGCs, in a representative in-vitro Circle of Willis model.

Methods:

The in-vitro model comprised a peristaltic pump, aortic arch and Circle of Willis (Vascular Simulations Inc). Pulse rate (72BPM), flow rate (720mL/min), and temperature (37°C) were controlled to replicate in-vivo conditions. Flow was measured continuously in the distal middle cerebral artery (MCA), 15cm distal to the catheter tip placed in the MCA-M1, using ultrasonic flow sensors (SONOFLOW CO.55/060, SONOTEC GmbH). Four aspiration catheters with increasing lumen size were evaluated; ACE 060 & ACE 064 (Penumbra), Sofia Plus (Microvention) and Millipede 088 (Perfuzo).

Results:

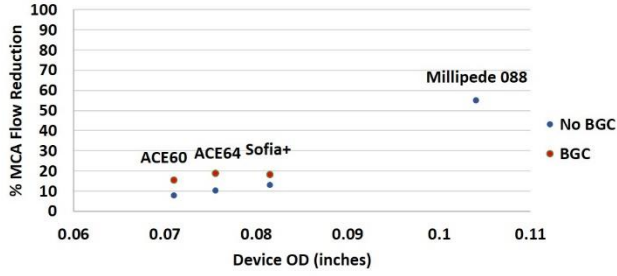
Flow Control: The Millipede 088 device results in a significantly larger reduction in MCA flow than all other aspiration catheters, even when they used with a BGC (Fig 1A). The use of a BGC leads to moderate reduction in the amount of flow in the MCA using the ACE 060, ACE 064 and Sofia Plus devices (Fig 1A).

Aspiration: Smaller catheters (ACE 060, ACE 064 and Sofia Plus) were unable to cause flow reversal in the distal MCA during aspiration (Fig 1 B&C). This means that there is still forward flow in the distal MCA during aspiration. Millipede 088 achieved complete flow reversal (-150ml/min) in the distal MCA during aspiration (Fig 1 D).

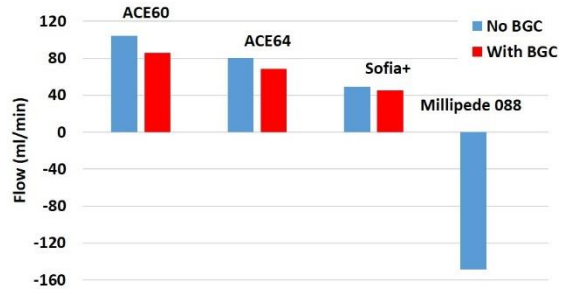
Conclusions:

Two key behaviours were observed. First, closely matching the catheter size to the vessel size allows the physician to control the degree of local flow arrest upon catheter insertion potentially negating the need for a BGC. Second, an 088 ID catheter enables significant flow reversal in the distal MCA during aspiration meaning that fluid is drawn from distal regions (distal aspiration) of the vasculature potentially enabling removal of distal clot emboli.

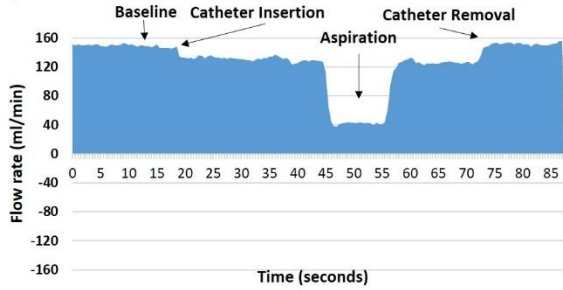
(A) Effect of Device OD on Flow Reduction Upon Placement of Catheter in MCA



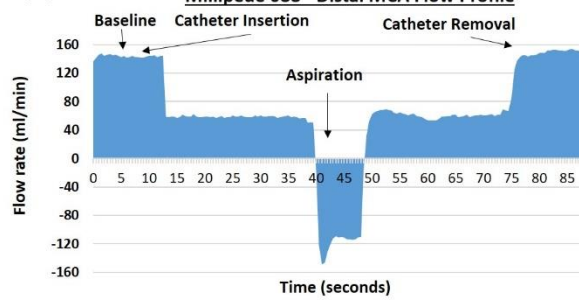
(B) Distal MCA Flow During Aspiration



(C) SOFIA Plus - Distal MCA Flow Profile



(D) Millipede 088 - Distal MCA Flow Profile



Keywords: Endovascular, New Technique, Balloon Guide Catheter, Neurointerventional Education,

Financial Disclosures: Perfuze Ltd - Stock Holder

Grant Support: This work was supported by the European Regional Development Enterprise Ireland grant number IP-2019-0865.

Platform 3

Long-term sided branch and perforator patency following Surpass flow diverter treatment in the SCENT Trial

Miklos Marosfoi, MD¹, Joost de Vries, MD², Peter T Kan, MD³, Ricardo A Hanel, MD⁴, Alexander L Coon, MD⁵, Philip M Meyers, MD⁶, Ajay K Wakhloo, MD¹

¹Department of Neurointerventional Radiology, Beth Israel Lahey Health, LHMC, Burlington, Massachusetts, United States of America; ²Department of Neurosurgery, Radboud University Medical Center, Nijmegen, Netherlands; ³Department of Neurosurgery Baylor College of Medicine, Houston, Texas, United States of America; ⁴Department of Neurosurgery, Jacksonville Baptist, Jacksonville, Florida, United States of America; ⁵Carondelet Neurological Institute, St. Joseph's Hospital, Tucson, Arizona, United States of America; ⁶Department of Neurosurgery Columbia University Medical Center, New York, New York, United States of America

Introduction:

Flow diverters (FD) have demonstrated to be highly effective in the treatment of intracranial aneurysms (IA). Multiple international studies have reported long-term occlusion rates between 85% and 95%. When treating IA, FD frequently does cover side branches or perforators. The fate of these covered vessels has not systematically been evaluated. We did a post-hoc data analysis of the SCENT trial and studied the long-term patency of these vessels and correlated it with clinical outcome.

Methods:

Subjects enrolled in the SCENT Trial with at least a 1-year angiographic follow-up were included. Patency of covered ophthalmic (OphA), anterior choroidal (AChA) and lenticulostriate arteries (LSA) were retrospectively analyzed on angiograms by two independent experienced neurointerventionalists. Images were available at the time of the procedure, at 6 months and at 1, 3, and 5 years. Flow within the side branches and perforators were scored as brisk, slow or absent. The artery was considered occluded if not discerned on follow-up imaging. Occlusions were classified as symptomatic or asymptomatic and changes in vessel patency over multiple follow-up angiographic studies were recorded.

Results:

A total of 171 subjects out of 180 enrolled in the Surpass SCENT trial with ICA aneurysms treated were available for assessment. Six-hundred fifteen angiograms were reviewed and scored. Follow-up angiography was available for: 153/171 (89.4%) of the patients at 1 year; 109/171 (63.7%) patients at 3 years; 29/171 (17.0%) patients at 5 years. In total 225 side branches or perforators were covered. OphA, AChA, and LSA were covered in 143 (84%), 63 (37%), and 19 (11%) of the subjects respectively. Ophthalmic arteries were patent at one year in 119/127 (93%) patients and the number of the compromised vessels remained the same at 3 years. One 1/51 (2%) AChA progressed to an occlusion at 3 years; one AChA with a slow flow - did not change over time. There were no LSA (0/19) occlusions at 1 and 3 years. From a total of 225 covered vessels, 7 (3.1%) were symptomatic, and were associated with the OphA [7/127 (5.5%)]; there were no symptoms associated with AChA or LSA. Clinical improvement of visual symptoms most likely secondary to an occlusion was observed in 1/7 (14.2%) patient. Vessel

occlusions or slow flow were present as early as 6 month on follow-up angiograms in 11/225 (4.8%) patients

Conclusions:

Our study shows that perforators covered by a Surpass FD have an excellent long-term patency and in case of an occlusion remain asymptomatic. However, ophthalmic artery occlusion may become symptomatic in a small number of subjects. Thus attention has to be paid to proper wall apposition and an effective dual antiplatelet therapy.

Keywords: Aneurysm, Aneurysm Embolization, Flow Diverter, Clinical Trial

Financial Disclosures: Consultant on a fee-per-hour basis for Stryker Neurovascular.

Grant Support: None.

Platform 4

Acute Stroke Management of Tandem Occlusions During Mechanical Thrombectomy Survey

Cynthia B Zevallos, MD¹, Mudassir Farooqui, MD, MPH¹, Darko Quispe-Orozco, MD¹, Alan Mendez Ruiz, MD¹, Andres Dajles, MS¹, Mary Patterson, BA², Hannah Slight, BA², Kristine Below, BS², Osama Zaidat, MD, MS², Santiago Ortega-Gutierrez, MD, MSc¹

¹University of Iowa, Iowa City, Iowa, United States of America; ²St. Vincent Hospital, Toledo, Ohio, United States of America

Introduction:

Tandem occlusion (TO) involves high-grade stenosis or occlusion of the extracranial internal carotid artery (eICA) with concomitant intracranial large vessel occlusion. These occlusions are associated with poor prognosis. However, the optimal management, especially, of the eICA lesion is still uncertain. We aimed to determine the current practice patterns among stroke experts involved in the treatment of TO during mechanical thrombectomy (MT).

Methods:

We distributed a 28-question online survey to experts affiliated with the Society of Vascular and Interventional Neurology, Society of Neurointerventional Surgery, Middle East North Africa Stroke and interventional neurotherapies organization, Grupo Sud-Americano de Neurorradiologia Intervencionista, Global Stroke Alliance, and stroke societies of South America. We sent out the survey in July 2020. After 2 months, data were extracted and analyzed using descriptive statistics.

Results:

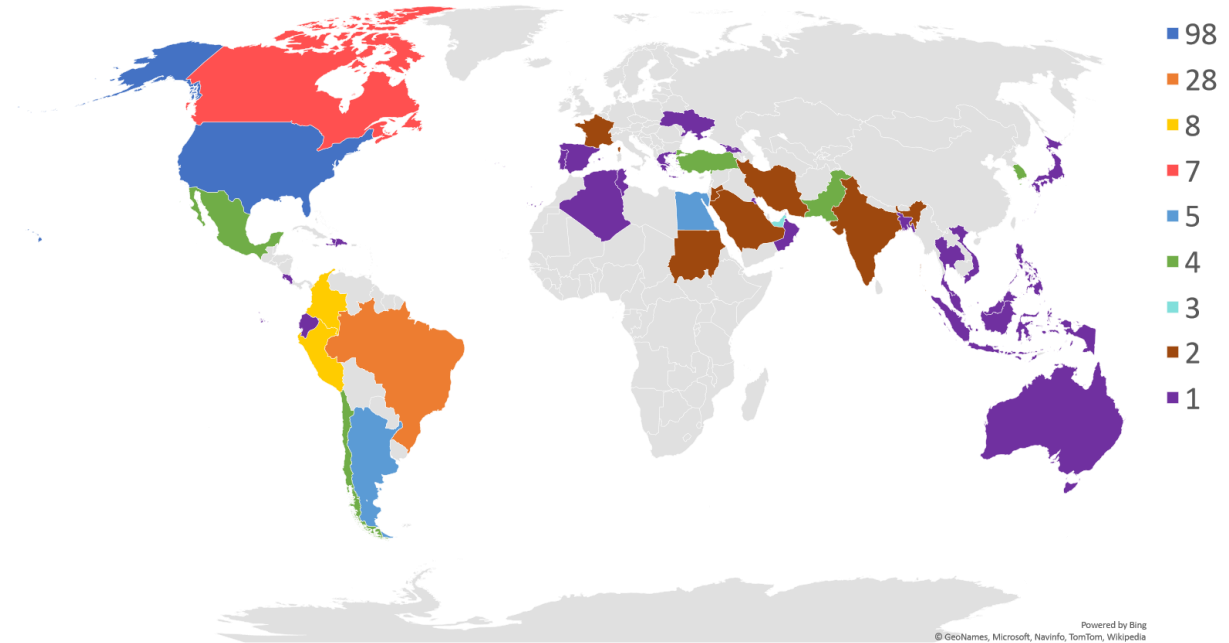
We obtained 220 responses from North America (48%), Latin America (28%), Asia (22%), and other countries (2%). The background training was interventional neurology (34%), neuroradiology (23%), neurosurgery (21%), stroke neurology (20%), and others (2%).

The preferred timing for eICA revascularization varied among respondents; 51% supported treatment in a subsequent procedure during the same hospitalization; 39%, acute treatment during MT; 9%, electively; and 1%, preferring conservative medical management. Regarding the endovascular approach, 57% preferred the retrograde approach (intracranial first); 30%, anterograde; and 12%, simultaneously. Angioplasty and stenting (41%), and balloon angioplasty and suction aspiration (38%) were the preferred techniques. The risk of intracerebral hemorrhage was the most compelling reason for not stenting acutely (68%). Most experts (70%) agreed that there is uncertainty about the optimal endovascular treatment of eICA lesions in TO. Similarly, 77% would include patients in RCT to better answer this question.

Conclusions:

Our survey exposed the high variability in current practice in the management of TO. Experts acknowledged the necessity of further evidence, and their willingness to participate in RCT evaluating the best treatment for the extracranial ICA lesion in patients with TO in the context of MT.

Geographic Distribution of Responses



Keywords: Carotid Stenting And Angioplasty, Mechanical Thrombectomy, Endovascular Therapy, Acute Ischemic Stroke Intervention

Financial Disclosures: The authors had no disclosures.

Grant Support: None.

Platform 5

Motor Neuroprosthesis Implanted using Cerebral Venography Improves Activities of Daily Living in Severe Paralysis

Thomas J Oxley, Associate Professor¹, Nicholas L Opie, Associate Professor¹, Peter E Yoo, Dr¹, Christin Bird, NP¹, J Mocco, Professor², Peter Mitchell, Professor³, Bruce Campbell, Professor³, Sarah Lee, Dr¹

¹University of Melbourne, Melbourne, Australia; ²Mount Sinai Hospital, New York City, United States of America; ³Royal Melbourne Hospital, Melbourne, Australia

Introduction:

An implantable Brain Computer Interface (BCI) may function as a motor neuroprosthesis to restore voluntary motor function in patients with severe paralysis due to brain, spinal cord, peripheral nerve or muscle dysfunction, but to date demonstrations have been limited in clinical translation. We report the home-based use of a fully-implanted mobile motor neuroprosthesis using a novel endovascular stent-electrode, avoiding craniotomy, to restore voluntary motor control of a patient by means of a personal computer.

Methods:

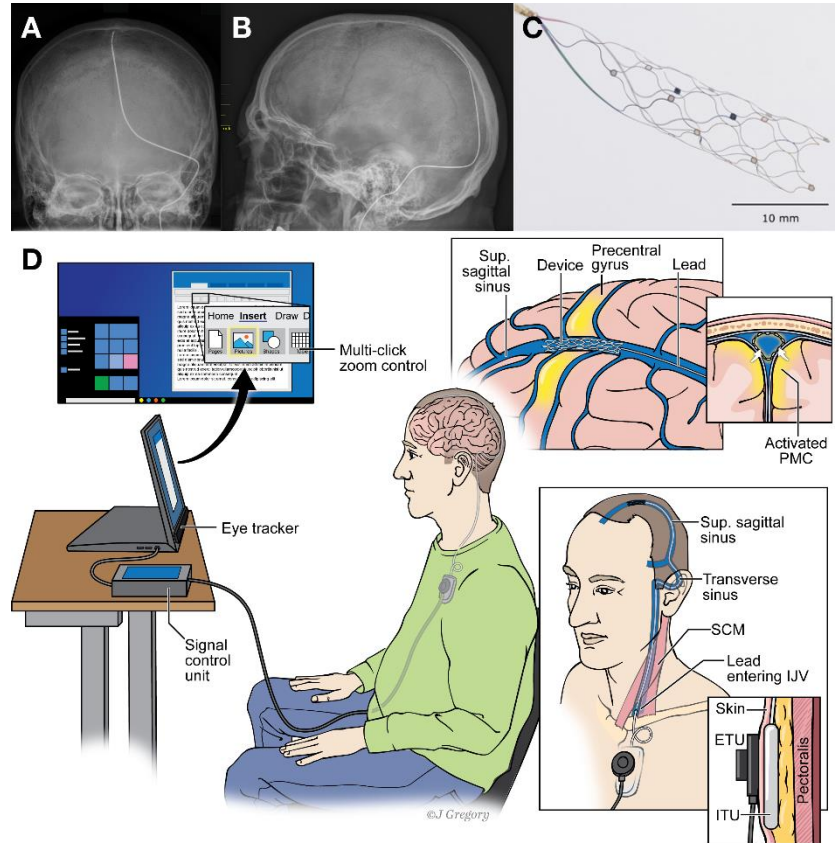
The participant was a 75-year-old man with flaccid paralysis in his upper limbs due to Motor Neuron Disease (MND). Prior to the study he was totally dependent on his caregiver wife for all Instrumental Activities of Daily Living (IADLs) including remote communication. Using routine cerebral venography techniques, the device was placed in the superior sagittal sinus adjacent to primary motor cortex and connected to a subcutaneous wireless transmitting unit. The participant underwent closed-loop training to convert electrocorticographic activity from attempted movements into multiple mouse-click actions for click-selection, used in conjunction with an eye-tracker for cursor-navigation, to control a personal computer. System control performance was measured as click-selection accuracy during activities of daily living tasks including typing and emailing. Other metrics included the correct characters per minute typing speed, information transfer rate in bits/min of the motor prosthesis alone and system overall, improvement in capacity to perform IADLs. The presence of device-related thrombus on computerised tomography (CT) venography was assessed at 3 months.

Results:

The participant was using the system at home and unsupervised on day 36 post system turn-on. During the typing task, a click-selection accuracy of $91.0 \pm 4.5\%$ was achieved across 748 trials, at 12.8 ± 1.1 correct characters per minute with predictive text disabled. An information transfer rate of 57.3 ± 5.9 bits/min and 15.1 ± 2.5 bits/min was achieved for the overall system and motor neuroprosthesis alone, respectively. He performed remote communication including messaging, shopping and managing his finances independently, resulting in a three-point increase in his Lawton IADL score. CT-venography study performed three months after implantation revealed no evidence of device migration, venous thrombosis or stenosis.

Conclusions:

A motor neuroprosthesis implanted via cerebral venography was used to restore voluntary motor function by way of computer control, which may represent a clinically feasible method of improving functional independence in patients with severe paralysis.



Keywords: Clinical Trial

Financial Disclosures: Stock in Synchron

Grant Support: This work was supported by research grants from US Defense Advanced Projects Agency (DARPA) Microsystems Technology Office contract N6601-12-1-4045; Office of Naval Research (ONR) Global N26909-14-1-N020; USA Department of Defense office of the Congressionally Directed Medical Research Programs (CDMRP), SC160158; Office of the Assistant Secretary of Defense for Health Affairs, Spinal Cord Injury Award Program W81XWH-17-1-0210; National Health and Medical Research Council of Australia (NHMRC) Grants GNT1161108, GNT1062532, GNT1138110; Australia Research Council (ARC) Linkage Grant LP150100038; Australian Federal Government, Department of Industry, Innovation and Science, GIL73654; Motor Neurone Disease Research Institute of Australia, GIA1844; and, Global Innovation Linkage Program, Australian Federal Government.

Platform 6

No delay in care of acute stroke due to the COVID19 pandemic: The SVIN collaboration

James E Siegler, MD¹, Alicia M Zha, MD², Alexandra Czap, MD², Santiago Ortega-Gutierrez, MD, MSc³, Mudassir Farooqui, MD³, David D Liebeskind, MD⁴, Shashvat Desai, MD⁵, Ameer Hassan, MD⁶, Amy Starosciak, PhD⁷, Italo Linfante, MD⁸, Vivek Rai, MD⁹, Jesse M Thon, MD¹, Ryna Then, MD¹, Mark E Heslin, BS¹⁰, Lauren Thau, BS¹⁰, Priyank Khandelwal, MD¹¹, Mahmoud H Mohammaden, MD, MSc¹², Diogo Haussen, MD¹², Raul G Nogueira, MD¹², Dinesh V Jillella, MD¹³, Artem Kaliaev, MD¹⁴, Thanh N Nguyen, MD¹⁴, Osama Zaidat, MD, MBBs, MSc¹⁵, Tudor G Jovin, MD¹, Ashutosh Jadhav, MD, PhD⁵

¹Cooper Neurologic Institute, Cooper University Hospital, Camden, New Jersey, United States of America;

²University of Texas Health Science Center, Houston, Texas, United States of America; ³Department of Neurology, University of Iowa Hospitals and Clinics, Iowa City, Iowa, United States of America; ⁴Ronald Reagan University of California at Los Angeles, Los Angeles, California, United States of America;

⁵University of Pittsburgh Medical Center Mercy Hospital, Pittsburgh, Pennsylvania, United States of America; ⁶University of Texas Rio Grande Valley, Valley Baptist Medical Center, Harlington, Texas, United States of America; ⁷Center for Research, Baptist Health South Florida, Coral Gables, Florida, United States of America; ⁸Baptist Health South Florida, Coral Gables, Florida, United States of America; ⁹OhioHealth Neuroscience Center, Riverside Methodist Hospital, Columbus, Ohio, United States of America; ¹⁰Cooper Medical School of Rowan University, Camden, New Jersey, United States of America; ¹¹Robert Wood Johnson University Hospital, New Brunswick, New Jersey, United States of America; ¹²Marcus Stroke & Neuroscience Center, Grady Memorial Hospital, Atlanta, Georgia, United States of America; ¹³Emory University Hospital, Atlanta, Georgia, United States of America; ¹⁴Boston Medical Center, Boston, Massachusetts, United States of America; ¹⁵Mercy Health St. Vincent Hospital, Toledo, Ohio, United States of America

Introduction:

The pandemic caused by the novel coronavirus disease 2019 (COVID-19) has led to an unprecedented paradigm shift in medical care. We sought to evaluate whether the COVID-19 pandemic may have contributed to delays in acute stroke management at Comprehensive Stroke Centers (CSCs).

Methods:

Pooled clinical data of consecutive adult stroke patients from 12 U.S. CSCs (1/1/2019-5/31/2020) were queried. The rate of thrombolysis for non-transferred patients within the Target: Stroke goal of 60min was compared between patients admitted 3/1/2019-5/31/2019 (pre-COVID-19) and 3/1/2020-5/31/2020 (COVID-19). The time from arrival to imaging and treatment with thrombolysis or thrombectomy, as continuous variables, were also assessed.

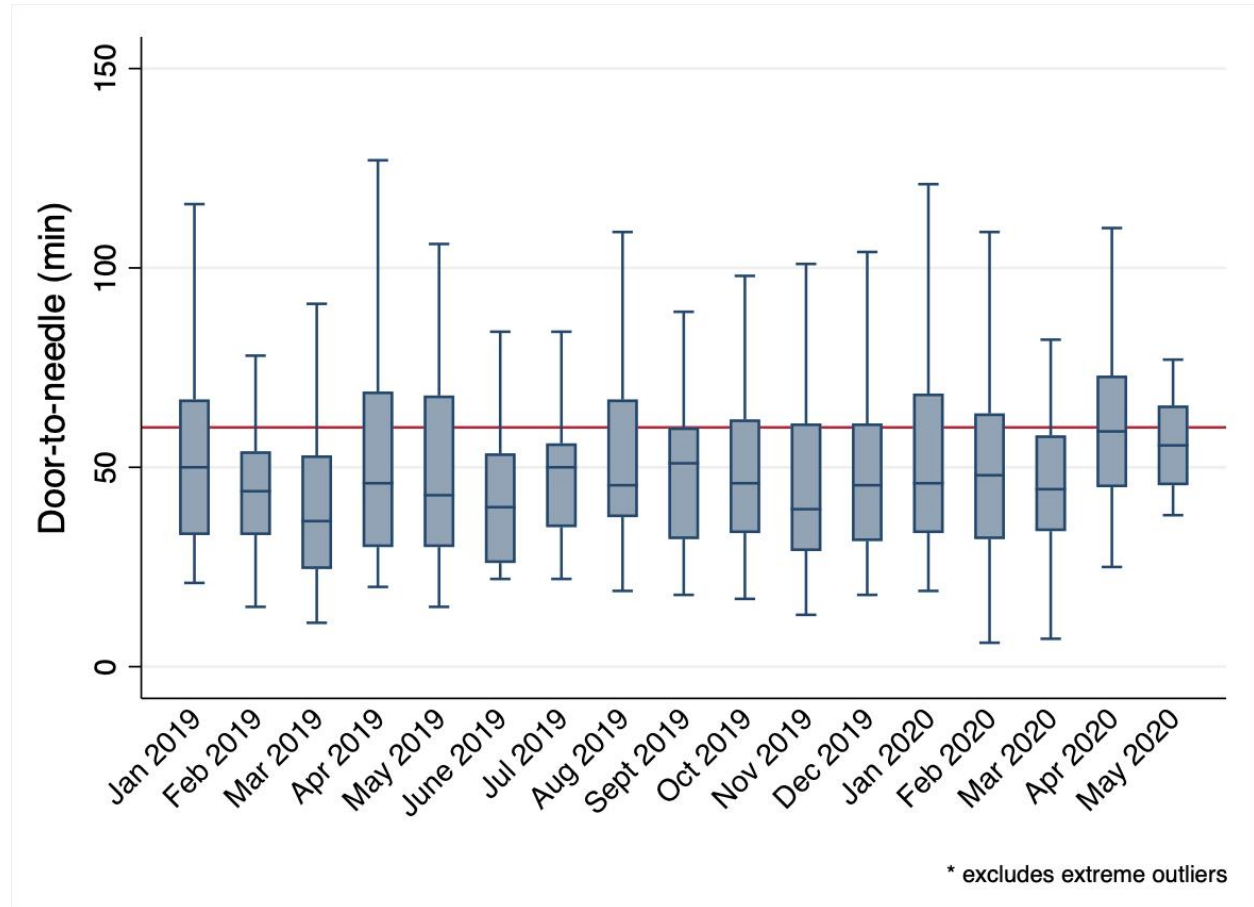
Results:

Of the 7906 patients included, 1319 were admitted pre-COVID-19 and 933 were admitted during COVID-19, 15% of whom underwent intravenous thrombolysis. There was no difference in the rate of thrombolysis within 60 minutes during the COVID-19 period (OR 0.88, 95%CI 0.42-1.86, p=0.74), despite adjustment for variables associated with earlier treatment (adjusted OR 0.82, 95%CI 0.38-1.76, p=0.61). A non-significantly longer delay to thrombolysis was observed during the COVID-19 period (median 49 vs. 43 min, p=0.42). This delay remained non-significant after multivariable adjustment (p=0.63), while

the only independent predictor of delayed treatment time was the use of emergency medical services (adjusted $\beta=-6.93$, 95%CI -12.83 - -1.04, $p=0.03$). There was no significant delay from hospital arrival to imaging in all patients, or imaging to skin puncture in patients who underwent thrombectomy.

Conclusions:

There was no independent effect of the COVID-19 period on delays in acute care with respect to thrombolysis or thrombectomy in this multicenter observational cohort. Further studies are warranted to externally validate these findings, and determine if site volume or center accreditation may mediate a collateral effect of the pandemic on stroke care paradigms.



Keywords: Thrombolytics, Mechanical Thrombectomy, Acute Ischemic Stroke Intervention,

Financial Disclosures: The authors had no disclosures.

Grant Support: None.

Platform 7

Safety and Efficacy of Intra-arterial Mesenchymal Stem Cell Therapy in a Canine Model of Stroke

Roshni Thakkar, Assistant Professor¹, Mitsuyoshi Watanabe, Fellow², Karen Bates, Clinical Research Manager³, Luis Guada, Resident⁴, Kengo Nishimura, Research Fellow⁴, Vasu Saini, Fellow¹, Kevin Ramdas, Researcher⁴, Charif Sidani, Assistant Professor⁴, Aisha Khan, Director⁵, Joshua Hare, Professor⁵, Dileep Yavagal, Professor⁴

¹Department of Neurology, Miller School of Medicine, University of Miami, Miami, Florida, United States of America; ²Department of Neurosurgery, Jikei University School of Medicine, Tokyo, Japan; ³Rapid Medical Ltd, Miami, Florida, United States of America; ⁴University of Miami, Miami, Florida, United States of America; ⁵Interdisciplinary Stem cell Institute, University of Miami, Miami, Florida, United States of America

Introduction:

Therapeutic advances for ischemic stroke in the past few decades include intravenous tissue plasminogen activator administered within 4.5 hours, and mechanical thrombectomy up to 24 hours after stroke onset. Although this has led to a 30% increase in survival rates after stroke, more than 50% of stroke survivors are chronically disabled. Hence, novel more effective therapies are needed. Research in the last 2.5 decades has shown great promise in the use of cell-based therapies for stroke. Our group and others have shown the safety and efficacy of intra-arterial (IA) stem cell therapy in a rodent model of stroke and safety in a clinical study, RECOVER-Stroke. The IA route of delivery is minimally invasive and allows for targeted delivery of cells. In order to further advance the translation of IA cell delivery, we pursued a large animal pre-clinical project to study the safety, efficacy, and optimum dosage of IA mesenchymal stem cell delivery in a canine model of stroke. The canine model is well-suited for translation due to its gyrencephalic brain and a white to gray matter ratio that is similar to humans. The selection of this model is a crucial step in pre-clinical translational research to better optimize stem cell therapy for stroke, thereby leading to effective clinical translation. The objectives of this study were: 1) Develop a reproducible endovascular model of canine focal cerebral ischemia with reversible middle cerebral artery occlusion (rMCAO). 2) Test the safety, efficacy and optimal dosage of intra-arterial allogenic mesenchymal stem cell (MSCs) therapy in this canine stroke model.

Methods:

An endovascular canine rMCAO model using retractable platinum coil for 60-120 min was established. At 48 hr post-rMCAO, allogenic male canine MSCs (10-80 million) were delivered using a 0.0165" microcatheter in the ipsilateral upper cervical internal carotid artery of female canine subjects. Serial MRIs and neurological deficit scoring (NDS) were performed over 30 days. Animals were euthanized at 15-30 d post-rMCAO and brains were harvested for histology and molecular analyses.

Results:

Our study yielded a highly reproducible, minimally invasive endovascular large animal model of rMCAO stroke confirmed using imaging, histopathological and behavioral testing. Significantly higher infarct volume reduction was seen at IA 10 million and 40 million doses in dose dependent manner as compared to the control group. This correlated with improvement in focal neurological deficits with faster and more complete recovery in the treated groups as compared to controls. Delivery of high dose,

80 m cells, led to worsened outcome and new infarct lesions 4 days post-injection with spontaneous resolution at day 15 were observed.

Conclusions:

In conclusion, our study suggests that intra-arterial delivery of MSC at 48 hour post-stroke is safe and effective for stroke recovery in a dose-dependent manner up to 40 million MSCs. IA delivery of 80 million MSCs is toxic leading to new severe cerebral ischemia from the cell dose. Collectively, our study has established a successful preclinical canine model of stroke and reported dose-dependent efficacy of IA MSC therapy after stroke.

Keywords: Acute Stroke, Endovascular Therapy, Ischemic Stroke, Stem Cell Therapy

Financial Disclosures: The authors had no disclosures.

Grant Support: None.

Platform 8

Thrombectomy with a Novel Device: Initial Experience with a Catheter Featuring a Self-Expanding Funnel

Marc Ribo, MD FEBNI¹, Alejandro Tomasello, MD¹, David Hernandez, MD¹, Carlos Piñana, MD¹, Manuel Requena, MD¹, David Liebeskind, MD², Adnan Siddiqui, MD³, Tommy Andersson, MD⁴, Raul Nogueira, MD⁵, Christophe Cognard, MD⁶, Tudor Jovin, MD⁷, Marc Ribo, MD FEBNI¹

¹Hospital Vall d'Hebron, Barcelona, Spain; ²UCLA Comprehensive Stroke Center, Los Angeles, United States of America; ³State University of New York at Buffalo, Buffalo, New York, United States of America; ⁴Karolinska Univ Hospital, Stockholm, Sweden; ⁵Emory, Atlanta, United States of America; ⁶CHU de Toulouse, Toulouse, France; ⁷Cooper University Hospital, Camden, New Jersey, United States of America

Introduction:

The ANA™ thrombectomy system is a novel stroke thrombectomy device comprising a self-expanding funnel designed to reduce clot fragmentation by locally restricting flow while becoming as wide as the lodging artery. Once deployed, the funnel catheter allows distal aspiration in combination with a stent retriever (SR) to mobilize the clot into the funnel where it remains copped during extraction. We investigate safety and efficacy of the funnel catheter in a first-in-man study.

Methods:

Prospective data was collected on 35 consecutive patients treated as first line with the funnel catheter at a single center. Outcome measures included per-pass reperfusion scores assessed at an independent central corelab, symptomatic intracerebral hemorrhage (sICH), NIHSS at day 5 and mRS at 90 days.

Results:

Median presenting NIHSS was 12 (9-18). Sites of primary occlusion were: 5 ICA, 15 M1-MCA, 15 M2-MCA. Primary performance endpoint, mTICI 2b-3 within 3 passes without rescue therapy was achieved in 91.4% (n=32) of patients; rate of complete recanalization (mTICI 2c-3) was 65.7%. First pass complete recanalization rate was 42.9% and median number of study device passes 1 (IQR:1-2). In 17.1% (n=6) rescue treatment was used; median number of rescue passes was 2 (1-7), leading to a final mTICI2b-3 rate of 94.3% (n=33). There were no device related serious adverse events and the rate of sICH was 5.7%(n=2). At 5 days median NIHSS was 1 (IQR 1-6) and 90 days mRS 0-2 was achieved in 60% of patients

Conclusions:

In this initial clinical experience, the self-expanding funnel catheter achieved a high rate of complete recanalization with good safety profile and favorable 90 days clinical outcomes.

Table 1

Study name	# of pts	Device	mTICI 2b/3			mTICI 2c/3			mTICI 3			Sudden Recanalisation	mRS 0-2 at 90 days
			First pass	Last pass with study device	Final	First pass	Last pass with study device	Final	First pass	Last pass with study device	Final		
Hermes (7)	634	Multiple			75.4%			31.4%			8.6%		46.0%
Arise II (20)	227	Embotrap	51.5%	80.2%	92.5%	40.1%	64.8%	75.8%	30%	44%	52%		67.3%
Sudden Rec (21).	609	Multiple	41%	NA	83.6%						45.6%	62.1%	44.8%
Solonda (ITT)	35	ANA + SR	57.1%	91.4%	94.3%	42.9%	65.7%	74.3%	40%	51.4%	54.3%	82.9%	60%

Table 1: Recanalization rates in the Solonda study and other published series. (pts: patients, Rec: Recanalization, ITT: Intention To Treat, SR: Stent retriever)

Keywords: Endovascular Therapy, Acute Ischemic Stroke Intervention, New Innovation

Financial Disclosures: Marc Ribo is the co-founder of Anaconda Biomed

Grant Support: None.

Platform 9

Prospective Post-Market Safety Study Of The Apollo Microcatheter For Onyx Embolization Of Brain Arteriovenous Malformations

Philip M Meyers, MD¹, Johanna T Fifi, MD², Kevin M Cockroft, MD³, Timothy R Miller, MD⁴, Curtis A Given, MD⁵, Ali R Zomorodi, MD⁶, Bharathi D Jagadeesan, MD⁷, Maxim Mokin, MD, PhD⁸, Peter Kan, MD⁹, Tom L Yao, MD¹⁰, Orlando Diaz, MD¹¹, Daniel Huddle, DO¹², Richard J Bellon, MD¹³, Joshua Seinfeld, MD¹⁴, Adam Polifka, MD¹⁵, David Fiorella, MD, PhD¹⁶, Rohan V Chitale, MD¹⁷, Peter Kvamme, MD¹⁸, Jay T Morrow, MD¹⁹, Justin Singer, MD¹⁹, Ajay K Wakhloo, MD, PhD²⁰, Ajit S Puri, MD²¹, Vivek R Deshmukh, MD²², Ricardo A Hanel, MD, PhD²³, L. Fernando Gonzalez, MD²⁴, Henry Woo Woo, MD²⁵, Mohammad Ali Aziz-Sultan, MD²⁶

¹Departments of Radiology and Neurological Surgery, Columbia University, New York, New York, United States of America; ²Icahn School of Medicine, Mount Sinai Medical Center, New York, New York, United States of America; ³Pennsylvania State University College of Medicine, Hershey, Pennsylvania, United States of America; ⁴University of Maryland Medical Center, Baltimore, Maryland, United States of America; ⁵Baptist Health Lexington, Lexington, Kentucky, United States of America; ⁶Duke University Medical Center, Durham, North Carolina, United States of America; ⁷University of Minnesota, Minneapolis, Minnesota, United States of America; ⁸University of South Florida, Tampa, Florida, United States of America; ⁹Baylor College of Medicine, Houston, Texas, United States of America; ¹⁰Norton Healthcare, Louisville, Kentucky, United States of America; ¹¹Houston Methodist Hospital, Houston, Texas, United States of America; ¹²UCHealth Medical Group (UCHMG), Colorado Springs, Colorado, United States of America; ¹³Swedish Medical Center, Englewood, Colorado, United States of America; ¹⁴University of Colorado Medical Center, Aurora, Colorado, United States of America; ¹⁵University of Florida, Gainesville, Florida, United States of America; ¹⁶Stony Brook University Hospital, Stony Brook, New York, United States of America; ¹⁷Vanderbilt University Medical Center, Nashville, Tennessee, United States of America; ¹⁸University of Tennessee Medical Center, Knoxville, Tennessee, United States of America; ¹⁹Michigan State University & Spectrum Health, Grand Rapids, Michigan, United States of America; ²⁰Beth Israel Lahey Health, Tufts School of Medicine, Burlington, Massachusetts, United States of America; ²¹University of Massachusetts Medical Center, Worcester, Massachusetts, United States of America; ²²Providence Brain and Spine Institute, Portland, Oregon, United States of America; ²³Baptist Health Research Institute, Lyrly Neurosurgery, Jacksonville, Florida, United States of America; ²⁴Duke University, Durham, North Carolina, United States of America; ²⁵Zucker School of Medicine at Hofstra/Northwell Health, Manhasset, New York, United States of America; ²⁶Brigham and Women's Hospital, Harvard Medical School, Boston, Massachusetts, United States of America

Introduction:

The Onyx™ Liquid Embolization System (Onyx) allows slow and controlled embolization of brain arteriovenous malformations (bAVM). However, catheter retention and difficulty in retrieval have been reported with Onyx. The Apollo™ Onyx Delivery Microcatheter (Apollo) is a detachable distal tip catheter designed to aid catheter retrieval during Onyx embolization. This study evaluates the safety of the Apollo device for delivery of Onyx during embolization of bAVMs.

Methods:

This prospective, non-randomized, single-arm, multi-center, post-market study included subjects with a bAVM who underwent Onyx embolization with Apollo between May 2015 and February 2018. Patients were followed-up at 30 days and 12 months. The primary endpoint included catheter-related adverse events (AEs) at 30 days, such as unintentional tip detachment or malfunction with clinical sequelae, or retained catheter. Secondary endpoints included unintentional and intentional catheter tip detachment, migration of the retained catheter tip post-embolization, and catheter/tip leakage from the detachment zone. Procedure-related AEs (untoward medical occurrence, disease, injury, or clinical signs) and serious AEs (life-threatening illness/injury, permanent physiological impairment, hospitalization, or requiring intervention) were also recorded at 30 days and 12 months post-embolization. A Clinical Events Committee (CEC) adjudicated all AEs and serious AEs, and an Imaging Core Laboratory assessed device migration.

Results:

A total of 142 embolization procedures with 201 Apollo devices were performed in 112 subjects (mean age 44.1±17.6 years, 56.3% male). A total of 59 (52.7%) AVMs were located on the left side of the brain, most frequently in the parietal lobe (39/112, 34.8%). Nidus size was small (<3 cm) in 60 (53.6%) subjects, medium (3-6 cm) in 47 (42.0%) and large (>6 cm) in 5 (4.5%). Spetzler-Martin grades III and IV rate was (45.5%), and the mean Spetzler-Martin grade was 2.38. The primary endpoint was not observed (0/112, 0%). Through 30-day follow-up, unintentional catheter tip detachment was observed in 1/112 (0.9%) subject, and intentional catheter tip detachment was observed in 68 (60.7%) subjects. Procedure-related AEs were observed in 31 (27.7%) subjects, including serious AEs in 12 (10.7%), and non-serious AEs in 26 (23.2%) subjects. Catheter/tip leakage from detachment zone was not observed at 30 days. Migration of the retained catheter tip post embolization was not observed at 30-day or 12-month follow up. At 12 months, AEs were reported in a total of 68 (60.7%) subjects; serious AEs occurred in 39 (34.8%) subjects and non-serious AEs in 50 (44.6%) subjects. Device-related AEs occurred in 2 (1.8%) subjects and procedure-related in 33 (29.5%) subjects. At 12-months, device-related neurological death was reported in 2 (1.8%) subjects, and there were 3 (2.7%) mortalities, none of which were device-related.

Conclusions:

This study demonstrates the safety of Apollo for Onyx embolization of bAVMs, with a low rate of unintentional catheter tip detachment that was not associated with clinical sequelae.

Keywords: Avm Embolization

Financial Disclosures: The authors had no disclosures.

Grant Support: This study was sponsored by Medtronic, Inc.

Platform 10

Safety and Efficacy of the Penumbra System for Large Vessel Occlusion Thrombectomy: The COMPLETE Registry

Osama O Zaidat, MD, MS, FAHA, FAAN, FSVIN¹, Johanna T Fifi, MD, FAHA, FSVIN², Ameer E Hassan, DO, FAHA, FSVIN³

¹Mercy Health St. Vincent Medical Center, Toledo, Ohio, United States of America; ²Icahn School of Medicine at Mount Sinai, New York, New York, United States of America; ³University of Texas Rio Grande Valley at Valley Baptist Medical Center, Harlingen, Texas, United States of America

Introduction:

The purpose of this registry was to evaluate the safety and efficacy of a mechanical thrombectomy system in patients with large vessel occlusion acute ischemic stroke (LVO-AIS) in a real-world setting.

Methods:

The global prospective multicenter COMPLETE registry enrolled LVO-AIS patients aged ≥ 18 years with pre-stroke modified Rankin Scale (mRS) 0-1 who underwent mechanical thrombectomy using the Penumbra System with or without the 3D Revascularization Device (Penumbra, Inc). The primary safety endpoint was 90-day all-cause mortality. The primary efficacy endpoints were successful post-procedure angiographic revascularization (modified thrombolysis in cerebral infarction [mTICI] $\geq 2b$) and 90-day functional outcome (mRS 0-2). Secondary endpoints included incidence of device- or procedure-related serious adverse events (SAEs), occurrence of embolization in previously uninvolved or new territories (ENT), and occurrence of symptomatic intracranial hemorrhage (sICH) at 24 hours. Descriptive statistics were calculated for all subjects and for 3 cohorts: Anterior circulation LVO with ASPECTS ≥ 6 , Anterior circulation LVO with ASPECTS < 6 , and Posterior circulation LVO. A core lab evaluated imaging findings and independent medical reviewers reviewed and adjudicated clinical events related to the safety endpoints.

Results:

From July 2018 to October 2019, 650 patients were enrolled across 42 centers (29 in the US and 13 in Europe). Baseline characteristics and endpoints are available in the table.

Conclusions:

Mechanical thrombectomy with the Penumbra System in anterior and posterior circulations appears to be safe and effective, resulting in high rates of successful revascularization across all 3 cohorts.

Baseline Characteristics	All Subjects (N=650)	Anterior circulation ASPECTS ≥ 6 (N=525)	Anterior circulation ASPECTS < 6 (N=72)	Posterior circulation (N=51)
Age, years	68.4 (14.2)	69.1 (14.0)	64.6 (14.6)	66.0 (14.8)
Female	54.0% (351/650)	56.8% (298/525)	44.4% (32/72)	39.2% (20/51)
NIHSS	15.0 [9.0, 20.0]	14.0 [9.0, 20.0]	18.0 [15.5, 22.0]	12.0 [5.0, 18.0]
ASPECT Score	8.0 [7.0, 9.0]	8.0 [7.0, 9.0]	4.0 [3.0, 5.0]	N/A
pc-ASPECT Score	9.0 [8.0, 10.0]	N/A	N/A	9.0 [8.0, 10.0]
IV tPA pre-procedure	49.2% (320/650)	50.1% (263/525)	58.3% (42/72)	29.4% (15/51)

Time from onset to admission, hours	3.2 [1.4, 6.3]	3.0 [1.3, 6.0]	4.0 [1.9, 6.8]	5.1 [1.5, 8.2]
Aspiration only as frontline treatment	62.9% (409/650)	63.0% (331/525)	59.7% (43/72)	64.7% (33/51)
Combined technique with 3D and Penumbra Reperfusion Catheter as frontline treatment	35.2% (229/650)	35.4% (186/525)	38.9% (28/72)	29.4% (15/51)
Primary & Secondary Endpoints				
90-day mRS 0-2	55.8% (342/613)	59.6% (295/495)	32.3% (21/65)	49.0% (25/51)
mTICI 2b-3 post-procedure	87.8% (571/650)	87.4% (459/525)	87.5% (63/72)	92.2% (47/51)
90-day all-cause mortality	15.5% (101/650)	14.1% (74/525)	25.0% (18/72)	17.6% (9/51)
Device-related SAE, ≤ 24 hrs	0.6% (4/650)	0.6% (3/525)	1.4% (1/72)	0.0% (0/51)
Procedure-related SAE, ≤ 24 hrs	5.8% (38/650)	5.1% (27/525)	9.7% (7/72)	7.8% (4/51)
ENT, at end of procedure	2.8% (18/650)	2.5% (13/525)	6.9% (5/72)	0.0% (0/51)
sICH, ≤ 24 hrs	3.8% (25/650)	3.8% (20/525)	5.6% (4/72)	2.0% (1/51)
Other Outcomes of Interest				
mTICI 2b-3 post-first pass	56.8% (368/648)	56.4% (295/523)	47.2% (34/72)	72.5% (37/51)
Vessel Perforation	0.3% (2/650)	0.4% (2/525)	0.0% (0/72)	0.0% (0/51)
Vessel Dissection	0.9% (6/650)	1.0% (5/525)	0.0% (0/72)	2.0% (1/51)

Mean (SD), Median [IQR], % (n/N)

Two patients were missing baseline ASPECT scores and therefore not assigned to any cohort

Keywords: Acute Ischemic Stroke Intervention, Endovascular, Mechanical Thrombectomy, Penumbra, Clinical Trial

Financial Disclosures: Grant/research/other financial or material support: Genentech, Medtronic Neurovascular, Stryker; Consultant: Codman, Medtronic Neurovascular, National Institutes of Health StrokeNet, Penumbra, Stryker. Ownership interest: Galaxy Therapeutics, LLC

Grant Support: None.

Platform 11

Neuroform Atlas™ Stent Assisted Posterior Circulation Aneurysm Coiling: Primary Outcomes

Brian T Jankowitz, MD¹, Ashutosh P Jadhav, MD PhD², Tudor G Jovin, MD³, Justin F Fraser, MD⁴, Abdulnasser Alhajeri, MD⁵, Ricardo A Hanel, MD⁶, Eric a Sauvageau, MD⁶, Amin Aghaebrahim, MD⁶, Donald Frei, MD⁷, David Loy, MD⁸, Ajit Puri, MD⁹, Adel Malek, MD¹⁰, Ajith Thomas, MD¹¹, Lin Eugene, MD¹², Gabor Toth, MD¹³, Richard Crowley, MD¹⁴, Demetrius Lopes, MD¹⁵, Adam Arthur, MD, MPH¹⁶, John Reavey-Cantwell, MD¹⁷, Steven W Hetts, MD¹⁸, Osama O Zaidat, MD¹²

¹Cooper Neurological Institute, Camden, New Jersey, United States of America; ²BNI, Phoenix, Arizona, United States of America; ³CNI, Camden, New Jersey, United States of America; ⁴UK, Lexington, Kentucky, United States of America; ⁵Riverside Methodist, Columbus, Ohio, United States of America; ⁶Lyerly Neurosurgery, Jacksonville, Florida, United States of America; ⁷RAI, Englewood, Colorado, United States of America; ⁸UVA, Charlottesville, Virginia, United States of America; ⁹UMass, Worcester, Massachusetts, United States of America; ¹⁰Tufts, Boston, Massachusetts, United States of America; ¹¹BID, Boston, Massachusetts, United States of America; ¹²Mercy Health St. Vincent Medical Center, Toledo, Ohio, United States of America; ¹³Cleveland Clinic, Cleveland, Ohio, United States of America; ¹⁴Rush, Chicago, Illinois, United States of America; ¹⁵Advocate, Chicago, Illinois, United States of America; ¹⁶Semmes-Murphey Clinic, Memphis, Tennessee, United States of America; ¹⁷VCU, Richmond, Virginia, United States of America; ¹⁸UCSF, San Francisco, California, United States of America

Introduction:

Stent-assisted coil embolization using the Neuroform Atlas™ Stent System has shown promising results. Here, we present the primary efficacy and safety results of the posterior circulation cohort in the ATLAS Investigational Device Exemption (IDE) Trial.

Methods:

ATLAS IDE is a prospective, multicenter, single-arm, open label study of unruptured wide-necked (neck ≥ 4 mm or dome-to-neck ratio < 2 mm) intracranial aneurysms in the posterior circulation treated with the Neuroform Atlas Stent and approved coils in the United States. The primary efficacy endpoint was complete aneurysm occlusion (Raymond Class 1) on 12-month DSA, in the absence of retreatment, or parent artery stenosis $> 50\%$ at the target location. The primary safety endpoint was any major stroke or ipsilateral stroke or neurological death within 12 months. Adjudication of the primary endpoints was performed by an imaging core laboratory and the ATLAS Clinical Events Committee.

Results:

The ATLAS trial enrolled and treated 116 patients at 24 medical centers with unruptured wide-necked posterior circulation aneurysms. The mean aneurysm size was 7.1 ± 3.0 mm, mean neck width was 4.7 ± 1.7 mm, and mean dome-to-neck ratio was 1.2 ± 0.3 with a previous rupture in 11.2% (13/116). The most frequent aneurysm location was the Basilar Apex (88/116; 75.9%). Stents were placed in the anticipated anatomic location in 116/116 (100%) patients. Of the 116, 82.0% underwent complete DSA follow-up at 12 months; 82 (86.3%) had complete aneurysm occlusion (Raymond class I). On follow up at 6 or 12 months, 18 (18.9%) patients progressed to better occlusion (Raymond–Roy class I or II), with 16 (16.8%) moving from II to I, and 2 (2.1%) from III to I. Ten patients exhibited recanalization; 6 from I to II, 1 from I to III, and 3 patients regressed from II to III. Primary Effectiveness Outcome at 12 months

defined as Grade 1 Raymond Class in the absence of retreatment, or parent artery stenosis (>50%) at the target location was 77.2% [67.2%,87.3%]. Overall, 3.4% (4/116) of patients experienced a major ipsilateral stroke, although 2 resolved with no residual symptoms and only 1 was considered disabling. Within 12 months, 7.8% (9/116) of patients underwent re-treatments (8) or a pre-planned staged procedure (1).

Conclusions:

In the ATLAS IDE posterior circulation cohort pre-market approval study, the Neuroform Atlas™ stent with adjunctive coiling demonstrated high rates of long-term complete occlusion at 12 months, with excellent technical success and safety.

Keywords: Aneurysm, Aneurysm Embolization, Coiling, Endovascular Therapy, Stent Assisted

Financial Disclosures: Consultant for Stryker

Grant Support: None.

Platform 12

Stroke etiologies in patients with COVID-19: The SVIN COVID-19 Multinational Registry.

Maria E Ramos-Araque, MD,PhD¹, James E Siegler, MD², Marc Ribo, MD, PhD³, Manuel Requena, MD, PhD³, Cristina López, MD⁴, Mercedes de Lera, MD⁴, Juan F Arenillas, MD, PhD⁴, Isabel Hernández Pérez, MD⁴, Beatriz Gómez-Vicente, RN⁴, Blanca Talavera, MD⁴, Pere Cardona Portela, MD⁵, Ana Nuñez Guillen, MD⁵, Xabier Urra, MD,PhD⁶, Laura Llull, MD,PhD⁶, Arturo Renú, MD,PhD⁶, Thanh N Nguyen, MD⁷, Dinesh Jillela, MD⁸, Fadi Nahab, MD⁸, Raul Noguerira, MD⁹, Diogo Haussen, MD⁹, Ryna Then, MD², Jesse M Thon, MD², Luis Rodriguez Esparragoza, MD¹⁰, Maria Hernández-Pérez, MD, PhD¹⁰, Alejandro Bustamante, MD, PhD¹⁰, Ossama Yassin Mansour, MD, PhD¹¹, Mohammed Megahed, MD¹², Tamer Hassan, MD¹³, David S Liebeskind, MD¹⁴, Ameer Hassan, MD¹⁵, Saif Bushnaq, MD¹⁶, Mohamed Osman, MD¹⁶, Alejandro Rodriguez Vazquez, MD⁶

¹Department of Neurology; Hospital Clínico Universitario de Valladolid, Valladolid, Spain; ²Cooper Neurologic Institute, Cooper University Hospital, Camden, New Jersey, United States of America; ³Stroke Unit, Department of Neurology, Vall d'Hebron Research Institute, Barcelona, Spain; ⁴Department of Neurology, Hospital Clínico Universitario de Valladolid, Valladolid, Spain; ⁵Department of Neurology, Hospital Universitari, Bellvitge, Barcelona, Spain; ⁶Department of Neurology, Hospital Clinic, Barcelona, Spain; ⁷Boston Medical Center, Boston University School of Medicine, Boston, Massachusetts, United States of America; ⁸Department of Neurology, Emory University School of Medicine, Atlanta, Georgia, United States of America; ⁹Department of Neurology, Grady Memorial Hospital, Atlanta, Georgia, United States of America; ¹⁰Stroke Unit, Hospital Universitari Germans Trias i Pujol, Barcelona, Spain; ¹¹Neurology Department, Stroke and neurointervention unit, Alexandria, Egypt; ¹²Critical care Department, Alexandria University, Alexandria, Egypt; ¹³Neurosurgery Department, Stroke and Neurointervention unit, Alexandria, Egypt; ¹⁴Department of Neurology, Ronald Reagan UCLA Medical Center, Los Angeles, California, United States of America; ¹⁵Department of Clinical Neuroscience Research, Valley Baptist Medical Center, Harlingen, Texas, United States of America; ¹⁶Neuroscience Institute, Bon Secours Mercy Health St. Vincent Hospital, Toledo, Ohio, United States of America

Introduction:

Coronavirus disease 2019 (COVID-19) is associated with a small but clinically significant risk of stroke, the cause of which is frequently cryptogenic. In a large multinational cohort of consecutive COVID-19 patients with stroke, we evaluated clinical predictors of cryptogenic stroke, short-term functional outcomes and in-hospital mortality among patients according to stroke etiology.

Methods:

We explored clinical characteristics and short-term outcomes of consecutively evaluated patients 18 years of age or older with acute ischemic stroke (AIS) and laboratory-confirmed COVID-19 from 31 hospitals in 4 countries (3/1/20-6/16/20).

Results:

Of the 14,483 laboratory-confirmed patients with COVID-19, 156 (1.1%) were diagnosed with AIS. Sixty-one (39.4%) were female, 84 (67.2%) white, and 88 (61.5%) were between 60-79 years of age. The most frequently reported etiology of AIS was cryptogenic (55/129, 42.6%), which was associated with significantly higher white blood cell count, c-reactive protein, and D-dimer levels than non-cryptogenic

AIS patients ($p \leq 0.05$ for all comparisons). In a multivariable backward stepwise regression model estimating the odds of in-hospital mortality, cryptogenic stroke mechanism was associated with a fivefold greater odds in-hospital mortality than strokes due to any other mechanism (adjusted OR 5.16, 95%CI 1.41-18.87, $p=0.01$). In that model, older age (aOR 2.05 per decade, 95%CI 1.35-3.11, $p<0.01$) and higher baseline NIHSS (aOR 1.12, 95%CI 1.02-1.21, $p=0.01$) were also independently predictive of mortality.

Conclusions:

Our findings suggest that cryptogenic stroke among COVID-19 patients may be related to more severe disease and carries a significant risk of early mortality.

Keywords: Stroke

Financial Disclosures: The authors had no disclosures.

Grant Support: None.

Platform 13

Pre-clinical Large Vessel Occlusion Stroke Model: Capybaras (Hydrochoerus Hydrochoeris)

Diogo C Haussen, MD¹, Srikant Ranagraju, MD¹, Alhamza R Al-Bayati, MD¹, Christian Rolfes, Ph.D², Mahmoud H Mohammadem, MD¹, Michael Frankel, MD¹, Raul G Nogueira, MD¹

¹Emory University/Grady Memorial Hospital, Atlanta, Georgia, United States of America; ²GCMi (Global Center for Medical Innovation), Atlanta, United States of America

Introduction:

Existing pre-clinical large vessel occlusion stroke (LVOS) models have limitations. We evaluated the capybara (Hydrochoerus Hydrochoeris), a rodent with larger cerebral cortex, higher gyral complexity, and larger caliber vessels as a potential model.

Methods:

A conventional catheter angiogram was performed in an 18-month-old/38Kg capybara. We investigated 1) the angiographic architecture, 2) the feasibility of microcatheter navigation/stent-retriever deployment/retraction in the intracranial vessels, 3) the leptomeningeal collateral pattern following transient large vessel occlusion (LVO) with coil occlusion, 4) the infarct topography and 5) histological analysis on the parenchyma and approached arteries. Paraffin embedded sections of the brain parenchyma were stained with hematoxylin and eosin (HE) and luxol fast blue (LFB); proximal/mid/distal basilar and right middle cerebral artery (MCA) cross-sections were stained with HE.

Results:

The animal was placed supine on the angiography table under general anesthesia and the femoral artery was punctured. Full heparinization was pursued (ACT 250-300s). A 6French catheter was used to perform an angiogram of the craniocervical arteries (**Figure**). Both cervical internal carotid arteries (ICA) were atrophied as previously described; the cerebral angioarchitecture was otherwise similar to humans; no left anterior cerebral artery A1 observed. The catheter was exchanged for a Catalyst-5 intermediate catheter in the left vertebral artery (VA). Under roadmap guidance, a 0.017" microcatheter was advanced into the basilar, posterior communicating artery, ICA, and finally into the right MCA-M2 segment. A 3mm Trevo-Retriever was deployed across the MCA and retracted; the process was repeated 4 times. Another 0.017" microcatheter used to position a 2mmX6cm ultra-soft coil to transiently occlude the left MCA (and maintained for 45min per protocol based on collateral status). A 4mm Trevo-Retriever was deployed across the basilar for a total of 5 times. Final angiography revealed patent arteries with no stagnation/oligemia/cutoffs. The animal was extubated with a normal exam but progressively deteriorated with no clear focal neurological signs, developing hyperventilation/tachycardia and then euthanized at 2.5hours. Parenchymal histology revealed neurons with pyknotic features (indicating ischemic injury) in the left frontal cortex while all other regions were normal; LFB staining demonstrated loss of the grey-white delineation in the left frontal cortical. The integrity of the internal elastic lamina and media was preserved in cross-sectional analysis of the proximal/mid/distal basilar and right MCA; denudation of the endothelium was noted; subarachnoid blood was noted in the right Sylvian fissure.

Conclusions:

We evaluated a novel pre-clinical model for stroke thrombectomy. Capybaras are a promising neuroendovascular animal model. Further validation is warranted.

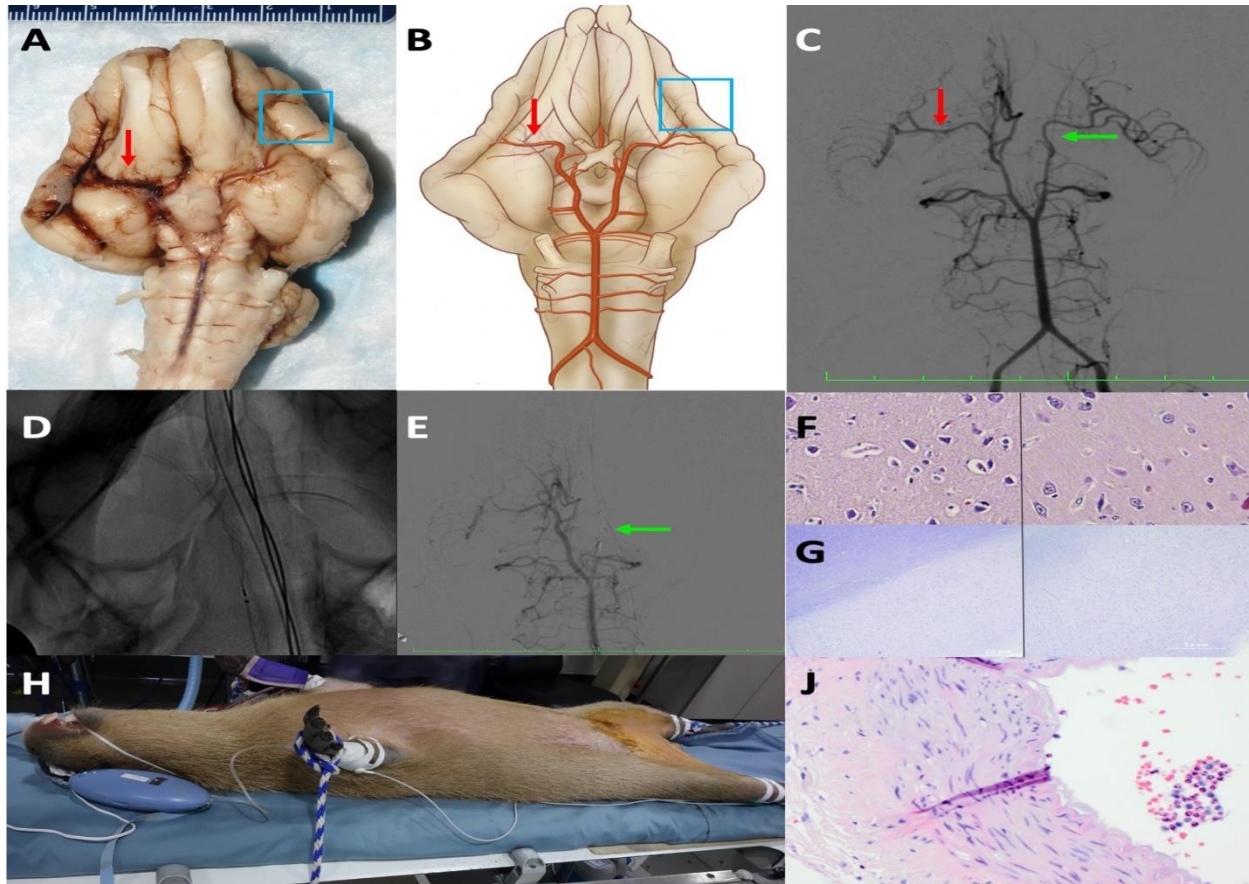


Figure Legend: A) gross-view and B) diagram of the base of the encephalon (red arrow indicates the right middle cerebral artery (MCA); inset demonstrates the pathological specimen of F-G); frontal angiogram (red arrow indicates the right and green arrow the left MCA); D) 3mm retriever deployed in the right MCA; E) coil occlusion of the left MCA; F) HE staining revealing pyknotic features (left) and normal pyramidal cells (right); G) LFB revealing preserved grey-white matter (left) and pallor/myelin loss (right); animal under anesthesia; J) mid basilar artery HE showing intact internal elastic lamina and denudation of endothelium.

Keywords: Angiogram, Angiographic Technology

Financial Disclosures: Consultant for Stryker, Cerenovus, Vesalio; Viz-AI; stock options

Grant Support: Sources of Funding: Emory Medical Care Foundation; Society of Vascular and Interventional Neurology.

Platform 14

Detection and Quantification of Symptomatic Atherosclerotic Plaques with High-Resolution Imaging in Cryptogenic Stroke

Rami Fakh, MD¹, Jorge A Roa, MD¹, Girish Bathla, MD¹, Heena Olalde, RN¹, Alberto Varon, MD¹, Santiago Ortega Gutierrez, MD¹, Colin Derdeyn, MD¹, Harold Adams, MD¹, David Hasan, MD¹, Enrique Leira, MD¹, Edgar Samaniego, MD¹

¹University of Iowa Healthcare, Iowa City, Iowa, United States of America

Introduction:

High-resolution vessel wall imaging (HR-VWI) is as a powerful tool in diagnosing intracranial vasculopathies not detected on routine imaging. We hypothesized that 7T HR-VWI may detect the presence of atherosclerotic plaques in patients with intracranial atherosclerosis disease (ICAD) initially misdiagnosed as cryptogenic strokes.

Methods:

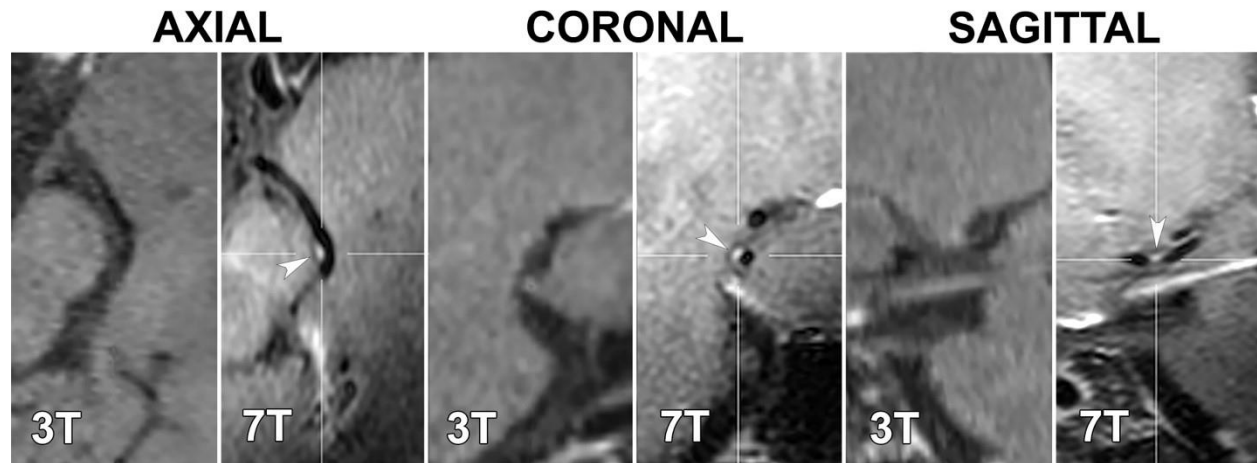
Patients diagnosed as cryptogenic stroke but suspected of having an intracranial arteriopathy by routine imaging were prospectively imaged with HR-VWI. If intracranial atherosclerotic plaques were identified, they were classified as culprit or non-culprit based on the likelihood of causing the stroke. Plaque characteristics such as contrast enhancement, degree of stenosis, and morphology, were analyzed. Contrast enhancement was determined objectively after normalization with the pituitary stalk. A cut-off value for plaque-to-pituitary stalk contrast enhancement ratio (CR) was determined for optimal prediction of the presence of a culprit plaque. A revised stroke etiology was adjudicated based on clinical and HR-VWI findings.

Results:

A total of 344 cryptogenic strokes were analyzed and 38 eligible patients were imaged with 7T HR-VWI. ICAD was adjudicated as the final stroke etiology in 25 patients. A total of 153 intracranial plaques in 374 arterial segments were identified. Culprit plaques (n=36) had higher CR, and had concentric morphology when compared to non-culprit plaques ($p \leq 0.001$). CR ≥ 53 had 78% sensitivity for detecting culprit plaques, and a 90% negative predictive value. CR ≥ 53 ($p=0.008$), stenosis $\geq 50\%$ ($p<0.001$) and concentric morphology ($p=0.030$) were independent predictors of culprit plaques.

Conclusions:

7T HR-VWI allows identification of underlying ICAD in a subset of stroke patients with suspected underlying vasculopathy but otherwise classified as cryptogenic. Plaque analysis in this population demonstrated that culprit plaques had more contrast enhancement (CR ≥ 53), caused higher degree of stenosis, and had a concentric morphology.



Keywords: Ischemic Stroke, Atherosclerosis, Intra Caranial Stenosis, Imaging

Financial Disclosures: The authors had no disclosures.

Grant Support: This work was supported by the 2019 Brain Aneurysm Research Grant from The Bee Foundation and by a Pilot Research Grant from the Society of Vascular and Interventional Neurology (SVIN),

Platform 15

Angiosuite Cone-Beam Computed Tomography Perfusion Imaging in Large Vessel Occlusion Thrombectomy Patients Using RAPID Software

Darko Quispe-Orozco, Dr.¹, Darko Quispe-Orozco, Dr.¹, Cynthia Zevallos, Dr.¹, Mudassir Farooqui, Dr.¹, Alan Mendez-Ruiz, Dr.¹, Sameer Ansari, Mr.¹, Sebastian Schafer, Dr.², Sudeepta Dandapat, Dr.³, Kaustubh Limaye, Dr.¹, Edgar Samaniego, Dr.¹, Colin Derdeyn, Dr.¹, Nils Petersen, Dr.⁴, Santiago Ortega-Gutierrez, Dr.¹

¹University of Iowa Hospitals and Clinics, Iowa city, Iowa, United States of America; ²Siemens Healthineers Forchheim Germany, Hoffman Estates, Illinois, United States of America; ³Aurora Neuroscience Innovation Institute, Milwaukee, Wisconsin, United States of America; ⁴Yale New Haven Hospital, New Haven, Connecticut, United States of America

Introduction:

Clinical trials have demonstrated the value of Multidetector CT perfusion (MDCTP) for selecting late-window patients undergoing mechanical thrombectomy (MT). Direct transfer to angiosuite with Cone Beam CT perfusion (CBCTP) capabilities could significantly reduce revascularization times for optimal clinical outcomes. We sought to evaluate the agreement between RAPID software post-processing acquisition images obtained by a CBCTP prototype and MDCTP in patients undergoing MT.

Methods:

We performed a prospective, single-arm interventional study. Consecutive patients with anterior circulation large vessel occlusion (LVO) underwent MDCTP and CBCTP within 60 minutes apart before MT. CBCTP images were acquired on an Artis Zee biplane system. A prototype acquisition mode enabling ten consecutive C-Arm rotations with data acquisition in forward and backward rotations was used. 60 ml Contrast injection and multisweep acquisition were triggered at the same time for a minute duration. CBCTP projection datasets were post-processed independently using a RAPID prototype by an investigator blinded to all clinical information. Core infarct was defined as CBF<45% in CBCTP images. Intraclass correlation coefficient (ICC), Pearson (r), and Spearman (ρ) correlation tests were used for comparisons. We evaluated the agreement using the Bland-Altman analysis. A final sensitivity analysis was used to evaluate the agreement and correlation between CBCTP images and the final infarct volume (FIV) on post-MT DWI-MRI sequences in patients with mTICI 2b-3.

Results:

We included 13 patients in the study. The median age was 80 (IQR 74-87), 46% were male, and median NIHSS was 19 (IQR 14-22). The median time from the LWK to groin puncture was 302 minutes (IQR 272 – 918); and from MDCTP to CBCTP, 47 minutes (IQR 32 – 62). Six patients (46%) received IV t-PA, and 12 (92%) underwent MT (one patient had spontaneous recanalization). Successful reperfusion was achieved in 10/12. There were no significant differences in median volumes of CBF medians (12ml IQR 7-50 vs 21.6ml IQR 0-91), T_{max}>6s (184ml IQR 121-212 vs. 151ml IQR 76-192), and T_{max}>10s (88ml IQR 40-133 vs. 71ml IQR 37-98) between MDCTP and CBCTP, respectively. We found a good (ICC: 0.89), moderate (ICC: 0.74), and excellent (ICC: 0.92) level of agreement for CBF, T_{max}>6s, and T_{max}>10s, respectively. Correlation coefficients and Bland-Altman plots are summarized on Figure 1. Our sensitivity analysis showed a good correlation ($r=0.87$, $\rho=0.87$) and ICC of 0.81 between FIV and CBCTP images.

Conclusions:

Our results demonstrate a promising accuracy of CBCTP in evaluating infarct ischemic tissue in patients with LVO eligible for MT.

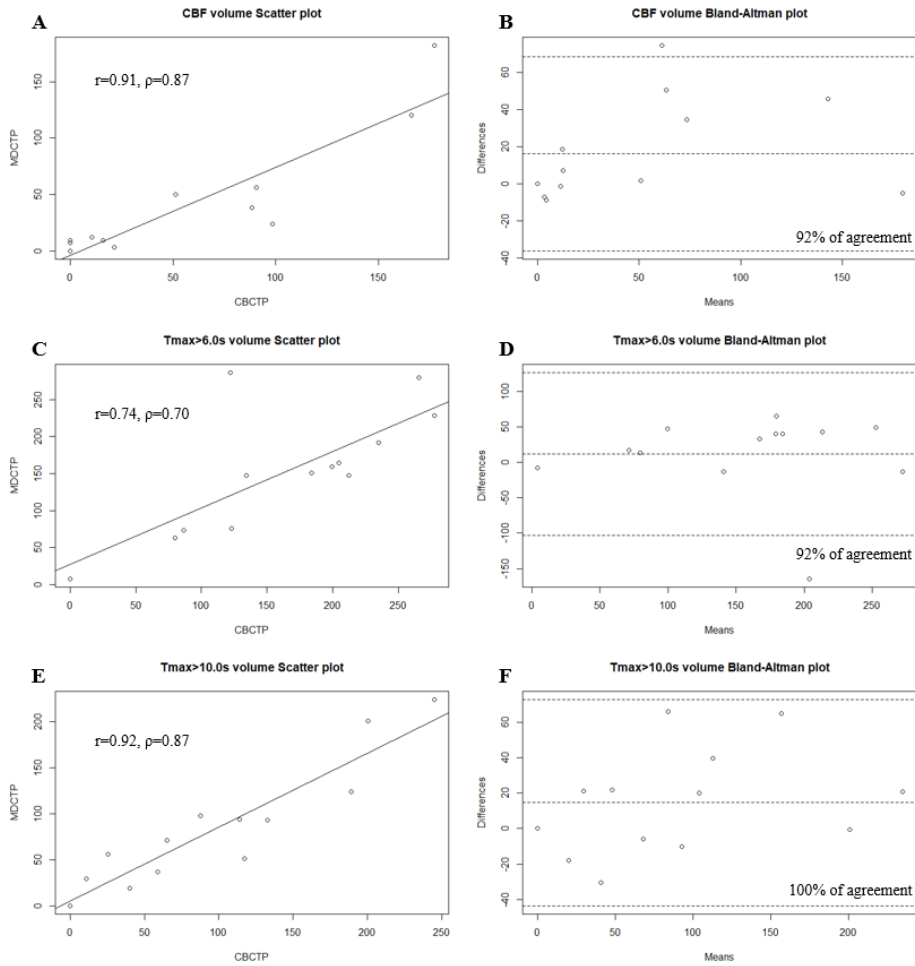


Figure 1. Scatterplot with regression line of CBF (A), Tmax>6.0s (C), and Tmax>10.0s (E) measured with MDCTP and CBCTP. Bland-Altman plots comparing CBF (B), Tmax>6.0s (D), and Tmax>10.0s (F) between MDCTP and CBCTP.

Keywords: Acute Stroke, Mechanical Thrombectomy, Ct Perfusion, Ischemic Stroke,

Financial Disclosures: The authors had no disclosures.

Grant Support: None.

Platform 16

Distal MCA M2 Thrombectomy in the STRATIS Registry

Mouhammad A Jumaa, MD, FSVIN¹, Alicia C Castonguay, PhD, FSVIN¹, Hisham Salahuddin, MD¹, Kaustubh Limaye, MD², Mudassir Farooqui, MD², Syed F Zaidi, MD¹, Nils Mueller-Kronast, MD³, David Liebeskind, MD, FSVIN⁴, Osama O Zaidat, MD, MS, FSVIN⁵, Santiago Ortega Gutierrez, MD, FSVIN²

¹University of Toledo, Toledo, Ohio, United States of America; ²University of Iowa, Iowa City, Iowa, United States of America; ³Delray Medical Center, Tenet, United States of America; ⁴UCLA, Los Angeles, California, United States of America; ⁵Mercy St. Vincent, Toledo, United States of America

Introduction:

The safety and efficacy of mechanical thrombectomy for acute ischemic stroke patients (AIS) with M2 segment middle cerebral artery occlusions remains unclear. Here, we compare clinical and angiographic outcomes in ICA or M1 versus M2 occlusions using the Systematic Evaluation of Patients Treated With Neurothrombectomy Devices for Acute Ischemic Stroke (STRATIS) Registry.

Methods:

The STRATIS Registry was a prospective, multicenter, non-randomized, observational study of AIS LVO patients treated with the Solitaire stent-retriever as the first-choice therapy within 8 hours from symptoms onset. Primary outcome was defined as functional disability at 3 months measured by the dichotomized mRS (0-2 vs 3-6). Secondary outcomes included reperfusion rates measured by the mTICI, and rates of symptomatic ICH (sICH) at 24 hours. Multivariate logistic regression was performed to identify predictors of revascularization for M2 occlusions.

Results:

A total of 930 patients were included, of which 760 (81.7%) had ICA or M1 and 170 (18.3%) had M2 occlusions. Baseline demographics were well balanced within the groups, with the exception of mean baseline NIHSS score (17.7 ± 5.5 versus 15.7 ± 5.0 , $p < 0.001$) which was higher in the ICA/M1 population. Mean ASPECTS score was higher in the M2 group (8.7 ± 1.4 versus 8.1 ± 1.6 , $p < 0.001$). Mean arrival to groin puncture times were longer in the M2 group (89.5 ± 46.8 versus 77.2 ± 48.6 , $p = 0.005$); however, no difference was seen in mean puncture to revascularization times between the cohorts (45.1 ± 29.5 versus 46.0 ± 27.8 , $p = 0.75$). Mean number of passes was higher in the ICA/M1 group (1.9 ± 1.3 versus 1.6 ± 0.9 , $p < 0.001$). Rates of successful reperfusion (mTICI $\geq 2b$) were similar between the groups (93% versus 91%, $p = 0.34$). M2 patients had increased rates of sICH at 24hrs (1% versus 4%, $p = 0.003$). Rates of good functional outcome (mRS 0-2) (55% versus 58%, $p = 0.53$) and mortality (16% versus 15%, $p = 0.77$) at 90 days did not differ between the groups. In a multivariate logistic regression model that included univariately significant predictors baseline NIHSS, ASPECTS, puncture to revascularization time, procedure time, balloon guide use, and number of passes and utilized stepwise selection, only puncture to revascularization time was significant in the final model as a predictor of revascularization in M2 occlusions (odds ratio 0.97, 95% CI 0.95-0.99, $p = 0.002$).

Conclusions:

In the STRATIS Registry, M2 occlusions achieved similar rates of successful reperfusion and good functional outcome, although increased rates of sICH were demonstrated when compared to ICA/M1 occlusions. Randomized control studies are needed to understand the benefit of MT for M2 occlusions.

Keywords: Acute Ischemic Stroke Intervention

Financial Disclosures: The authors had no disclosures.

Grant Support: None.

Platform 17

Benefit Of Mechanical Thrombectomy In The Excellent Registry – Interim Analysis

Amin Nima Aghaebrarhim, SVIN¹, Ricardo Hanel, SVIN¹, Raul Nogueira, SVIN², Tommy Andersson, SVIN³, Simon F De Meyer, SVIN⁴, Jens Fiehler, SVIN⁵, Hacke Werner, SVIN⁶, Tudor Jovin, SVIN⁷, David S Liebeskind, SVIN⁸, Yoo J Albert, SVIN⁹, Osama Zaidat, SVIN¹⁰, Diogo Haussen, SVIN¹¹, Violiza Inoa, SVIN¹², William Humphries, SVIN¹³, Keith B Woodward, SVIN¹⁴, Pascal M Jabbour, SVIN¹⁵, Olivier Francois, SVIN¹⁶, Shervin R Dashti, SVIN¹⁷, hormozd Bozorgchami, SVIN¹⁸, Elad I Levy, SVIN¹⁹, Ronald F Budzik, SVIN²⁰, Stephan Boor, SVIN²¹, Muhammad A Taqi, SVIN²², Clemens M Schirmer, SVIN²³, Reade A De Leacy, SVIN²⁴, Shazam Hussain, SVIN²⁵, ajit s puri, SVIN²⁶, Laurent Estrade, SVIN²⁷, Adnan H Siddiqui, SVIN²⁸

¹Baptist Neurological Institution, Jacksonville, Florida, United States of America; ²Emory University school of medicine, Atlanta, Georgia, United States of America; ³Karolinska University Hospital, Stockholm, Sweden; ⁴Laboratory for Thrombosis Research, KU Leuven, Campus Kulak Kortrijk, Kortrijk, Belgium; ⁵Neurosurgery, University Medical Center, Hamburg, Germany; ⁶Neurology, University of Heidelberg, Heidelberg, Germany; ⁷Cooper University Hospital, Camden, New Jersey, United States of America; ⁸Neurology, University of California Los Angeles,, Los Angeles, California, United States of America; ⁹Interventional Radiology, Texas Stroke Institute, Dallas Fort Worth, Texas, United States of America; ¹⁰Mercy St Vincent Medical Center, Toledo, Ohio, United States of America; ¹¹Department of Neurology, Emory University and Grady Health System, Atlanta, Georgia, United States of America; ¹²Semmes Murphey Clinic, Memphis, Tennessee, United States of America; ¹³Wellstar Health System, Kennestone Hospital,, Marietta, Georgia, United States of America; ¹⁴TNVI Knoxville/ Fort Sanders Regional Medical Center, Knoxville, Tennessee, United States of America; ¹⁵Thomas Jefferson University Hospital, Philadelphia, Pennsylvania, United States of America; ¹⁶AZ Groeninge, Kortrijk, Belgium; ¹⁷Norton Healthcare, Louisville, Kentucky, United States of America; ¹⁸Oregon Health and Science University Hospital, Portland, Oregon, United States of America; ¹⁹Department of Neurological Surgery, University at Buffalo, Buffalo, New York, United States of America; ²⁰Riverside Radiology and Interventional Associates, Inc., Columbus, Ohio, United States of America; ²¹Universitätsmedizin Mainz Mainz, Germany; ²²Los Robles Medical Center, Vascular Neurology of Southern California, Thosand Oaks, California, United States of America; ²³Department of Neurosurgery, Geisinger Medical Center, Wilkes Barre, Pennsylvania, United States of America; ²⁴Mount Sinai, New York, New York, United States of America; ²⁵Cleveland Clinic Foundation, Cleveland, Ohio, United States of America; ²⁶Umass Memorial Medical Center, Boston, Massachusetts, United States of America; ²⁷Department of Interventional Neuroradiology, University Lille, Lille, France; ²⁸Neurosurgery, SUNY Buffalo, Buffalo, New York, United States of America

Introduction:

We report the results of an interim analysis of EXCELLENT, a large, international, multicenter registry of acute ischemic stroke patients treated with EmboTrap as the first line thrombectomy device in everyday clinical practice.

Methods:

The registry has enrolled 761 patients across 29 centers in US/EU over a period of 24 months. 690 subjects were included this analysis, 484 of whom had 90±15 day mRS available, 191 had imaging

adjudicated by a core lab, and 66 met pre-specified inclusion criteria based on typical clinical trial requirements.

Results:

Subjects mean age was 69.0±14.0 years, 52.3% were female, 96.1% had at least 1 relevant medical history (70.7% hypertension, 35.9% previous/active smoker, 35.4% AFIB, 25.1% diabetes), and 80.4% had a pre-stroke of mRS 0-1. Mean baseline NIHSS was 15.8 (83.1%≥8 and <30; 2.8%≥30), 47% patients had wake up or unwitnessed stroke. 52.4% patients were transferred from an outside hospital and 39.0% received IV tPA. 63.3% of subjects underwent thrombectomy within 8 hours of onset or last known well. Final successful reperfusion (mTICI 2b-3) was achieved in 95.5% cases, with 58.6% achieving it in first pass (per core lab: 96.8% and 66%, respectively). 42.5% patients had >8 point NIHSS improvement at 24hr, 43.6% had 90d mRS 0-2 or equal to pre-stroke in full 'all-comers' population (58.3% in the clinical-trial-like population), with 21.4% mortality at 90 days.

Conclusions:

The high reperfusion rates and good clinical outcomes observed in the EXCELLENT registry reflect the benefit of mechanical thrombectomy in an 'all-comers' population in a real-world setting.

Keywords: Mechanical Thrombectomy, Acute Stroke, Acute Ischemic Stroke Intervention

Financial Disclosures: The authors had no disclosures.

Grant Support: None.

Platform 18

Single-Center Experience with Endovascular Treatment of Cerebral Arteriovenous Malformations in Pediatric Patients

Aaron E Rodriguez-Calienes, Mr.¹, Diego Bustamante-Paytan, Mr¹, Kiara Camacho-Caballero, Ms², Angie Mayoria-Vargas, Ms¹, Giancarlo Saal-Zapata, Dr.³

¹Facultad de Medicina Humana de la Universidad de San Martin de Porres, Callao, Peru; ²Facultad de Medicina Humana de la Universidad Científica del Sur, Lima, Peru; ³Servicio de Neurocirugía Hospital Nacional Guillermo Almenara Irigoyen, Lima, Peru

Introduction:

Arteriovenous malformations (AMVs) are the commonest cause of hemorrhagic stroke in children. Endovascular embolization is a feasible treatment modality, but cure rates are heterogenous from one series to another. Moreover, in the pediatric population, factors associated with angiographic cure are extrapolated from adult series. Thus, we aimed to describe our single-center experience with embolization of pediatric AVMs to determine the frequency of periprocedural complications and associated factors of immediate obliteration outcomes.

Methods:

Between 2011 and 2019, participants between 1 and 18 years of age with AVMs treated at a hospital were included. The clinical features, immediate angiographic results and periprocedural complications were retrospectively collected from the clinical records. For all the patients, the obliteration outcome was obtained from the immediate post procedure angiogram of the final embolization session. Differences among incomplete and complete obliteration were carried out using the t-student and chi-square statistical tests. Logistic regression univariate and multivariate analysis were carried out. The data for this study was obtained after approval from the Institutional Review Board.

Results:

Seventy-six embolization sessions were performed in 41 children (25 females, mean age of 12.9). The 75.6% showed hemorrhage at admission and the majority were frontal lesions (29.3%). Regarding size, 29 cases (72.5%) were < 3cm and 11 cases were between 3-6 cm of size. The mean size of the AVM was 2.5 cm (SD 1.2 cm; range from 0.8 cm to 5.5 cm). The mean Spetzler Martin (SM) grade was 2.1 (range 1 – 4). Agents used were Squid in 12 (29.3%), Onyx in 10 (24.4%), NBCA in 8 (19.5%), more than 2 in 7 (17.1%) and PHIL in 2 (4.9%). In 24 cases (58.5%), a complete obliteration was achieved at the end of the procedure. During the procedure, there were no complications in 32 patients (78.1%), one complication in 8 patients (19.5%) and more than 2 complications in 1 patient. Univariate analysis showed that risk factors for incomplete occlusion were a larger AVM size and the presence of multiple feeders. Multivariate logistic regression analysis showed that the only independent predictor for incomplete occlusion was the presence of a large AVM nidus (OR: 4.2; 95% CI 1.39 – 12.66; p = 0.01).

Conclusions:

Our study showed that the presence of a large AVM nidus is a risk factor for incomplete obliteration of pediatric AVMs. Further studies are needed to determine the influence of these angiographic variables in long-term outcomes.

Keywords: Cerebral Arteriovenous Malformations, Endovascular Therapy, Pediatric Intervention

Financial Disclosures: The authors had no disclosures.

Grant Support: None.

Platform 19

The Society of Vascular and Interventional Neurology Registry (SVIN Registry): A Prospective Multicenter Thrombectomy Consortium

Diogo C Haussen, MD¹, Sunil Sheth, MD², Italo Linfante, MD³, Thanh Nguyen, MD⁴, Ameer Hassan, DO⁵, Jim Siegler, MD⁶, Santiago Ortega-Gutierrez, MD, MSc⁷, Steve M Cordina, MD⁸, Guillermo Linares, MD⁹, Brijesh Metha, MD¹⁰, Mohamad Abdalkader, MD⁴, Artem Kaliaev, MD⁴, Wondwossen Tekle, MD⁵, Laurem Thau, BS⁶, Tudor Jovin, MD⁶, Mudassir Farooqui, MD⁷, Mahmoud H Mohammad, MD, MSc¹, Alhamza Al-Bayati, MD¹, David S Liebskind, MD¹¹, Raul G Nogueira, MD¹

¹Emory University/Grady Memorial Hospital, Atlanta, Georgia, United States of America; ²University of Texas – Houston, Houston, Texas, United States of America; ³Baptist Cardiac and Vascular Institute, Miami, Florida, United States of America; ⁴Boston University medical Center, Boston, Massachusetts, United States of America; ⁵Valley Baptist Medical Center, Harlingen, Texas, United States of America; ⁶Cooper University, Camden, New Jersey, United States of America; ⁷University of Iowa, Iowa, Iowa, United States of America; ⁸University of South Alabama, Mobile, Alabama, United States of America; ⁹St Louis University, St Louis, Missouri, United States of America; ¹⁰Memorial Health System, Hollywood, Florida, United States of America; ¹¹UCLA, Los Angeles, California, United States of America

Introduction:

Mechanical thrombectomy (MT) is the standard of care for acute large vessel occlusion strokes (LVOS). The clinical efficacy has been demonstrated in randomized clinical trials that were performed in carefully selected centers using strict inclusion criteria. The Society of Vascular and Interventional Neurology (SVIN) developed a consortium to collect prospective and large-scale MT data from real-world practice.

Methods:

The SVIN Registry is a multicenter collaborative effort that initiated enrollment of consecutive patients with LVOS who underwent MT in November 2018. SVIN Registry platform utilizes a shared data dictionary instrument via REDCap, a browser-based metadata-driven electronic-data capture software. Data are prospectively collected locally at each site and subsequently exported for quality check and processing by the central coordinating center. The effort encompasses collection of over 90 discreet fields of mandatory variables and offers additional fields for optional co-variables

Results:

As of August 31, 2020, the SVIN Registry had 10 active centers in the United States and 1616 patients enrolled. The average monthly enrollment has ranged between 82-92 patients from July-September 2020. A total of 1488 patients were included from 9 comprehensive stroke centers in the present analysis. Baseline characteristics, imaging findings, procedural variables and clinical outcomes are depicted on **Table**. Median age is 69[IQR;58-79] years, 49.3% are females, 53.2% whites and 28.6% blacks. Hypertension was observed in 76.3%, diabetes mellitus in 29.7%, and atrial fibrillation in 28.8%. Cardioembolism was identified as a stroke etiology in 45%, whereas large vessel cervical and intracranial atherosclerosis in 8.8% and 11.8%, respectively. The median LKN-Puncture time was 334[IQR;188-707] minutes, baseline NIHSS score was 16[IQR;10-21], and ASPECTS was 8[IQR;7-8]. Pre-procedural IV-tPA administration was reported in 35.1%. On CTA;17% of patients had intracranial ICA, 53% had MCA-M1, and 5.2% had basilar occlusions. MT procedure was performed under general anesthesia in 30.4%, the

median procedure time was 39[IQR;25-63] minutes, with a median number of passes of 1[IQR;1-3]. Vessel perforation was reported in 0.9%, dissection in 0.6%, and groin hematoma that required intervention in 1.8%. Regarding outcome, 30.9% achieved full reperfusion (eTICI3) after the first pass and 93.3% had successful reperfusion (eTICI2b-3) at the end of the procedure. Symptomatic intracranial hemorrhage was reported in 4.7%. Functional independence (90-day mRS0-2) was achieved in 40.9%. The 90-day mortality rate was 22.2%.

Conclusions:

The SVIN Registry represents a high-quality composite of real-world data on the practice of MT for LVOS and demonstrates that results of pivotal clinical trials can be reproduced in clinical practice.

Table. Patients demographic, clinical, procedural characteristics, and outcome

Variables	All patients n=1488
Demographic and stroke risk factors n (%)	
Age, years median [IQR]	69 [58-79]
Female	732/1485 (49.3)
Ethnicity	
White	792 (53.2)
Black	426 (28.6)
Hispanic	121 (8.1)
Asian	40 (2.7)
Others / Unknown	109 (7.3)
Hypertension	1136 (76.3)
Diabetes Mellitus	442 (29.7)
Coronary Disease	285 (19.2)
Congestive Heart Failure	208 (14)
Atrial Fibrillation	428 (28.8)
Smoking	262 (17.6)
Hyperlipidemia	768 (51.6)
Stroke etiology	n=1229
Cardioembolic	602 (45)
Large vessel disease	108 (8.8)
Intracranial atherosclerosis	145 (11.8)
Dissection	21 (1.7)
Other determined	85 (6.9)
Undetermined	268 (21.8)
Clinical and Procedural characteristics n (%)	
Last Normal to Puncture time, min	334 [188-707]
Intravenous-Alteplase	519/1480 (35.1)
Baseline NIHSS score	16 [10-21]
ASPECTS	8 [7-10]
CT Perfusion rCBF>30%	6 [0-26]
CT Perfusion Tmax>6s	111 [58-170.5]
CT Perfusion Tmax>10s	36 [9-77]
CTA Favorable Collaterals	328/461 (71.1)
Site of Occlusion (CTA)	
Cervical ICA	84 (5.6)

Intracranial ICA	253 (17)
MCA-M1	790 (53)
MCA-M2	323 (21.7)
MCA-M3	24 (1.1)
ACA	24 (1.1)
Basilar	77 (5.2)
PCA	30 (2)
Lesion side	n=1238
Left	621 (50.2)
Right	555 (44.8)
Basilar	62 (5)
Puncture site	n=1252
Femoral	1206 (96.3)
Radial	57 (45.5)
Carotid	14 (1.1)
Brachial	2 (0.2)
General anesthesia	380/1252 (30.4)
Balloon Guide Catheter	615/1488 (41.3)
Procedure duration, min	39 [25-63]
Number of passes.	1 [1-3]
Procedural complications	
Vessel perforation	11/1252 (0.9)
Dissection	7/1252 (0.6)
Groin hematoma requires intervention	22/1252 (1.8)
Outcome n (%)	
First Pass Effect (FPE - eTICI 3)	386/1248 (30.9)
Modified FPE (eTICI2b-3)	590/1248 (47.3)
Successful reperfusion at the end of the procedure (eTICI2b-3)	1164/1248 (93.3)
Symptomatic Intracranial Hemorrhage	58/1226 (4.7)
24 hours NIHSS score	9 [3-17]
NIHSS score at discharge	5 [2-13]
Discharge mRS	n=1411
0	93 (6.6)
1	178 (12.6)
2	152 (10.8)
3	209 (14.8)
4	379 (26.9)
5	246 (17.4)
6	154 (10.9)
90-day mRS	n=1016
0	126 (12.4)
1	164 (16.1)
2	126 (12.4)
3	159 (15.4)
4	109 (10.7)
5	106 (10.4)
6	226 (22.2)
90-day mRS 0-2*	416/1016 (40.9)
90-day mortality*	226 /1016 (22.2)

* 1297 patients had completed a 90-day window and were eligible for determination of 90-day clinical outcome.

Keywords: Acute Stroke, Mechanical Thrombectomy

Financial Disclosures: Consultant for Stryker, Cerenovus, Vesalio; Viz-AI; stock options

Grant Support: None.

Poster

Simultaneous Mechanical Thrombectomy For Bilateral Large Vessel Occlusions: Technical Case Report With First Pass Effect

Samer M Abdul Kareem, MD¹, Saif Bushnaq, MD¹, Nicholas Liaw, MD,PHD¹, Eugene Lin, md¹, Osama Zaidat, MD, MS¹

¹*Mercy St. Vincent Medical Center, Toledo, Ohio, United States of America*

Introduction:

Acute bilateral Large Vessel Occlusion (LVO) is a devastating condition associated with poor outcome, resulting in loss of consciousness, decerbrate posturing or death. Literature review reveals a scarcity of case reports for this rare condition, with unclear interventional treatment from a neuro-endovascular approach.

We present a case for a patient who presented with coma secondary to right Middle Cerebral Artery (MCA) M1 segment and left Internal Carotid Artery (ICA) terminus LVO. We describe a unique technical approach that was used for simultaneous bilateral mechanical thrombectomy (MT) resulted in bilateral Thrombolysis In Cerebral Infarction (TICI) 3 recanalization, with significant neurological improvement.

Methods:

This is a case of bilateral anterior LVO managed with simultaneous bilateral thrombectomy. A literature review was conducted of reports of bilateral LVO and their subsequent treatment.

Results:

A 75 year old male with history of atrial fibrillation on Warfarin, chronic kidney disease, hyperlipidemia, hypertension and diabetes mellitus type 2 presented with acute onset coma 2 hours prior to arrival. Imaging showed acute occlusion of the left supraclinoid ICA and right MCA M1, with evidence of bilateral perfusion mismatch. Patient was taken to the endovascular lab and simultaneous bilateral MT was performed with TICI 3 recanalization [figure1]. Total fluoroscopy time was 21 minutes and the time from puncture to complete recanalization was 40 minutes. The clinical exam improved significantly from National Institutes of Health Stroke Scale (NIHSS) of 35 (coma scale) to 13.

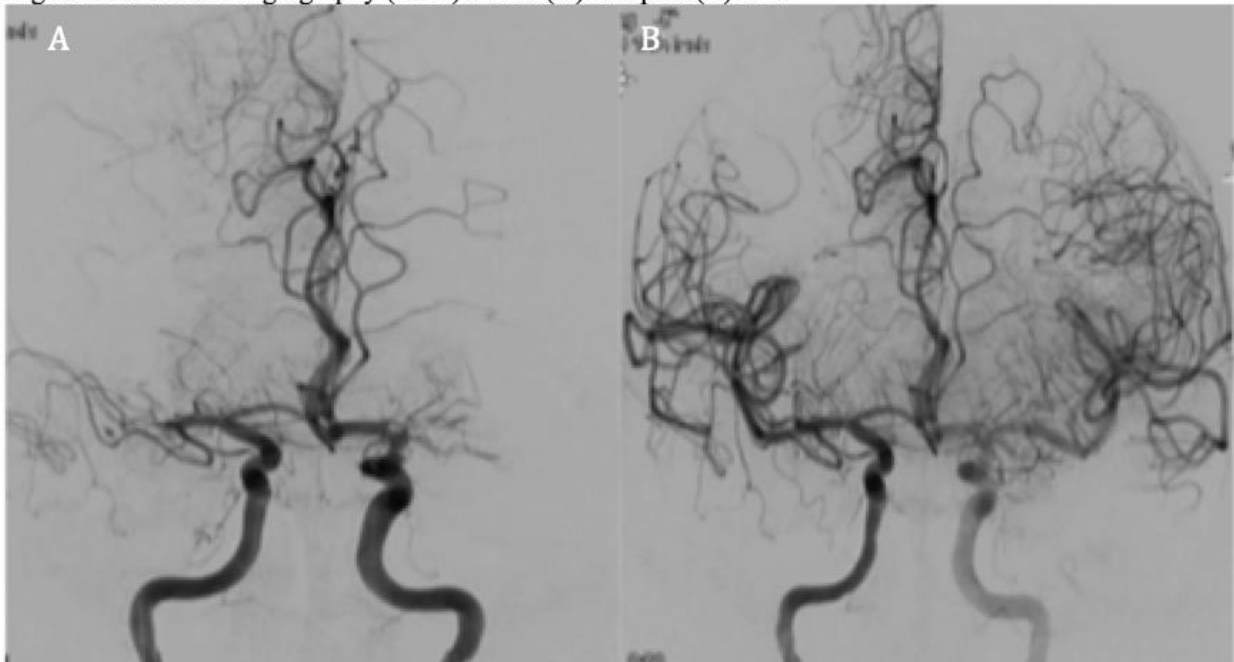
We performed simultaneous intra-arterial thrombectomy for bilateral LVO using the classic technique, which is by using bilateral groin access with bilateral proximal flow arrest using 2 balloon guide catheters (BGC), 2 micro-catheters and two solitaire stent-retrievers. Both clots were crossed simultaneously using J-shaped tip microwire and 021 microcatheter. Subsequently, the solitaire devices were deployed bilaterally for 5 minutes. Then both micro-catheters and solitaire stent-retrievers were withdrawn into the balloon-guide catheter under negative pressure through the BGC port.

Conclusions:

Acute bilateral LVO can be treated with simultaneous MT. This technique reduces the time to first pass, potentially improving neurological outcome and reducing total radiation exposure.

Figure 1

Digital Subtraction Angiography (DSA) of Pre (A) and post (B) MT.



Keywords: Endovascular Therapy, Balloon Guide Catheter, Mechanical Thrombectomy, Solitaire, TICI

Financial Disclosures: The authors had no disclosures.

Grant Support: None.

Poster

A Case of Multi-Drug Resistance to ADP Receptor Inhibitors in Neurointervention

Mohammad El-Ghanem, M.D.¹, Leonardo B. C. Brasiliense, M.D.², Richard Cosgrove, Pharm.D.³, Hamza Abbad, M.D.⁴, Travis M. Dumont, M.D.⁵

¹*Department of Neurology, University of Arizona, Tucson, Arizona, United States of America;* ²*Division of Neurosurgery, University of Arizona, Tucson, Arizona, United States of America;* ³*Department of Pharmacy, Banner University Medical Center, Tucson, Arizona, United States of America;* ⁴*School of Medicine, Jordan University of Science and Technology, Irbid, Jordan;* ⁵*Department of Surgery, Division of Neurosurgery, The University of Arizona, Tucson, Arizona, United States of America*

Introduction:

Inhibition of platelet activity is essential for the safe use of intravascular devices in Neurointerventions. Administration of Aspirin and an ADP receptor inhibitor is supported by the cardiovascular literature and extensive clinical experience. However, resistance or hyporesponse to ADP receptor inhibitors is a recognized problem in the Neurovascular community. We present the case of a patient who demonstrated multi-drug resistance to ADP receptor inhibitors, requiring treatment with Vorapaxar (thrombin receptor antagonist).

Methods:

A 48-year-old female presented with a ruptured left dorsal ICA wall aneurysm over the communicating segment and spontaneous bilateral cervical ICA dissections with pseudoaneurysms. The patient was started on Aspirin and Ticagrelor (ADP receptor inhibitor) in preparation for flow-diverter treatment. She underwent placement of one device over the aneurysm and another device over the left ICA pseudoaneurysm. Two days after the procedure, the patient developed acute right hemiparesis, left gaze deviation, and aphasia. She was taken emergently to the angio suite where thrombosis of the distal flow-diverter was identified. The parent vessel was reopened using intra-arterial Eptifibatid and the patient recovered. Upon discontinuation of the Glicoprotein IIb/IIIa inhibitor, the patient developed recurrent neurological symptoms on multiple occasions despite trying Prasurgel, Clopidogrel, and Ticagrelor. Throughout this period, thromboelastography (TEG) was utilized to monitor the patient's response to the ADP-receptor inhibitors. The MAADP, a marker of individual contribution of ADP activation to clot strength remained essentially normal with all three drugs. The patient showed improved MAADP response to Integrilin. She was then started on Vorapaxar (thrombin receptor antagonist) and remained asymptomatic. She was discharged with mRS 0.

Results:

The patient showed improved MAADP response to Integrilin. She was then started on Vorapaxar (thrombin receptor antagonist) and remained asymptomatic. She was discharged with mRS 0.

Conclusions:

Multi-drug resistance to ADP-receptor inhibitors is a concerning but rare occurrence in neurointerventions. Knowledge of the mechanism of action of different anti-platelet drugs is important to manage this problem.

Keywords: Aneurysm

Financial Disclosures: The authors had no disclosures.

Grant Support: None.

Poster

Distal transradial access for diagnostic cerebral angiography and neurointervention: Systematic review and meta-analysis

Haydn Hoffman, M.D.¹, Muhammad S Jalal, B.S.¹, Hesham Masoud, M.D.¹, Neil Suryadevara, M.D.¹, Grahame C Gould, M.D.¹

¹State University of New York Upstate Medical University, Syracuse, New York, United States of America

Introduction:

Radial artery access for diagnostic cerebral angiography and neurointervention is traditionally performed in the wrist. Distal transradial access (dTRA) in the anatomic snuffbox is an alternative with several advantages. The safety and efficacy of dTRA has not been reviewed.

Methods:

A systematic review of the literature was performed according to PRISMA guidelines in order to identify all case series describing outcomes associated with dTRA for diagnostic cerebral angiography or neurointervention. Random effects models were used to obtain pooled rates of procedural success and complications. Additional variables included mean fluoroscopy time (FT) and contrast dose.

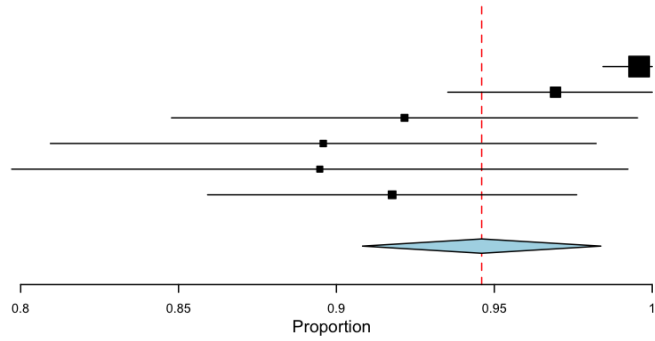
Results:

A total of 7 studies comprising 348 (75.8%) diagnostic cerebral angiograms and 111 (24.2%) interventions met the inclusion criteria. Mean ages ranged between 52 and 64.4 years and there was a majority of females (58.8%). The pooled success rate was 95% (95% CI 91 – 98), but there was significant heterogeneity ($I^2 = 74.33$, $p < 0.01$). The pooled minor complication rate was 2% (95% CI 1 – 4), and there was low heterogeneity ($I^2 = 0$, $p = 0.77$). No major complications were reported. For diagnostic procedures the combined mean (\pm SD) FT was 13.53 minutes (± 8.82) and the mean contrast dose was 74.9 mL (± 35.6).

Conclusions:

Early experience with dTRA suggests that it is a safe and effective alternative to proximal radial access and femoral access for performing diagnostic cerebral angiography and intervention. Additional studies are needed to establish its efficacy and compare it with other access sites.

Studies	Estimate (95% C.I.)
Weinberg et al. 2020	1.00 (0.98, 1.00)
Pons et al. 2020	0.97 (0.94, 1.00)
Saito et al. 2020	0.92 (0.85, 1.00)
Kuhn et al. 2020	0.90 (0.81, 0.98)
Patel et al. 2019	0.89 (0.80, 0.99)
Brunet et al. 2019	0.92 (0.86, 0.98)
Overall (I²=7433 %, P< 0.01)	0.95 (0.91, 0.98)



Keywords: New Technique, Access Catheters, Endovascular

Financial Disclosures: The authors had no disclosures.

Grant Support: None.

Poster

MOYAMOYA DISEASE: AN ATYPICAL CLINICAL CASE IN A PATIENT 73 YEARS OLD PATIENTE

Javier A Lagos-Servellon, Dr¹, Tulio Murillo, Dr², Francisco Amador, Dr³, Roberto Rodriguez, Dr⁴

¹*Residencia Neurologia UNAH, Tegucigalpa, Honduras;* ²*Neurocirugia Hospital Escuela, Tegucigalpa, Honduras;* ³*Neurocirugia UNAH, Tegucigalpa, Honduras;* ⁴*Facultad Ciencias Medicas UNAH, Tegucigalpa, Honduras*

Introduction:

Moyamoya disease is an infrequent cause of stroke, it is a rare cause of ischemia and cerebral hemorrhage. It should be searched in young patients and even rarer is to identify it in the elderly population.

Methods:

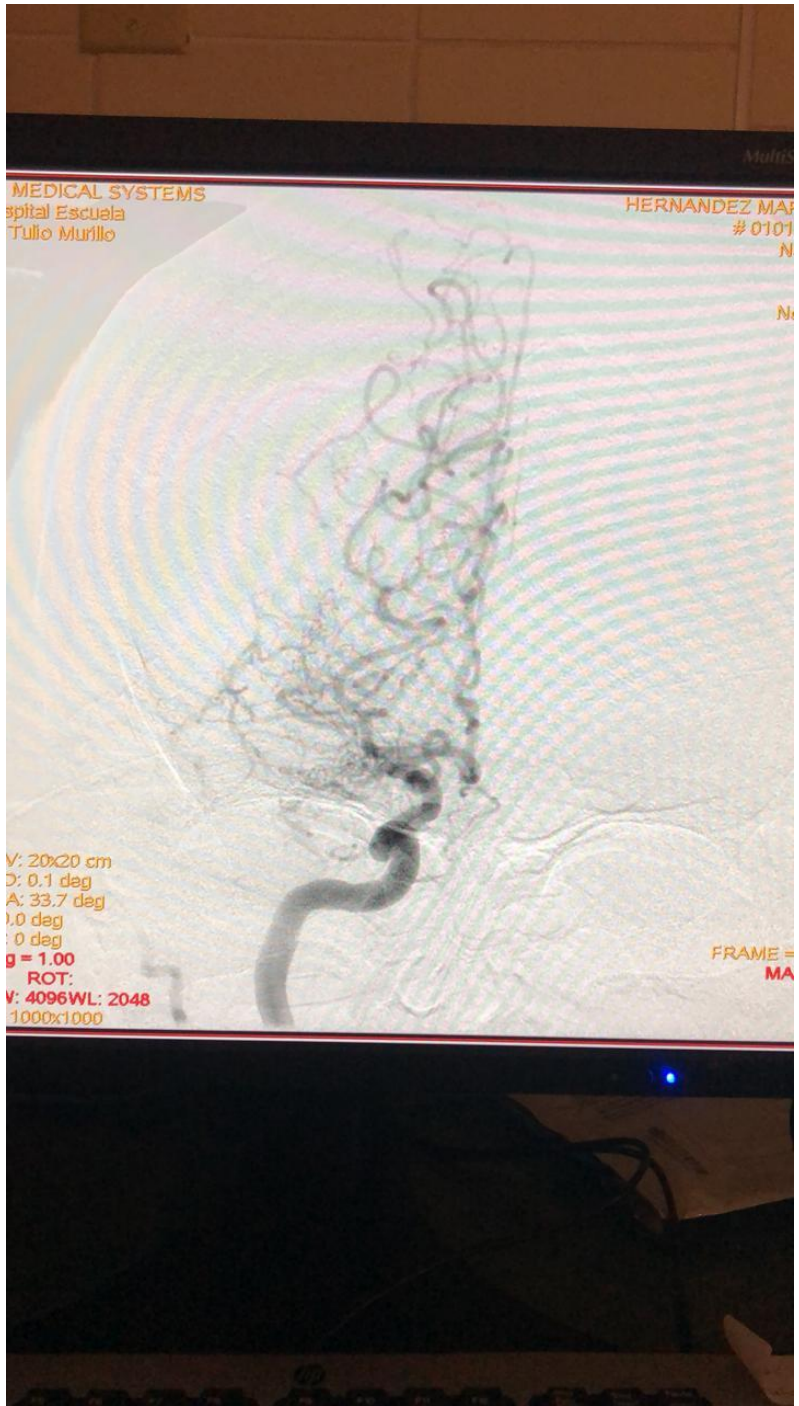We present the case of a patient with multiple cardiovascular risks with sudden headache and impaired consciousness secondary to subarachnoid hemorrhage.

Results:

Imaging studies showed a right posterior communicating artery aneurysm and changes in cerebral circulation consistent with Suzuki grade 6 Moyamoya disease. The patient underwent clipping of the aforementioned aneurysm with good clinical evolution. Little has been described about Moyamoya syndrome in elderly patients and little is known about the management and prognosis of the disease. In Honduras, it is the first published case of Moyamoya syndrome with these characteristics.

Conclusions:

The objective of presenting the case is to highlight the importance of pial circulation as an alternate source of irrigation in the face of slowly progressive occlusion of native vessels (in this example by Moyamoya). This circulation model could eventually be similar to what occurs in atherosclerotic disease, hypertensive vasculopathy, amyloid, among others.



Keywords: Subarachnoid Hemorrhage, Aneurysm

Financial Disclosures: The authors had no disclosures.

Grant Support: None.

Poster

Acute Ischemic Stroke from Thrombosed Aneurysm Mistaken for Intracranial Hemorrhage

Christina Xia, MD¹, Neil Suryadevara, MD, MPH¹, Grahame Gould, MD¹

¹SUNY Upstate Medical University, Syracuse, New York, United States of America

Introduction:

Thrombus in small unruptured aneurysms that cause downstream acute ischemic strokes are rare and guidelines for management are limited.

Methods:

N/A

Results:

We had a 58-year-old woman who was transferred to our institution with dysarthria and aphasia whose outside CT Head reported a left temporal intracranial hemorrhage. Upon arrival, a repeat CT Angiography Head did not demonstrate intracranial or subarachnoid hemorrhage, but instead revealed six aneurysms with a completely thrombosed 5 mm left MCA bifurcation aneurysm and an occluded left inferior M2 branch. MRI brain disclosed an acute infarct in the left insular cortex and left superior temporal gyrus. While the M2 branch was fully occluded, the area of infarct did not represent the full volume of the inferior division. A following CT Perfusion showed a mismatch volume of 20cc that was suggestive of a penumbra in the left temporoparietal region. Given the low NIHSS of 2 and higher risk of hemorrhage from a procedure, our team decided against pursuing recanalization of the thrombosed aneurysm and occluded M2 branch. Antiplatelet agents were not started initially as it was unclear if the focal hyperdensity on imaging included a subtle subarachnoid hemorrhage. However, upon confirming the absence of aneurysmal rupture and hemorrhage, the patient was started on aspirin and atorvastatin for secondary stroke prevention. The patient initially declined catheter angiogram and possible aneurysm clipping during her admission. In a follow up neurosurgery clinic visit, she decided to proceed with a DSA and possible endovascular treatment of her aneurysm. One year later from her initial presentation, the patient underwent stent-assisted Woven EndoBridge (WEB) embolization of left MCA aneurysm. A gradual thrombus was seen extending beyond the WEB device into the patent left inferior division lumen and an intracranial stent was deployed with significant improvement of the lumen patency. The patient had no complications and was neurologically intact. She was discharged on aspirin and ticagrelor. Ticagrelor was chosen as the patient was a poor responder to clopidogrel.

Conclusions:

In literature, there are case reports of thrombosed aneurysms mimicking other conditions such as cavernous angiomas¹, primary brain tumors, and metastases². In this case, the patient had an acute ischemic stroke from a thrombosed aneurysm that was initially thought to be an intracranial hemorrhage on CT imaging. One should confirm imaging findings with a patient's clinical exam. It was highly unlikely for our patient to present with cortical stroke symptoms from a focal subarachnoid hemorrhage in the left sylvian fissure that did not spread to surrounding sulci. In her case, she had an ischemic stroke from a small aneurysm of 5 mm. Ischemic strokes from aneurysms are more commonly associated with large and giant aneurysms³. Small aneurysms, < 10 mm, are a rarer occurrence, with

only a few reported case reports and series in the literature⁴. The role of initiating antiplatelet therapy for secondary stroke prevention in thrombosed small aneurysms is unclear⁵. The patient was managed on aspirin for a year had no intracranial thromboembolic or hemorrhagic events prior to her endovascular embolization of the aneurysm.

Keywords: Aneurysm, Vascular Imaging, Medical Management

Financial Disclosures: The authors had no disclosures.

Grant Support: None.

Poster

Mechanical thrombectomy for cerebral venous sinus thrombosis secondary to heparin-induced thrombocytopenia and thrombosis.

Rahul R Rao, M.D.¹, Aaron Brooking, D.O.², Hamza Shaikh, M.D.², Tudor G Jovin, M.D.², Brian Jankowitz, M.D.²

¹UPMC, Pittsburgh, Pennsylvania, United States of America; ²Cooper University Medical Center, Philadelphia, Pennsylvania, United States of America

Introduction:

Heparin-induced thrombocytopenia and thrombosis (HITT) is a potentially life-threatening immune reaction characterized by declining platelet counts 5-14 days after heparin exposure. It induces venous thrombosis via activation of the coagulation cascade and subsequent platelet aggregation. A 4T score of 6-8 confers a high probability of HITT1. A 44 year old Hispanic male with a past medical history of Bipolar I disorder, diabetes mellitus, chronic low back pain, tobacco use, and hypertension presented with right-sided back pain and hematuria. He was diagnosed with nephrolithiasis and admitted for lithotripsy. Patient was admitted for 7 days and during this time, his complete blood count and coagulation labs remained stable while on heparin pharmacoprophylaxis for deep venous thrombosis. After discharge, he represented 1 day later with a right-sided, 10/10 headache which had been going on for 24 hours. Repeat complete blood count revealed platelet count of 45 and INR of 1.7. A CT head without contrast was obtained and revealed a clot in the right sigmoid and transverse sinuses extending towards the right internal jugular vein (IJV) and involving the posterior 2/3 of the superior sagittal sinus. This was confirmed by CT venogram. 4T score was 7. Due to concern for heparin-induced thrombocytopenia and thrombosis (HITT), the patient was started on an argotroban drip and admitted. After developing new thrombosis after being medically treated, he was brought to the angiography suite for diagnostic cerebral venogram and potential thrombectomy.

Methods:

A 6-French catheter sheath was placed into the right femoral vein. This was upsized to an 8 French Cook shuttle sheath which was advanced into the right IJV. A triaxial system consisting of a 105 cm TracStar catheter, Jet 7, and XT 27 microcatheter was advanced into the SSS. Diagnostic venogram revealed extensive thrombus through the sagittal sinus and right transverse and sigmoid sinuses. Manual aspiration thrombectomy was performed using both the Jet 7 and TracStar catheters resulting in complete recanalization of posterior third of the sagittal, right transverse and sigmoid sinuses.

Results:

The following day, the patient reported resolution of his headache symptoms. Repeat CT venogram 24 hours after the procedure revealed superior sagittal sinus and transverse sinus recanalization.

Conclusions:

This case highlights an example where a patient's symptoms rapidly improved following intervention. In certain, appropriately-selected patients, endovascular treatment for cerebral venous sinus thrombosis may be a useful adjunctive therapy to systemic anticoagulation which is standard of care.

Figure 1. Pretreatment CT venogram demonstrating occlusion of the right transverse sinus, torcula, and superior sagittal sinuses.

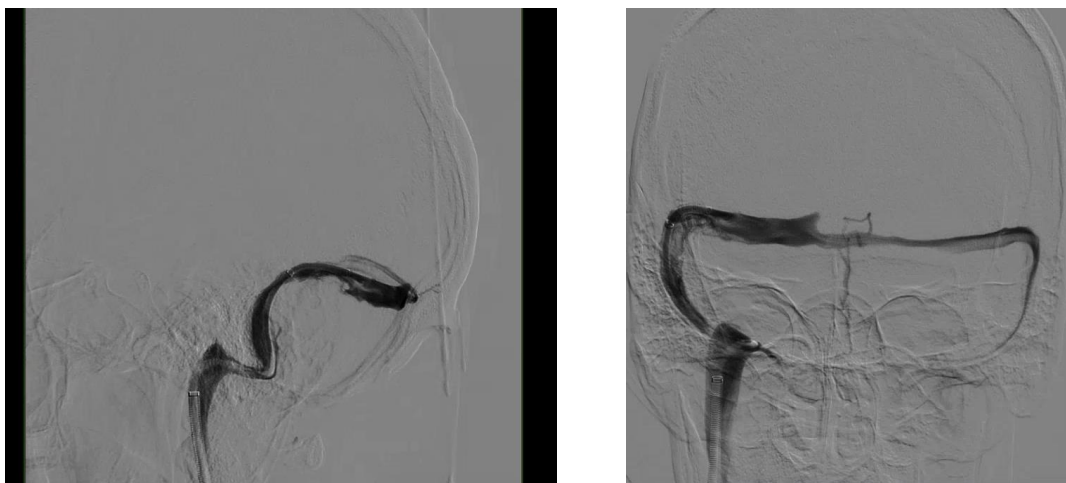
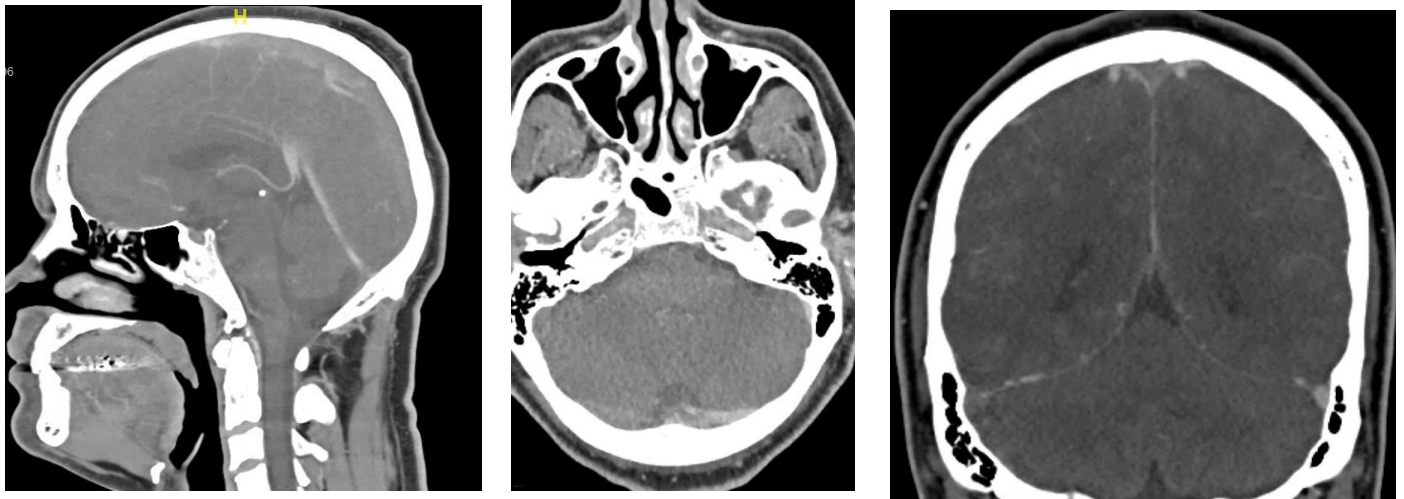


Figure 2. Pre Treatment Sagittal and Coronal Angiogram demonstrating occlusion of torcula and superior sagittal sinus.

Keywords: Cerebral Sinus And Venous Thrombosis, Cerebral Sinus Thrombosis Therapy, Angiographic Technology, Coagulation, Thrombosis

Financial Disclosures: The authors had no disclosures.

Grant Support: None.

Poster

Syringomyelia With Coexistent Spinal Arachnoid Cyst In A 25-year-old Male: A Case Report

Princi D Demaisip, MD¹, Artemio A Roxas, FPNA²

¹The Medical City, Metro Manila, Philippines; ²The Medical City, Pasig City, Philippines

Introduction:

Spinal arachnoid cyst with coexistent syringomyelia is infrequently mentioned in literature. This report describes a previously healthy young adult with upper motor neuron signs and symptoms, imaging findings, surgical technique performed, and the outcome of the patient.

Methods:

A 25-year-old male without comorbidities and recent trauma came in to the ER due to urinary retention. 5 months earlier, he had worsening constipation, erectile dysfunction, and gait changes described as tiptoeing and difficulty in raising his thighs. Symptoms progressed noting numbness of the lower extremities and difficulty in urination prompting frequent visits in the outpatient clinic for catheterization to relieve him from the associated bladder distention and hypogastric pain. There was hypoesthesia on light touch, pain, and temperature modalities at the 10th thoracic dermatomal level. Present Babinski sign bilaterally with impaired vibratory and position sense up to the knee level associated, with muscle atrophy and increased patellar and ankle jerk reflexes. There was decreased motor strength on both lower extremities upon hip flexion and extension, hip abduction and adduction, and knee flexion and extension.

Spine MRI revealed a sacculated fluid filled cavity approximately 9.5 centimeters long with full axial diameter of 1 x 0.9 centimeters within the cord between the 7th to 11th thoracic vertebrae that was consistent of syringohydromyelia. Immediately above this within the dorsal aspect of the spinal canal between the 1st to upper 7th thoracic vertebrae was a poorly defined, T1W hypointense, T2W hyperintense non-enhancing focus, approximately 11 to 12 centimeters long which was consistent of an intradural, extramedullary spinal arachnoid cyst.

Patient underwent decompressive laminectomy with drainage of the cyst at the 2nd to 3rd thoracic levels and laminectomy with subarachnoid shunt insertion at the 8th to 9th thoracic levels. There was a well-defined, thin-walled, transparent and lobulated mass visualized posteriorly to the spinal cord. The mass was composed of a CSF-like content upon wide fenestration. CSF pulsation was evident after drainage. Midline myelotomy followed by syringosubarachnoid shunt insertion was done. Pathological examination of the cyst wall showed intact benign spindle cells with a background of mostly fibrocollagenous tissue. The specimen was consistent with arachnoid cyst.

Results:

After a 3-month follow up, patient reported he was able to go back to office work.

Conclusions:

This is a rare case of a spinal arachnoid cyst causing syringomyelia. Finding more cases can aid in establishing the exact pathomechanism, thereby providing the best management approach for this phenomenon

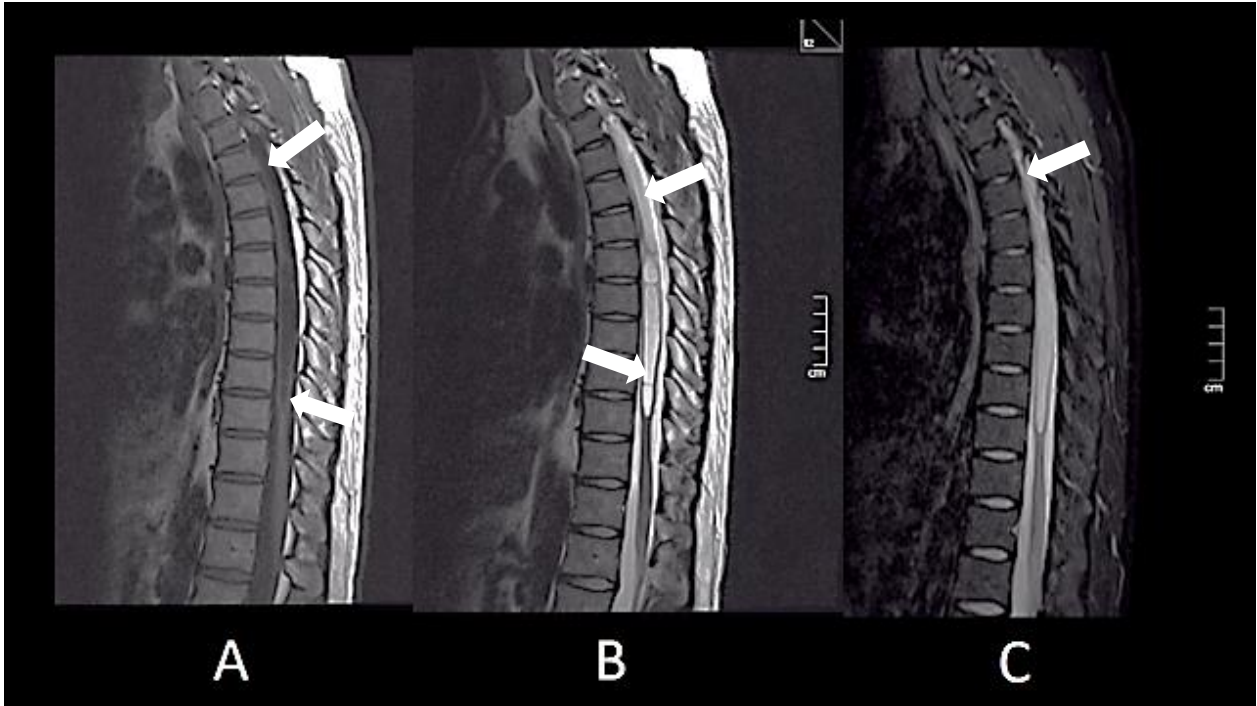


Fig. 1. Thoracolumbar spinal MRI. A. A hypointense intradural extramedullary uniformly cystic mass expanding from T1-T7 compressing the spinal cord posteriorly. Furthermore, there is an intramedullary multicystic component suggestive of syringomyelia located at T7-T11 spinal cord level. B. T2-weighted sequence shows that the cystic mass at the T1-T7 level is isointense compared to the cerebrospinal fluid (CSF) background. The syringomyelia is compartmentalized. C. Short Tau Inversion Recovery (STIR) shows that the upper cystic mass is consistent with arachnoid cyst.

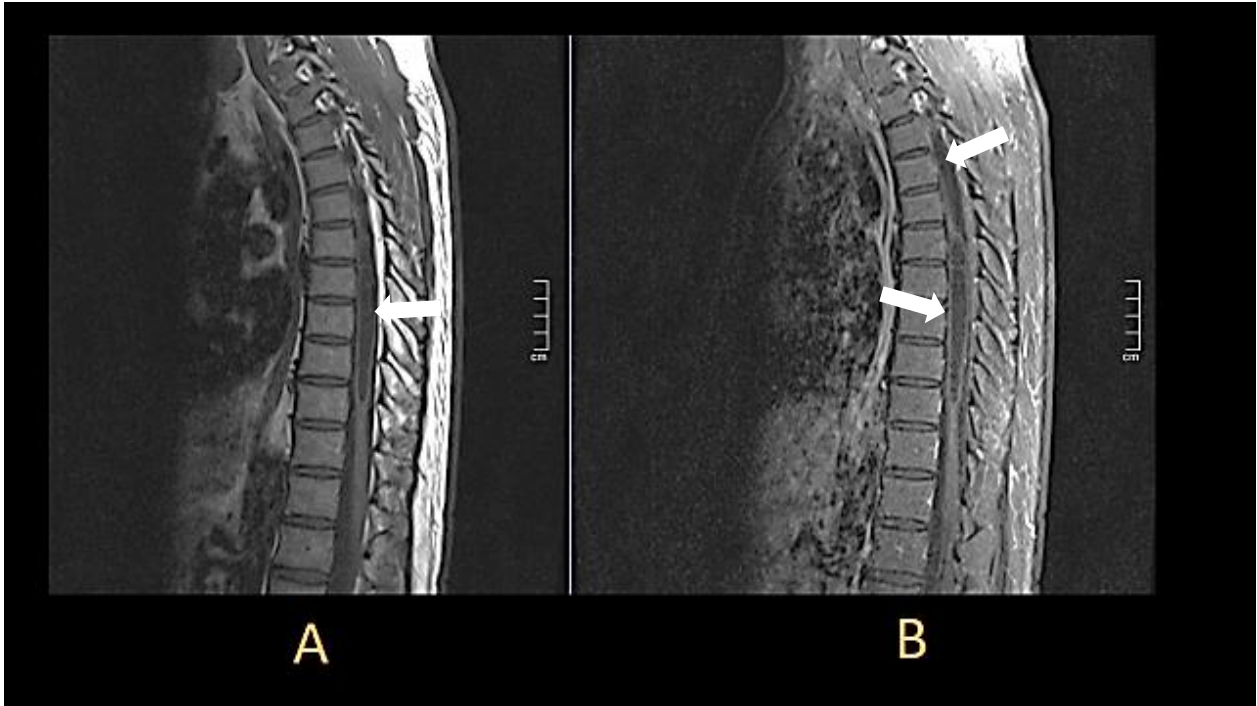


Fig. 2. A. This T1 weighted contrast shows that there is no enhancement in the walls of the dura as well as the walls of the cystic mass depicting that it is not of vascular origin. B. This appears to be extramedullary and intradural in location causing anterior cord displacement and mild cord compression but with no cord edema signals.

Keywords: Diagnostic Neuroradiology, Vertebral, Spinal Malformation Therapy, Epidemiology, MRI

Financial Disclosures: The authors had no disclosures.

Grant Support: None.

Poster

Infarct In New Vascular Territory Secondary To Aspiration Catheter Fracture During Mechanical Thrombectomy

Navreet Kaur, MBBS¹, Karan Philip, MBBS¹, Carlos Lopez, MD³, Amar Swarnkar, MD¹, Hesham Masoud, MBBCH¹

¹SUNY Upstate Medical University, Syracuse, New York, United States of America

Introduction:

Endovascular mechanical thrombectomy is the standard of care for acute ischemic stroke secondary to large vessel occlusions. Though the safety profile of mechanical thrombectomy is well-established, procedural complications may rarely occur. Stent retriever detachment is extremely rare (<1%) and encountered more with first-generation devices. There are only a few cases of aspiration catheter fractures listed in the literature.

Methods:

We present a case of embolic stroke in new vascular territory secondary to aspiration catheter fracture.

Results:

An 84-year-old female presented to our institution 9 hours from last known well with right hemiplegia and global aphasia (NIHSS of 10). CT angiography revealed a left superior M2 MCA occlusion and CT perfusion demonstrated a target mismatch ratio(6.9) favorable for intervention. Initially, a 6F 90 cm long sheath was placed in the left common carotid artery. Subsequently, a Synchro 014 standard microwire(Stryker), a Velocity microcatheter (Penumbra), and an AXS Catalyst 6 aspiration catheter (Stryker) were advanced tri-axially through the sheath. During a difficult advancement through the patient's tortuous aortic arch, the microwire's distal end broke but was successfully retrieved. There was no apparent damage to the velocity microcatheter or suction catheter. A new 6F 90 cm long sheath was used and the ASX Catalyst 6 aspiration catheter, Velocity microcatheter, and Synchro 014 microwire were advanced uneventfully. The M2 occlusion was crossed with the microcatheter and microwire and left M2 thrombectomy was attempted using a 3x20 mm Trevo stent retriever (Stryker). On the second attempt, the M2 occlusion could not be crossed and the tri-axial system was pulled off the sheath. On the third thrombectomy attempt with a Sophia 6F 070 (Microvention), Penumbra 3F microcatheter, and 014 synchro wire, a radio-opaque ring-like material was observed on fluoroscopy in the distal left A1 segment which moved to the left A2 segment spontaneously. A third M2 thrombectomy attempt was unsuccessful. On repeat angiogram, complete occlusion of the left A2 segment was seen. The inspection of the AXS Catalyst 6 aspiration catheter revealed a missing distal metallic marker. We did not attempt to retrieve the detached tip marker due to the high risk of perforation caused by the tight impaction and sharp edges of the marker. Post-procedure NIHSS was 17. She was admitted to the neurocritical care unit, and over her hospital course, required management of cerebral edema and respiratory failure. Eventually, her family opted to transition her to comfort measures only and she passed.

Conclusions:

This case illustrates a rare aspiration catheter-related complication of mechanical thrombectomy. The exact cause of the broken aspiration catheter tip is uncertain and may be related to the tortuous aortic

arch and damaged metallic tip sheared off by the tip of the sheath during withdrawal. We recommend that in addition to routine inspection of the distal part of the aspiration catheter, inspection of the metallic tip itself should also be performed carefully after each withdrawal during mechanical thrombectomy.

Keywords: Mechanical Thrombectomy, Stent retriever, Acute Ischemic Stroke Intervention, Access Catheters, Endovascular Therapy

Financial Disclosures: The authors had no disclosures.

Grant Support: None.

Poster

Convulsive Status Epilepticus: Who Dies and Why?

Keshav Raghavendran, N/A¹, Leah Blowes, N/A¹, Erick Martinez, N/A¹, Jessica Bloomfield, Dr.², Fawaz Al-Mufti, Dr.²

¹New York Medical College, Valhalla, New York, United States of America; ²Westchester Medical Center, Valhalla, New York, United States of America

Introduction:

Convulsive Status Epilepticus (CSE) is a common medical crisis with up to 150,000 cases and 55,000 associated deaths every year in the US alone. Convulsive Status Epilepticus (CSE) is defined as five or more minutes of continuous seizures of two or more discrete seizures with no return to baseline in-between. Studies have shown that treating CSE within the first thirty minutes results in a decreased mortality rate; however, there is little literature that describes who are at the highest risk of mortality and their specific causes of death. Given the life-threatening complications that can result from CSE and the absence of substantial descriptive literature, we feel it essential to identify which patients are at the highest risk for mortality in order to perform the appropriate life-saving treatment earlier.

Methods:

A retrospective cohort study was conducted using de-identified data from the National Inpatient Sample (NIS) database, a component of the Healthcare Cost and Utilization Project (HCUP) sponsored by the Agency for Healthcare Research and Quality and the US Department of Health and Human Services and the largest all-payer inpatient care database in the USA. It contains data on eight million discharges from more than 1000 hospitals each year, which approximates a 20% stratified sample of all US community hospitals. Annual NIS data files from 2007 to 2014 were obtained from the HCUP central distributor. Institutional Review Board and institutional approval were obtained.

Results:

Our study identified that respiratory issues were among the most prevalent in-hospital complications that CSE patients faced likely resulting from mechanical ventilation. While respiratory issues were among the most prevalent complications that CSE patients faced, cardiac issues were the most lethal. Our study also identified various predictors of mortality in CSE patients such as age, race, and sex. Additional predictors included conditions resulting from the buildup of toxic substrates during episodes of CSE such as acute liver necrosis, ERSD, and septicemia.

Conclusions:

Overall, our study was effective at determining the characteristics of patients with CSE who face the greatest risk of in-hospital mortality. Some of those characteristics include elderly age and various comorbidities due to provoked and unprovoked factors. Additionally, our study looked at the causes and potential predictors of mortality in these patients which include various organ dysfunction such as cardiac, pulmonary, hepatic, brain, and renal dysfunction. This information can be used to proactively intervene in high-risk patients and potentially prevent mortality for many of these patients.

Keywords: Neuroprotection

Financial Disclosures: The authors had no disclosures.

Grant Support: None.

Poster

Pipeline embolization device fracture: a case report

Micaela Schachter, MD¹, Raul Nogueira, MD¹, Alhamza Al-Bayati, MD¹, Diogo Haussen, MD¹

¹Emory University, Atlanta, Georgia, United States of America

Introduction:

Stent fractures have been well described with the use of drug-eluting stents in coronaries, carotids and peripheral arteries. However, fractures in Pipeline embolization device (PED) stents have not been reported. We report a PED fracture after the treatment of a vertebral artery dissection.

Methods:

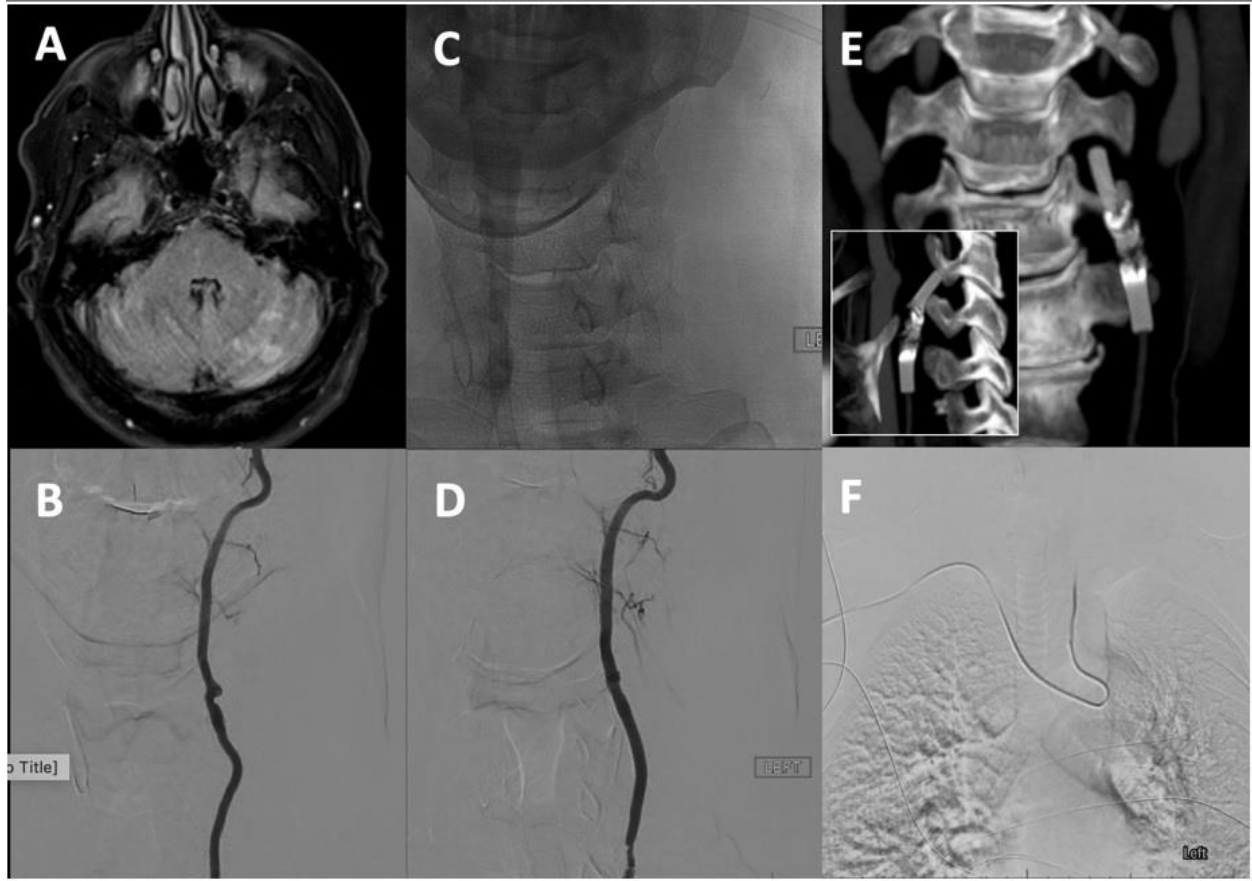
Electronic medical record review.

Results:

A healthy 52-year-old male presented with posterior circulation strokes. Initially, he presented with a posterior circulation infarct leading to numbness and was started on aspirin at an outside facility. Eight months later, he developed facial droop, dysarthria, vertigo and gait instability. MRI was significant for bilateral cerebellar strokes and Clopidogrel was added. CT angiography (CTA) revealed a distal left vertebral artery V1 segment dissection with a small pseudoaneurysm and co-dominant vertebrals. Of note, the vertebral artery was observed to enter the foramen transversarium at the C5 spinal level. There were otherwise no other bone structures adjacent to it on multiplane reconstructions. At 9 months he developed bilateral cerebellar and left thalamic strokes and was found to have a persistent dissection on non-invasive vascular imaging. Clopidogrel was substituted by ticagrelor. At 10 months, a digital subtraction angiogram (DSA) was performed showing an unchanged left vertebral artery dissection with a small pseudoaneurysm (Figure) and he underwent endovascular reconstruction with a PED (4mmx30mm). No recurrent events occurred. A follow-up CTA at 6 months post-stent showed disruption of the stent structure compatible with an extensive fracture; flow through the stent was present. Repeat DSA 8 months post-stent confirmed a fractured stent on fluoroscopy and demonstrated an occluded left vertebral artery stent. The patient remained asymptomatic and was continued on dual antiplatelets.

Conclusions:

We report the fracture of a PED stent. It is possible that the arterial anatomy, stent design, and biomechanical and external stressors could have played a role. It is unclear if additional stent layers or a different stent design could have prevented this adverse event.



Keywords: Flow Diverter, Pipeline

Financial Disclosures: The authors had no disclosures.

Grant Support: None.

Poster

Ruptured dysplastic quadrification blister basilar aneurysm treated in multiple stages with LVIS stents.

Bader Alenzi, Author¹, Saif Bushnaq, co-author¹, Osama Zaidat, Co-author¹

¹*Mercy Health St. Vincent Medical Center, Toledo, Ohio, United States of America*

Introduction:

Ruptured Dysplastic quadrification irregular basilar aneurysm presents on imaging with irregular dilation involving the entire artery with tortuosity, including the origin of the bilateral SCAs and PCAs. This aneurysm is likely to occur due to atherosclerosis and/or dissection.

Methods:

This is a case-report of a patient presenting with a challenging ruptured blister basilar aneurysm

Results:

A 59-years-old female with history of hypertension presenting with altered mental status. Computed Tomography (CT) head revealed Hunt Hess 3 (HH3), Modified Fisher 4 (MF4) diffuse subarachnoid hemorrhage (SAH) and intraventricular hemorrhage with hydrocephalus. Computed Tomography Angiogram (CTA) showed previously treated clipped aneurysm of the left ICA/MCA without residual recurrence and a possible basilar aneurysm. After External Ventricular Drain (EVD) placement, Cerebral angiogram (CA) showed dysplastic quadrification blister aneurysm of the basilar artery with dilatation and multiple irregularities/daughter sacs, involving the origin of the Superior Cerebellar Arteries (SCAs) and the Posterior Cerebral Arteries (PCAs); the most prominent one is 1.5 mm x 2 mm adjacent to the right SCA for which the aneurysm is not amenable to primary coiling. The patient was loaded with aspirin and Plavix and then treated with Y-stenting using an LVIS Jr 3.5mm /23 mm and LVIS blue 4.5 mm/23 mm stent. Clot formation in the right PCA and basilar artery despite aspirin and Plavix use was treated with intra-arterial Tirofiban bolus, resulting in near complete resolution of the clot. Few weeks follow-up CA showed persistence of the blister aneurysm with growing right SCA small aneurysm; which was treated with another stage of stenting using LVIS 4.5mm/23 mm stent spanning the right PCA to the basilar artery. 6 months follow-up CA showed slight resolution of the aneurysm and the development of an in-stent stenosis, which was treated with ATLAS stent. There were no further cerebrovascular events but she had persistent cognitive dysfunction.

Image legend: A. CT head with diffuse SAH/IVH and hydrocephalus

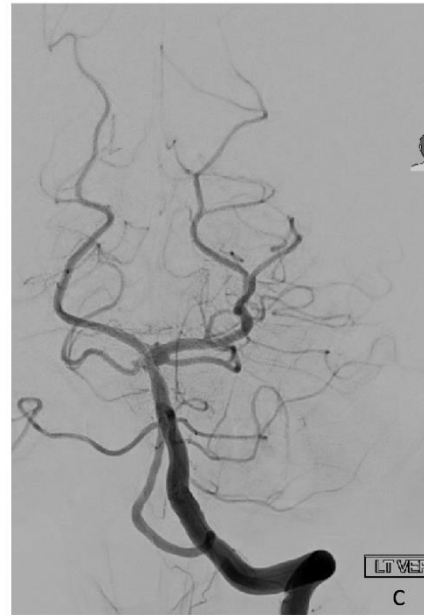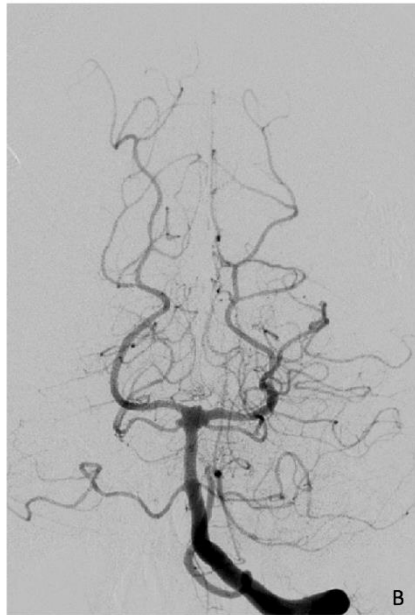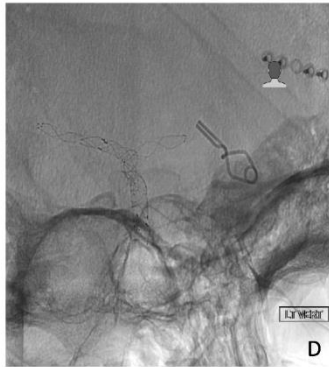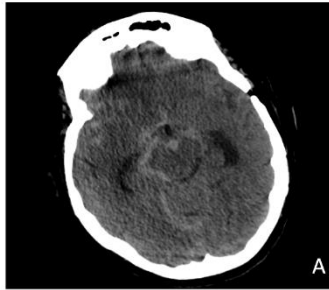
B. CA with dysplastic quadrification blister aneurysm of the basilar artery with dilatation and multiple irregularities/sacs, involving the origin of the SCAs and PCAs.

C. CA 6 months post-treatment follow-up showing slight resolution of the aneurysm

D. CA (Unsubtracted image) 6 months post-treatment follow-up showing the multiple overlapping stents

Conclusions:

This is a challenging ruptured dysplastic quadrification blister basilar aneurysm that was treated in multiple stages using multiple overlapping LVIS stents. According to the literature, LVIS stents are reported to cause less flow diversion effect compared to conventional Pipeline Embolization devices (PEDs).



Keywords: Intracerebral Aneurysm, Aneurysm Embolization, Subarachnoid Hemorrhage, Flow Diverter, SAH

Financial Disclosures: The authors had no disclosures.

Grant Support: None.

Poster

Dual-Stent Retriever Thrombectomy For Extensive Dural Sinus Thrombosis

Michael G Abraham, MD, FAHA¹, Stefano H Byer, MS¹

¹University of Kansas Medical Center, KANSAS CITY, Kansas, United States of America

Introduction:

Cerebral venous thrombosis (CVT) is estimated to occur in 2-15 million/year. Symptoms range from headache to symptoms due to elevated intracranial pressure (ICP). First line treatment is systemic anticoagulation. In cases with symptoms of elevated ICP, endovascular thrombectomy (EVT) is pursued (aspiration and stent-retriever (SR)). We describe two cases in which dual SR were used for EVT.

Methods:

Case 1

A 17-year-old female presented with a 3-day history of headaches, right visual field defect, right facial droop, and right upper/lower extremity weakness. Magnetic resonance venography (MRV) demonstrated occlusion of the superior sagittal sinus (SSS), dominant right transverse sinus (TS), right sigmoid sinus (SS), and upper right internal jugular vein (IJV). Anticoagulation was started. Due to progression to stupor, EVT was performed.

Case 2

A 20-year-old female presented with a 9-day history of bilateral retroorbital pain with swollen-sensation in left neck, blurry vision, and grade 2 OS papilledema. A lumbar puncture demonstrated an opening pressure of 53 cmH₂O. MRV noted CVT in the dominant lateral left TS, SS, and upper left IJV. Anticoagulation was started. Due to objective and subjective findings of elevated ICP, EVT was performed.

Results:

In both cases, a 6 French 90 cm Neuron Max sheath (Penumbra Inc, Alameda, CA) was advanced into the symptomatic IJV.

In case 1 a Jet 7 Flex aspiration catheter (Penumbra Inc) was advanced into the SSS and aspiration thrombectomy was performed to the TS with recanalization of the SSS. Her right TS measured 13 mm in diameter. A Solitaire 6 mm x 40 mm SR (Medtronic, Minneapolis, MN) was deployed into the TS clot. A second Solitaire 6 mm x 40 mm SR was deployed into the clot, below the first SR. After 5 minutes, both SRs and the aspiration catheter were removed with continuous aspiration. This maneuver was performed two additional times with further recanalization of the right TS and SS. Two days later she returned to baseline. She had 2 more recurrences due to re-occlusion of her TS and underwent EVT for both. She was discharged on apixaban and 6-week clinic follow up demonstrated a normal neurologic exam.

In case 2 the aspiration catheter was advanced into the lateral left TS. A Solitaire 6 mm x 40 mm SR was deployed into the left TS-SS junction. The SR and aspiration catheter were removed with continuous aspiration with recanalization of the left SS. Two Solitaire 6mm SRs were deployed from the SS to the IJV and then removed with continuous aspiration with significant recanalization of the left IJV. She was discharged on apixaban. Follow up eye exam demonstrated resolution of papilledema.

Conclusions:

The average diameter of the dural sinuses is 8 mm compared to the average size of the middle cerebral artery 3-4 mm. The largest available SR in the US is 6 mm and the largest outer diameter of available aspiration catheters is 2-3 mm. Due to the larger size of the dural sinuses, using two SRs can result in more efficient recanalization and less radiation.

Keywords: Cerebral Sinus And Venous Thrombosis, Cerebral Sinus Thrombosis Therapy, Stent retriever, Endovascular Therapy, Solitaire

Financial Disclosures: Stryker Neurovascular - consultant, lecturer Penumbra Inc, consultant, lecturer

Grant Support: None.

Poster

Nationwide Practices of Endovascular Carotid Revascularization Following Intracranial Thrombectomy for Acute Stroke with Tandem Occlusion

Aayushi Garg, MD¹, Aayushi Garg, MD¹, Mudassir Farooqui, MPH¹, Darko Quispe Orozco, MD¹, Cynthia Zevallos, MD¹, Alan Mendez Ruiz, MD¹, Kaustubh Limaye, MD¹, Santiago Ortega, MD¹

¹*University of Iowa Hospitals and Clinics, Iowa City, United States of America*

Introduction:

Approximately 20% of all patients with acute ischemic strokes due to anterior circulation large vessel occlusion (LVO) have concurrent cervical internal carotid artery (ICA) tandem lesion. In the absence of randomized controlled data to guide the treatment decisions, the approach towards carotid revascularization in this patient population is heterogeneous and is largely driven by individual or institutional preferences. In this study, we aimed to evaluate the current practice patterns of endovascular carotid revascularization following mechanical thrombectomy (MT) for anterior circulation LVO in the United States.

Methods:

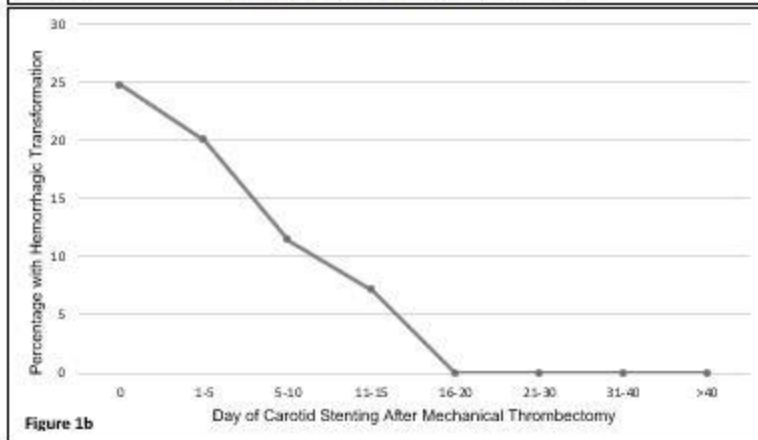
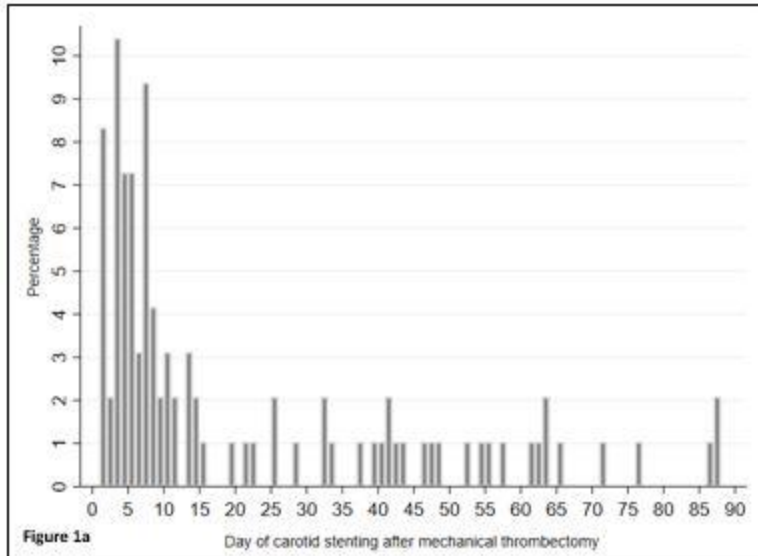
We used the Nationwide Readmissions Database 2016-2017 to identify patients admitted with anterior circulation LVO treated with MT. Patients who underwent carotid artery stenting (CAS) or carotid artery angioplasty (CAA) within 90 days of MT were also identified. Survey design methods were used to generate national estimates.

Results:

We identified 15,137 hospitalizations undergoing anterior circulation MT (mean±SD age:70.1±14.6, female 51.1%). Of these, 2,042 (13.5%) hospitalizations had carotid revascularization (CAS or CAA) performed on the same day as MT. Among these, CAA alone was performed in 651 (31.9%) cases and CAS in 1,391 (68.1%) cases. CAS was performed non-emergently (day 2-90 of MT) in 206 (14.8%) cases. Among these patients, CAS was done during the same hospitalization as MT in 104 (50.5%) cases, and during a readmission in the remaining 102 (49.5%) cases. Figure 1a shows the days of non-emergent CAS following MT and figure 1b shows the risk of hemorrhagic transformation according to the day of CAS from MT.

Conclusions:

Despite the existing reservations regarding the safety of acute carotid revascularization, we find that a vast majority of these procedures are being performed in the emergent setting during MT.



Keywords: Carotid Stenting And Angioplasty

Financial Disclosures: The authors had no disclosures.

Grant Support: None.

Poster

CEA V/s CAS For Symptomatic Carotid Stenosis: Bet On The Jockey, Not On The Horse

Rushabh M Chheda, Resident Neurosurgeon¹, Batuk Diyora, Professor¹

¹Lokamanya Tilak Municipal Medical College And General Hospital, Sion, Mumbai, India

Introduction:

Internal carotid artery (ICA) atherosclerosis is a major risk factor for stroke especially in patients with amaurosis fugax or transient ischaemic attack (TIA), and leads to approximately 30% of all ischemic strokes. 2–6% annual risk of stroke is observed in patients with asymptomatic stenosis of >50% while symptomatic carotid stenosis accounts for an even higher annual risk of stroke. Treatment modalities for carotid stenosis include medical management (treatment of vascular risk factors), carotid endarterectomy (CEA), and carotid artery stenting (CAS), which have shown to decrease the risk of subsequent stroke and reduces stroke-related morbidity and mortality.

In the 1990s, endovascular treatments (first balloon angioplasty and then stenting) emerged as a safer and less invasive alternative to endarterectomy, especially in high-risk cases. However, trials such as Stent-Protected Angioplasty versus Carotid Endarterectomy SPACE, Stenting and Angioplasty with Protection in Patients at High Risk for Endarterectomy SAPHIRE, and Carotid Revascularization Endarterectomy versus Stenting Trial CREST have failed to demonstrate significant short or long term differences between the 2 cohorts receiving CEA or CAS with distal protection with respect to the combined primary endpoint of stroke, death, and myocardial infarction (MI). Because most of these trials were performed in academic centers, a vigorous training course was required for the surgeons and interventionists selected to enroll in these trials. This has raised a concern regarding the generalization of these results and has made it necessary to determine whether similar results can be obtained in community settings by a single hybrid neurosurgeon. Aim And Objective:-

To study the outcome and adverse events associated with CEA and CAS.

To determine the generalization of results obtained with multicentric trials such as CREST, etc by comparing the results obtained by a single neurosurgeon in a community setting.

Methods:

From Jan 2014 - Dec 2017, 80 patients presented with symptomatic carotid stenosis. Out of these 80 patients, 65 underwent intervention; 34 patients underwent CEA and 31 patients underwent CAS. Pre-defined variables like age, sex, and degree of stenosis were assessed as potential risk factors, and the patient's clinical features, radiological imaging, and procedural complications were documented. The high surgical risk was defined based on anatomic criteria (Stenosis extending cavernous carotid, previous ipsilateral neck surgery or radiation, contralateral laryngeal nerve paralysis), and clinical criteria (age >80 years, decompensated liver disease, compromised cardiopulmonary reserve and valvular heart disease).

Results:

The primary outcome of procedure-related stroke, major adverse events(MAEs), and death at 30 days follow-up and long term outcomes of restenosis at 1 year were analyzed. Peri-procedural stroke occurred in 2 cases(6.4%) of CAS; One suffered an ischemic stroke, other suffered a hemorrhagic stroke. 3 cases of CEA suffered procedure-related events; One(2.9%) suffered TIA while the other two developed postoperative hematoma without neurological deficit; one was treated conservatively while

the other required re-exploration due to pressure symptoms. Restenosis occurred in one case that underwent CAS.

Conclusions:

CAS and CEA are complementary approaches in treating symptomatic carotid stenosis even when performed by a single hybrid neurosurgeon as results obtained are commensurable to major studies like CREST.

Keywords: Carotid Stenting And Angioplasty, CEA, TIA, Extracranial Stenosis, Balloon Angioplasty

Financial Disclosures: The authors had no disclosures.

Grant Support: None.

Poster

Post-procedural Antiplatelets After Tandem Lesions Stroke Thrombectomy – Impact on Carotid Stent Patency Beyond Day-1

Raoul Pop, MD, PhD¹, Anca Haisu, MD¹, Pierre H Mangin, PhD², Francois Severac, MD¹, Dan Mihoc, MD¹, Daiana Nistoran, MD¹, Mihaela Simu, MD PhD³, Salvatore Chibbaro, MD PhD¹, Roxana Gheoca, MD¹, Veronique Quenardelle, MD¹, Olivier Rouyer, MD PhD¹, Valerie Wolff, MD PhD¹, Remy Beaujeux, MD PhD¹

¹Strasbourg University Hospitals, Strasbourg, France; ²Strasbourg University, Strasbourg, France; ³Victor Babes University of Medicine and Pharmacy Timisoara Romania

Introduction:

Post-procedural dual antiplatelet therapy (DAPT) is frequently withheld after emergent carotid stenting during stroke thrombectomy. We aimed to assess whether antiplatelet regimen variations increase the risk of stent thrombosis beyond post-procedural day 1.

Methods:

Retrospective review of all consecutive thrombectomies for acute stroke with tandem lesions in the anterior circulation performed in a single comprehensive stroke center between 01.09.2011–30.03.2020. Patients were included if carotid stent patency was confirmed at day 1 post-procedure. The group of patients with continuous DAPT from day 1 was compared with the group of patients with absent/discontinued DAPT.

Results:

Out of a total of 109 tandem lesion thrombectomies, 96 patients had patent carotid stents at the end of the procedure. Early post-procedural stent thrombosis rate during the first 24 hours was 14/96(14.5%). Out of 82 patients with patent stents at day 1, in 28(34.1%), DAPT was either not initiated at day 1 or discontinued thereafter. After further exclusion of cases without further controls of stent patency, there was no significant difference in the rate of subacute/late stent thrombosis between the two groups: 1/50(2%) in patients with continuous DAPT versus 0/22(0%) in patients with absent/discontinued DAPT($p=1.000$). In total, we observed 88 patient days without any antiplatelet treatment and 471 patient days with single antiplatelet treatment.

Conclusions:

Discontinuation of DAPT was not associated with increased risk of stent thrombosis beyond post-procedural day 1. Further studies are warranted to better assess the additional benefit and optimal duration of DAPT after tandem lesion stroke thrombectomy.

Keywords: Carotid Stenting And Angioplasty, Mechanical Thrombectomy, Stenting, Stroke

Financial Disclosures: The authors had no disclosures.

Grant Support: None.

Poster

One Year Outcomes Of Aneurysm Treated Patients From The SMART Registry

Ashish Nanda, Dr.¹, Min S Park, Dr.², Richard J Bellon, Dr.³, Bradley N Bohnstedt, Dr.⁴, Clemens M Schirmer, Dr.⁵, Reade A De Leacy, Dr.⁶, David J Fiorella, D⁷, B. K Woodward, Dr.⁸, Blaise W Baxter, Dr.⁹, Osama O Zaidat, Dr.¹⁰, Peter J Sunenshine, Dr.¹¹, Albert J Yoo, Dr.¹², Mouhammed R Kabbani, Dr.¹³, Kenneth C Liu, Dr.¹⁴, Robert M Starke, Dr.¹⁵, Alan R Reeves, Dr.¹⁶, Keneth V Snyder, Dr.¹⁷, Thinesh Sivapatham, Dr.¹⁸, Travis M Dumont, Dr.¹⁹, Alejandro M Spiotta, Dr.²⁰

¹S.S.M. St. Clare Healthcare, Fenton, Missouri, United States of America; ²University of Virginia, Charlottesville, Virginia, United States of America; ³Swedish Medical Center, Denver, Colorado, United States of America; ⁴Indiana University Health Physicians, Indianapolis, Indiana, United States of America; ⁵Geisinger Medical Center, Danville, Pennsylvania, United States of America; ⁶Mount Sinai, New York, New York, United States of America; ⁷Stony Brook University Medical Center, New York, New York, United States of America; ⁸Vista Radiology, Knoxville, Tennessee, United States of America; ⁹Tennessee Interventional Associates, Chattanooga, Tennessee, United States of America; ¹⁰St Vincent Mercy Health Medical Center, Toledo, Ohio, United States of America; ¹¹Banner University Medical Center, Phoenix, Arizona, United States of America; ¹²Texas Stroke Institute, Dallas-Fort Worth, Texas, United States of America; ¹³Gundersen Health System, La Crosse, Wisconsin, United States of America; ¹⁴Penn State Milton S. Hershey Medical Center, Hershey, Pennsylvania, United States of America; ¹⁵University of Miami, Miami, Florida, United States of America; ¹⁶University of Kansas, Kansas City, Kansas, United States of America; ¹⁷University of Buffalo, Buffalo, New York, United States of America; ¹⁸Christiana Care Health System, Newark, Delaware, United States of America; ¹⁹University of Arizona, Tucson, Arizona, United States of America; ²⁰Medical University of South Carolina, Charleston, South Carolina, United States of America

Introduction:

The SMART COIL System (Penumbra, Inc) includes a novel generation of embolic coils comprised of complex and WAVE shape properties with varying levels of softness to promote dense packing and durable long-term occlusion. We report a subset analysis to assess the durability of treatment with SMART COIL System at one-year in patients with aneurysms enrolled in the SMART Registry.

Methods:

The SMART Registry is a prospective, multi-center study. Procedures must employ $\geq 75\%$ of the SMART, PC400, or POD coils to meet the registry criteria. SMART Registry endpoints include retreatment rates at one year, procedural device-related serious adverse events (SAE), and the ability to achieve adequate occlusion at immediate post-procedure.

Results:

Of the overall 995 patients enrolled, 91% (905/995) of patients were treated for aneurysms (74.7% female; mean age 59.8 ± 12.64 years). Mean aneurysm size was 6.9 mm (SD 3.6), 16.9% (153/905) small (< 4 mm), 68.45% (619/905) medium (≥ 4 to 10 mm), 14.5% (131/905) were large (> 10 to 25 mm), 0.2% (2/905) giant (> 25 mm), 31.8% (288/905) ruptured, and 63.5% (554/872) and wide-neck (dome-to-neck ratio < 1.5 or neck width ≥ 4 mm). During treatment, unassisted coiling was performed in 43.3% (392/905), stent-assisted coiling (SAC) in 37.2% (337/905), and balloon-assisted coiling (BAC) in 20.3%

(184/905) of patients. Mean aneurysm packing density was 32.3% (SD 18.21) and 83.3% (724/869) of the first framing coil were completely conformed to lesion morphology. In patients with aneurysms, retreatment rate at one year was 7.1% (52/731). Procedural device-related SAE were observed in 2.9% subjects (26/905). Raymond Class I and II was observed in 79.7% (717/900) at immediate post-procedure and in 90.0% (641/712) at one year. In multivariable analysis, independent predictors of Raymond Class III occlusion or retreatment at one year were large/giant aneurysm size (OR 2.71, 95% CI 1.36-5.41, P=0.0048), Raymond Class III immediately post-procedure (OR 2.04, 95% CI 1.08-3.83, P=0.0270), male gender (OR 1.82, 95% CI 1.02-3.24, P=0.0428), and ruptured aneurysm (OR 4.50, 95% CI 2.57-7.88, P=<0.0001).

Conclusions:

SMART COIL System achieves adequate embolization and retreatment rates in aneurysms at one year. Predictors for Raymond Class III or retreatment were Raymond Class III immediately post-procedure, large/giant aneurysms, male gender, and ruptured aneurysms.

Table 1: SMART Registry One Year Outcomes in Patients Treated for Aneurysms

Outcome	Aneurysm Subgroup (N=905)
Baseline and Procedural	
Female	74.7% (676/905)
Age	59.8 ± 12.64 years
Aneurysm Size, mean (SD)	6.9 mm (3.62)
Small, <4 mm	16.9% (153/905)
Medium, ≥4 to 10 mm	68.4% (619/905)
Large, >10 to 25 mm	14.5% (131/905)
Giant, >25 mm	0.2% (2/905)
Ruptured	31.8% (288/905)
Wide-neck aneurysm	63.5% (554/872)
Stent-Assisted Coiling	37.2% (337/905)
Balloon-Assisted Coiling	20.3% (184/905)
Mean Packing Density [SD]	32.3% [18.21]
Endpoints	
Retreatment	7.1% (52/731)
Procedural Device-related SAEs	2.9% (26/905)
RROC I+II (Adequate occlusion) immediate post-procedure	79.7% (717/900)
Additional Outcomes	
RROC I+II (Adequate occlusion) at one year	90.0% (641/712)
Device-Related Mortality at one year	0.1% (1/905)
Modified Rankin Score, 0-2 (Adequate Occlusion)	84.4% (429/508)

Keywords: Penumbra, Aneurysm, Aneurysm Embolization, Clinical Trial

Financial Disclosures: The authors had no disclosures.

Grant Support: None.

Poster

Impact of Admission-to-Puncture Time on Mechanical Thrombectomy Outcomes for Large Vessel Occlusion Acute Ischemic Stroke

Osama O Zaidat, MD, MS, FAHA, FAAN, FSVIN¹, Johanna T Fifi, MD, FAHA, FSVIN², Ameer E Hassan, DO, FAHA, FSVIN³

¹Mercy Health St. Vincent Medical Center, Toledo, Ohio, United States of America; ²Icahn School of Medicine at Mount Sinai, New York, New York, United States of America; ³University of Texas Rio Grande Valley at Valley Baptist Medical Center, Harlingen, Texas, United States of America

Introduction:

To understand if large vessel occlusion acute ischemic stroke (LVO-AIS) patients managed with mechanical thrombectomy benefit from improved hospital admission-to-puncture times.

Methods:

Using data from the COMPLETE registry, this analysis compares patients with admission-to-puncture times of ≤ 90 mins to those with admission-to-puncture times of > 90 mins. Only patients with anterior circulation occlusions who were directly admitted to a treating center (i.e. not transferred) were included.

The COMPLETE registry was a global prospective multicenter study that enrolled LVO-AIS patients aged ≥ 18 years with pre-stroke modified Rankin Scale (mRS) 0-1 who underwent mechanical thrombectomy using the Penumbra System with or without the 3D Revascularization Device (Penumbra, Inc). The primary safety endpoint was 90-day all-cause mortality. The primary efficacy endpoints were successful post-procedure angiographic revascularization (modified thrombolysis in cerebral infarction [mTICI] $\geq 2b$) and 90-day functional outcome (mRS 0-2). Secondary endpoints included incidence of device- or procedure-related serious adverse events (SAEs), occurrence of embolization in previously uninvolved or new territories (ENT), and occurrence of symptomatic intracranial hemorrhage (sICH) at 24 hours. A core lab evaluated imaging findings and independent medical reviewers reviewed and adjudicated clinical events related to the safety endpoints.

Results:

Of the COMPLETE registry's 650 patients, 269 were included in this analysis. The cohorts were similar with respect to gender, race, ethnicity, ASPECT scores, target vessel locations, pre-procedure IV tPA use, and onset-to admission times. The ≤ 90 min cohort was younger ($p=0.02$), had higher NIHSS ($p=0.04$), and faster onset-to-mTICI 2b-3 times ($p<0.01$). Rates of post-procedure mTICI 2b-3 were similar between cohorts.

The ≤ 90 min cohort experienced significantly fewer device- or procedure-related SAEs (2.7% vs 9.2%, $p = 0.03$), non-significantly lower rates of sICH within 24 hours (2.0% vs 6.7%, $p=0.07$), and non-significantly higher rates of 90-day mRS 0-2 (67.6% vs 56.0%, $p=0.07$). Additional details available in the table. In multivariable analysis of mRS 0-2 at 90 days, (adjusting for age, baseline NIHSS, IV tPA, mTICI 2b-3 post-procedure, and location), door-to-puncture within 90 minutes yielded a p-value of 0.075.

Conclusions:

In this analysis of the COMPLETE registry, we found that LVO-AIS patients treated with mechanical thrombectomy within 90 minutes of admission had better functional independence and fewer complications.

Baseline	≤ 90 mins (N = 149)	> 90 mins (N = 120)	p-value
Age, years	67.0 (14.3)	71.3 (13.3)	0.0186
Female	55.7% (83/149)	56.7% (68/120)	0.8744
Race*			
American Indian or Alaska Native	0.0% (0/93)	0.0% (0/71)	0.2585
Asian	2.2% (2/93)	2.8% (2/71)	
Black or African American	9.7% (9/93)	12.7% (9/71)	
Native Hawaiian or Other Pacific Islander	0.0% (0/93)	0.0% (0/71)	
White	88.2% (82/93)	78.9% (56/71)	
Other	0.0% (0/93)	1.4% (1/71)	
Not Reported	0.0% (0/93)	4.2% (3/71)	
Ethnicity*			
Hispanic or Latino	8.6% (8/93)	15.5% (11/71)	0.3664
Not Hispanic or Latino	89.2% (83/93)	81.7% (58/71)	
Not Reported	0.0% (0/93)	2.8% (2/71)	
Unknown	1.1% (1/93)	0.0% (0/71)	
NIHSS	15.0 [10.0, 21.0]	13.0 [8.0, 18.0]	0.0439
ASPECT Score	8.0 [7.0, 9.0]	9.0 [7.0, 10.0]	0.1093
Target Vessel			
ICA	4.7% (7/149)	4.2% (5/120)	0.1300
ICAT	12.8% (19/149)	15.0% (18/120)	
MCA M1	66.4% (99/149)	52.5% (63/120)	
MCA M2	12.8% (19/149)	25.8% (31/120)	
MCA M3	2.7% (4/149)	0.8% (1/120)	
ACA A2	0.7% (1/149)	1.7% (2/120)	
IV tPA pre-procedure	53.7% (80/149)	45.0% (54/120)	0.1564
Time from onset to admission, mins	96.0 [57.0, 229.0]	85.0 [53.0, 279.0]	0.4128
Time from admission to puncture, mins	67.0 [51.0, 78.0]	116.0 [102.0, 152.0]	<0.0001
Time from onset to puncture, mins	163.0 [120.0, 295.0]	225.0 [175.0, 428.0]	<0.0001
Procedure			
Time from onset to mTICI 2b-3 else final angiogram, mins	199.0 [146.0, 345.0]	283.0 [211.0, 466.5]	<0.0001
Frontline treatment			
Aspiration only	68.5% (102/149)	61.7% (74/120)	0.2493
Aspiration with 3D	31.5% (47/149)	36.7% (44/120)	0.4369
mTICI 2b-3 Post-Frontline	65.1% (97/149)	52.5% (63/120)	0.0455
Endpoints			
90-day mRS 0-2	67.6% (96/142) (59.9%, 75.3%)	56.0% (65/116) (47.0%, 65.1%)	0.0704

mTICI 2b-3 post-procedure	87.9% (131/149) (82.7%, 93.2%)	87.5% (105/120) (81.6%, 93.4%)	1.000
90-day all-cause mortality	12.8% (19/149) (7.4%, 18.1%)	15.0% (18/120) (8.6%, 21.4%)	0.5988
Device- or Procedure-Related SAE, ≤ 24 hrs	2.7% (4/149) (0.1%, 5.3%)	9.2% (11/120) (4.0%, 14.3%)	0.0304
ENT, at end of procedure	4.0% (6/149) (0.9%, 7.2%)	2.5% (3/120) (0.0%, 5.3%)	0.7354
siCH, ≤ 24 hrs	2.0% (3/149) (0.0%, 4.3%)	6.7% (8/120) (2.2%, 11.1%)	0.0674

*Ethnicity and Race information are only collected for US

Keywords: Acute Ischemic Stroke Intervention, Door To Groin Puncture, Endovascular, Mechanical Thrombectomy, Penumbra

Financial Disclosures: Grant/research/other financial or material support: Genentech, Medtronic Neurovascular, Stryker; Consultant: Codman, Medtronic Neurovascular, National Institutes of Health StrokeNet, Penumbra, Stryker; Ownership interest: Galaxy Therapeutics, LLC

Grant Support: None.

Poster

Upper extremity only access for combined transarterial and transvenous neuro interventional procedures

Muhammad Z Memon, MD¹, Taha Nisar, MD¹, Amit Singla, MD¹, Priyank Khandelwal, MD¹

¹Rutgers, The State University of New Jersey, Newark, New Jersey, United States of America

Introduction:

A concurrent arterial and venous access is routinely obtained for diagnosis and treatment of dural arteriovenous fistula (DAVFs) and arteriovenous malformation (AVMs). Recently indication is expanded for venous sinus manometry and stenting in pseudotumor cerebri patients. Traditionally venous approaches are performed by direct internal jugular puncture or by femoral vein access. Although complication rates are low, serious life-threatening complications have been reported. The advantages of radial artery access have been widely proven, nevertheless the use of upper limb veins in neurointervention is rare.

Methods:

We present two cases of the concurrent arteriovenous approach through the radial artery and basilic vein of the forearm for diagnostic cerebral angiography and venous manometry in pseudotumor cerebri patients. Radial access was obtained by using the standard technique and venous access was obtained by cannulating basilic vein using ultrasound guidance and 6 F short sheath was placed. Venous angiography was then performed by using 6 F Envoy guide catheter over SIM select catheter into the right and left internal jugular veins followed by venous manometry by using XT 27 microcatheter over synchro 2 microwire.

Results:

Procedures were successfully completed with no adverse effects and patients were discharged home the same day.

Conclusions:

Our initial experience indicates that the concurrent approach through the radial artery and basilic forearm vein is feasible and safe and should be considered for neurointerventional procedures

Keywords: New Technique, Endovascular

Financial Disclosures: The authors had no disclosures.

Grant Support: None.

Poster

Transradial Access for Thrombectomy in Acute Stroke: A Systematic Review and Meta-Analysis

Catherine Peterson, Resident¹

¹*University of California, Davis, Sacramento, California, United States of America*

Introduction:

Numerous randomized controlled trials have demonstrated important clinical benefits of endovascular therapy for acute ischemic stroke. Transfemoral access has been the standard access for such interventions. Recently, in light of evidence demonstrating non-insignificant access site related complications associated with the transfemoral approach, alternative routes such as the transradial access have begun to be investigated. To this day, a systematic review and meta-analysis investigating the outcomes of transradial access for mechanical thrombectomy in acute stroke have not been performed.

Methods:

PubMed, Embase, and Scopus databases were systematically searched, and results were reported according to the PRISMA guidelines. Studies published in the last ten years reporting on the use of transradial access for acute stroke intervention were eligible. The transfemoral group used for a portion of meta-analysis was composed of contemporary randomized controlled trials pertaining to thrombectomy in acute stroke: the ESCAPE, EXTEND, MR CLEAN, REVASCAT, SWIF PRIME, DAWN, DEFUSE, THRACE, and PISTE clinical trials. The DerSimonian–Laird random effects model was used, and the primary endpoints included puncture to reperfusion time, end mRS, TICI reperfusion, mortality, and access site complications.

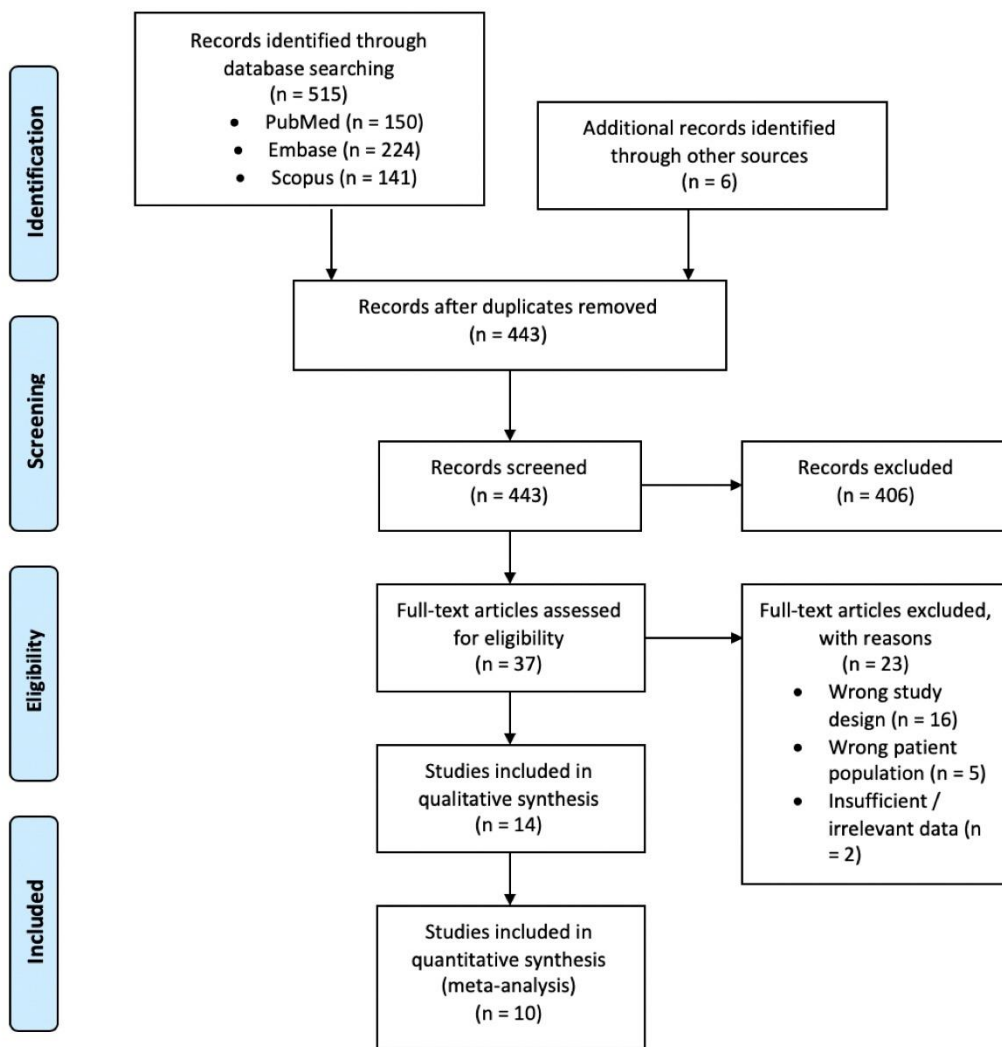
Results:

A total of 515 records were identified. Fourteen observational studies reported on the use of radial access for thrombectomy, and 10 of these studies (n=309) were included in the meta-analysis. Mean puncture to reperfusion time associated with the transradial access was 46.864 ± 6.601 minutes. Favorable end mRS of 2 or less was reported in $37.1\% \pm 7.3\%$ of patients. TICI 2B or higher was achieved in $84.6\% \pm 3.4\%$ of patients. All-cause mortality was observed in $9.3\% \pm 4.8\%$ of patients. Transradial access had low complications with only $1.4\% \pm 0.7\%$ of the cases. When the transradial studies were compared to the contemporary randomized clinical trials using the standard transfemoral access, no significant differences were found in all of these primary outcomes.

Conclusions:

Our meta-analysis demonstrates that the transradial access may be a safe and feasible alternative for mechanical thrombectomy in acute stroke. Future prospective studies are needed to validate these results.

Figure 1: PRISMA Flow Diagram



Keywords: Acute Ischemic Stroke Intervention, Acute Stroke, Cerebrovascular Disease, Revascularization, Mechanical Thrombectomy

Financial Disclosures: The authors had no disclosures.

Grant Support: None.

Poster

Time Resolved Contrast Enhanced MRA with Volumetric High Resolution T2 in Localizing Spinal Dural AVF

Maria G Martucci, MD¹, Avi Oppenheimer, MD¹, Michael Moogerfeld, RT (MR)¹, Michal Obrzut, MD¹

¹*Cleveland Clinic Florida, Weston, Florida, United States of America*

Introduction:

Objective: To describe a non-invasive method for prospectively localizing Spinal Dural AV Fistulas (SDAVF) with contrast enhanced magnetic resonance imaging prior to spinal angiography and treatment, by combining Time Resolved Contrast Enhanced MR Angiography (TRCE-MRA) with Volumetric High Resolution T2-weighted Imaging (VHR-T2-I) sequences. Background: The gold standard for the localization of SDAVF is spinal angiography. A complete spinal angiogram involves the sampling of all segmental arteries, which can be time consuming and carries the risks of contrast nephropathy and radiation exposure. A non-invasive method of prospectively localizing the SDAVF feeding segmental arteries would be highly beneficial, as it would allow focusing the spinal angiogram to only a few vessels, decreasing procedure time and mitigating these risks. TRCE-MRA has been utilized in the localization of SDAVFs in the past. This method, however, has been limited by the inherent tradeoff that exists between temporal and spatial resolution in MR imaging. Even on advanced 3 Tesla systems, TRCE-MRA of the spine at frame rates higher than 1 per 2 seconds have poor signal to noise and anatomical detail, making the identification of the small SDAVF feeding vessels a challenge. VHR-T2-I sequences have very high anatomical detail but cannot assess vessel flow. In this case series, we present a method that co-registers the temporal information from TRCE-MRA and the spatial information from VHR-T2-I to prospectively identify the feeding vessels of SDAVFs with a very high accuracy.

Methods:

Methods: Five consecutive patients with clinical and imaging findings consistent with SDAVF underwent 3 Tesla CE-MRA on a Siemens MAGNETOM Skyra system prior to spinal angiography. For each patient, Siemens Time-resolved angiography With Stochastic Trajectories (TWIST) sequences at frame rates of 1 per 2 seconds or higher were obtained. A single slab 3D single slab turbo spin echo (SPACE) sequence was then obtained and the sequences were co-registered. The images were reviewed by a neuroradiologist and the feeding segmental artery to the SDAVF was identified. Subsequently, each patient underwent spinal angiography. In all patients the segmental artery feeding the SDAVF was correctly prospectively identified by the CE-MRA.

Results:

Results: In all patients in this case series, CE-MRA with TWIST/SPACE co-registration prospectively identified the SDAVF feeding artery. This resulted in a reduction in procedure time, contrast dose and radiation exposure. No procedure complications were encountered. In one patient with advanced atherosclerotic disease, the CE-MRA was critical in identifying the SDAVF feeding artery, as severe stenosis at the origin of the feeding artery made catheterization difficult and the vessel might have been missed if not for the prospective information from the CE-MRA.

Conclusions:

Conclusion: This case series illustrates how combining TRCE-MRA and VHR-T2-I can prospectively identify the feeding segmental branches of SDAVFs, resulting in reduced procedure time and risks of pre-treatment spinal angiography.

Keywords: MRI, MRA, Angiogram, Interventional Neuroradiology, Imaging

Financial Disclosures: The authors had no disclosures.

Grant Support: None.

Poster

Optical Coherence Tomography in Carotid Web

Alhamza R. Al-Bayati, MD¹, Raul G Nogueira, MD¹, Rajesh Sachdeva, MD², Mahmoud H Mohammaden, MD¹, Diogo C Haussen, MD¹

¹Emory University/Grady Memorial Hospital, Atlanta, Georgia, United States of America; ²Grady Memorial Hospital, Atlanta, Georgia, United States of America

Introduction:

Carotid web (CaW) is an intimal variant of fibromuscular dysplasia described as a shelf-like filling defect in the posterior aspect of the carotid bulb which may generate thromboembolism and stroke. The diagnosis of CaW is based on vascular imaging using CT or MR angiography, as well as digital subtraction angiography (DSA). Intravascular ultrasound (IVUS) has been investigated and shown to have limited value in characterizing CaWs. Optical coherence tomography (OCT) is a catheter-based system that acquires images at a resolution of ~10µm, enabling visualization of the blood vessel wall at near histological resolution, thus it has the potential to be a useful imaging modality.

Methods:

Retrospective review of patients in which OCT was used as an additional investigative tool in acute ischemic stroke work-up when there was suspicion for CaW but clinical and/or radiological findings were unusual. A Dragonfly Optis Imaging Catheter (Abbott Cardiovascular, Abbott Park, IL) was navigated over a 0.014" microwire into the internal carotid artery and images were acquired along with an 8cc/sx40cc power injector angiogram. OCT images were analyzed using M2 OCT Imaging system, LightLab Imaging, Inc., Westford, MA).

Results:

Six patients were included. Median (IQR) age is 54.5 years. 50% were male. All patients except one had proximal large vessel occlusion (LVO) and underwent mechanical thrombectomy. All patients had DSA of bilateral common carotid arteries for treatment or investigation of large vessel occlusion strokes and had available CT angiography images. One patient (16%) had bilateral lesions. The baseline characteristics and OCT imaging findings summarized in **Table-1**. OCT ruled out the presence of underlying CaW in 2 patients (33%) whom their lesions were consistent with atherosclerotic disease and corroborated a CaW diagnosis in the remaining patients. The ridge was uniformly well demonstrated; however, the CaW pocket could not be optimally visualized. All cases were technically successful, and no complications occurred.

Conclusions:

OCT was found to have value as a complimentary vessel-wall imaging tool in the investigation of patients with suspected CaW. Further studies are warranted.

Case #	Age	Gender	LVO	CaW Laterality	Comorbidities	OCT findings
--------	-----	--------	-----	----------------	---------------	--------------

1	53	M	Yes	Bilateral	HTN, tobacco, CHF, CKD.	Bulge in the vessel wall with hyperintense rim representing the carotid web membrane and adjacent CaW pouch without superimposed thrombus or atherosclerotic changes at the bulb.
2	52	M	Yes	Right *	HTN.	CaW membrane without superimposed thrombus. Small sidewall RBC rich thrombus is noted distal to the right carotid bulb without underlying atherosclerosis.
3	63	M	No	Left *	HTN, Tobacco dependence.	Non fibrotic, lipid rich, lesion at the left carotid bifurcation with thin fibrous cap consistent with atherosclerotic non-hemodynamically significant stenotic lesion without evidence of underlying CaW.
4	41	F	Yes	Right *	HTN.	Fibrotic membrane with adjacent pouch consistent with underlying right CaW.
5	56	F	Yes	Right *	HTN, DM, Tobacco.	Endoluminal projection of fibrotic tissue compatible with a CaW.
6	80	F	Yes	Bilateral	HTN, AFib, breast cancer.	Left (stroke side): Thin fibrous cap consistent with atherosclerotic disease, foam cells and ulcerations with dropout compatible with atherosclerotic disease. Right: No evidence of atherosclerotic changes, smooth contoured intima, with higher density,

						compatible with either a thick fibrous cap or a CaW.
--	--	--	--	--	--	--

Legend: * Ipsilateral Ischemic Stroke; HTN: Hypertension, CHF: Congestive Heart Failure, CKD: Chronic Kidney Disease, CaW: Carotid Web

Table-1: Baseline characteristics of patients and their OCT findings

Keywords: Carotid, Diagnostic Neuroradiology, Acute Ischemic Stroke Intervention, Vascular Imaging, Stroke

Financial Disclosures: The authors had no disclosures.

Grant Support: None.

Poster

Factors Associated with Decreased Accuracy of mTICI Scoring Among Neurointerventionalists During Thrombectomy

Elliot Pressman, MD¹, Muhammad Waqas, MD², Victoria Sands, BS BA¹, Adnan H Siddiqui, MD PhD², Kenneth V Snyder, MD PhD², Jason M Davies, MD PhD², Elad I Levy, MD², Ciprian Ionita, PhD², Waldo R Guerrero, MD¹, Zeguang Ren, MD¹, Maxim Mokin, MD PhD¹

¹University of South Florida, Tampa, Florida, United States of America; ²University at Buffalo, State University of New York, Buffalo, New York, United States of America

Introduction:

The modified thrombolysis in cerebral infarct (mTICI) score is widely used to grade angiographic outcome after endovascular thrombectomy (ET). However, the accuracy of operator mTICI scores is not perfect. We sought to further characterize such discrepancies and identify factors that decrease the accuracy of intraprocedural mTICI scoring.

Methods:

We performed a two-center retrospective cohort study comparing angiographic operator (n=6) scores to ones from blinded core lab adjudicators. Patient characteristics, occlusion characteristics, and mTICI scores were analyzed. Groups were also assessed by dichotomizing mTICI scores to 0-2a versus 2b-3.

Results:

130 ET procedures were included. Operator and core lab adjudicators had pairwise agreement in 96 patients (73.8%). Eight cases (6.2%) featured operator underestimation, twenty-six cases (20.0%) overestimation of final mTICI. The unweighted κ statistic was 0.570 and weighted κ statistic was 0.721. Multivariate analysis showed ET overnight (Odds Ratio (OR)=3.84; 95% CI: 1.22-12.1; p=0.021), lacking frontal (OR=5.66; 95% CI: 1.36-23.6; p=0.017) or occipital (OR=7.18; 95% CI: 2.12-24.3; p=0.002) region reperfusion, and higher operator mTICI scores (OR=2.16; 95% CI: 1.16-4.01; p=0.015) were all predictive of incorrectly scoring an angiogram intraprocedurally. With dichotomized mTICI scores, increasing number of passes was associated with an increased risk of operator mistake (OR=1.93; 95% CI: 1.22-3.05; p=0.005).

Conclusions:

In our study, mTICI disagreement between operator and adjudicators was observed in 26.2% of cases. Interventions that took place between 22:30-4:00, featured frontal or occipital region non-perfusion, higher operator mTICI scores, and increased number of passes had higher odds of inaccuracy of mTICI grading.

Keywords: TICI, Acute Stroke, Endovascular Therapy, Interventional Neuroradiology, Mechanical Thrombectomy

Financial Disclosures: The authors had no disclosures.

Grant Support: None.

Poster

Penetrating Vertebral Artery Injuries: A Literature Review and Proposed Treatment Algorithm

Keaton Piper, Resident Neurosurgeon¹, Maxmilian Rabil, medical student², Maxim Mokin, MD³, Siverio Agazzi, MD³, Zeguang Ren, MD³, Waldo Guerrero, MD³

¹Tampa General Hospital, tampa, Florida, United States of America; ²USF School of Medicine, tampa, Florida, United States of America; ³USF Neurosurgery, Tampa, Florida, United States of America

Introduction:

Penetrating vertebral artery injuries (VAI) are rare but devastating traumas for which the approach to treatment varies greatly. The literature on treatment modalities is limited to case reports, case series and one review, with the majority of cases being treated surgically. However with the advent of digital subtraction angiography (DSA), treatment has shifted towards less invasive endovascular modalities that allows one to assess the flow and risks of sacrificing the vertebral artery (VA).

Methods:

In accordance with PRISMA, a systematic review of VAI was performed. Two new case reports were also detailed.

Results:

171 patients were identified. Of the penetrating VAI, the majority of occlusions were managed conservatively. The other injuries varied from pseudoaneurysm, dissection, transection, and arterial-venous fistula that were treated predominantly endovascularly with the rare surgical exploration/ligation. The majority of endovascular treatments included embolization without significant stroke or complication from VA sacrifice yet there are several instances in which VA sacrifice should be avoided that can be assessed by DSA

Conclusions:

This systematic review not only discusses updated treatment options but also provides a suggested decision algorithm for the treatment of penetrating VAI. This highlights the shifting treatment options for penetrating VAI to endovascular with variants to consider avoiding embolization and when to consider stenting. This also details the largest collection of stenting for penetrating VAI, an emerging treatment modality.

Keywords: Angiogram, Vertebral, Endovascular, Embolization, Endovascular Therapy

Financial Disclosures: The authors had no disclosures.

Grant Support: None.

Poster

Mechanical thrombectomy in the setting of an unruptured aneurysm and simultaneous emergent ischemic limb

Aravind Reddy, MD¹, Adam Blanden, MD¹, Neil Suryadevara, MD¹, Grahame Gould, MD¹

¹*Suny Upstate Medical University, Syracuse, New York, United States of America*

Introduction:

49 year-old woman presents with acute onset weakness and pain of right upper extremity on waking-up, found to have right axillary artery thrombosis at outside hospital. During ambulance transfer, patient developed new left arm and leg weakness. CTA showed tandem lesions including near occlusive thrombus in right ICA and right M1 MCA occlusion.

Methods:

Transfemoral cerebral angiogram was performed, which confirmed right ICA and right M1 lesions, as well as unruptured 8.3 x 7.0 x 5.7 mm broad neck right carotid ophthalmic aneurysm. Given the aneurysm's location and presence of mobile thrombus in right ICA, decision was made to perform flow arrest with balloon guide catheter, then aspiration thrombectomy of right MCA and ICA. Following reperfusion of right MCA, aspiration thrombectomy of right axillary, brachial, and ulnar arteries, and stent-retriever thrombectomy of right axillary artery were performed.

Results:

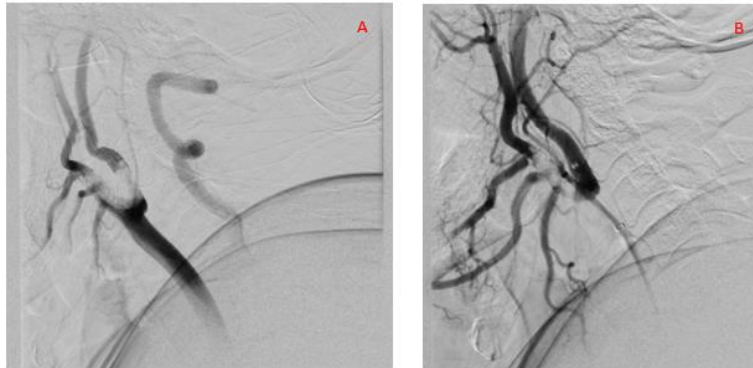
TICI2B recanalization of occluded right MCA was achieved with residual non-occlusive thrombus in right ICA. Large residual clot was left in right ECA, and small residual clots in right radial and interosseus arteries were untreated after thrombectomy in right upper extremity. Patient's NIHSS improved from 9 to 2 post-procedure, with mild residual left hemiparesis. Right hand perfusion and right arm pain improved.

Conclusions:

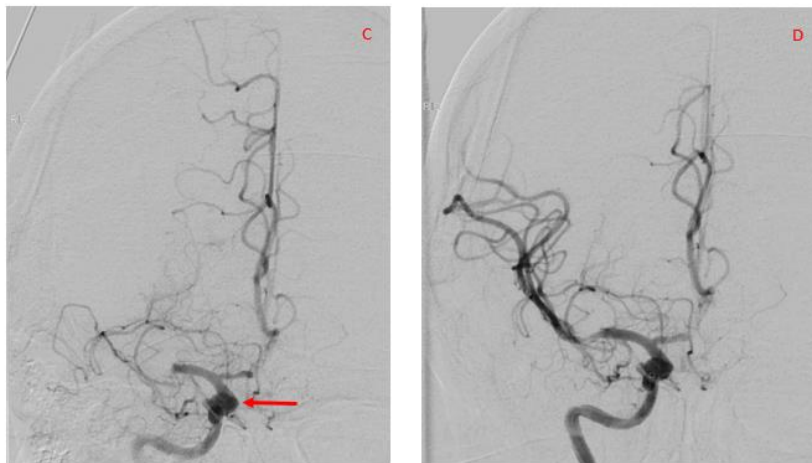
Post procedure, patient disclosed family history significant for young stroke, PE, and DVT. She was placed on therapeutic enoxaparin, then transitioned to rivaroxaban. Further work-up revealed persistently elevated Factor VIII activity on tests repeated 6 months apart.

The presence of large unruptured right carotid aneurysm proximal to right MCA occlusion presented technical challenges. Given the potential for catastrophic aneurysm rupture, aspiration was preferred to stent-retriever as it was considered to apply lower shear forces on the vessel wall during retrieval. While successful recanalization was achieved, the relative success rates of aspiration techniques versus stent-retriever in cases with target vessel aneurysms are not well-studied. While the first-pass success rate of recanalization with stent-retrievers is higher in general, the ultimate recanalization and functional outcomes between contact aspiration and stent-retrievers as first-pass techniques are identical. When appropriate, initial aspiration attempts should be considered followed by stent-retrievers if unsuccessful. Given the unique risks associated, careful analysis of CT angiography should be done so that these potential risks and outcomes can be disclosed to patients and family pre-procedure. Decision to pursue endovascular treatment of upper extremity thrombus was made with intra-procedural

consultation of vascular surgery, and was considered favorable given established catheter access for ipsilateral cerebral thrombectomy.



A: Right ICA and ECA thrombosis; B: Right ICA recanalized after aspiration, with residual thrombus in ECA



C: Right M1 occlusion; arrow – ophthalmic carotid aneurysm D: TICI 2B recanalization

Keywords: Acute Ischemic Stroke Intervention, Aneurysm, Mechanical Thrombectomy

Financial Disclosures: The authors had no disclosures.

Grant Support: None.

Poster

Post-angiographic Neurotoxic Encephalopathy: A Case Series and Comprehensive Literature Review

Nikil Swamy, MD MS¹, Joey English, MD PhD¹, Warren T Kim, MD PhD¹

¹California Pacific Medical Center (CPMC), San Francisco, California, United States of America

Introduction:

Post-angiography neurotoxicity is a rare complication seen after various angiographic procedures. It is commonly referred to as contrast-induced encephalopathy (CIE). Clinically, its varied presentations can mimic stroke. CIE is a diagnosis of exclusion, but in the absence of other explanations, this entity should be suspected.

Methods:

We present a retrospective review of four illustrative cases of CIE (and one unusual recurrence) following cerebral angiography and aneurysm embolization. Based on prior CIE literature and our thorough analysis of periprocedural data, we have formulated a hypothesis about the pathophysiology of this disease and identified potential contributory factors: chronic hypertension, antithrombotic use, guide catheter/sheath caliber, crystalloid use, blood pressure fluctuations, and electroencephalography (EEG).

Results:

Two of the four cases presented with symptoms of left cerebral hemisphere dysfunction, two with right-sided dysfunction. In three of the cases, the dominant A1 of the anterior cerebral artery (ACA) supplied ACA branches bilaterally, and there was edema in both ACA territories on follow-up CT, suggesting that CIE is related to the infusion of contrast, saline, or both.

There are certain risk factors that seem to predispose patients to CIE. The most common is chronic hypertension, which was a known diagnosis in two of the four patients. Intraprocedural blood pressure monitoring showed no significant sustained fluctuations that might cause disruption of the blood brain barrier (BBB). It is unclear if the size of the guide catheter or infused rate or volume of saline and/or contrast contributed to the downstream edema. However, all five procedures were long (median time = 300 minutes), and large volumes of heparinized-saline flush (mean volume = 2370 mL) and contrast (mean volume = 326 mL) were used.

This report is unique in its inclusion of intra- and peri-procedural EEG. With one exception, all the patients had diffuse background slowing with asymmetry over the edematous hemisphere.

There have been over 39 imaging-confirmed cases of CIE in the English-language literature. The pathophysiology is thought to be from contrast-induced disruption of the tight-junctions making up the BBB and increased pinocytosis, which results in vasogenic cerebral edema. However, most patients who undergo angiographic procedures, even long ones, do not develop CIE. We hypothesize that it manifests in a subset of cases when there is a combination of factors, e.g. predisposition from chronic hypertension, large volumes of intra-arterial crystalloid infusion over extended time periods, and repeated direct intra-arterial injections of contrast during selective angiography. Treatment for CIE has primarily involved fluid resuscitation and pharmacotherapies, including steroids, hyperosmolar therapy and, rarely, hemodialysis. In all our cases, the CIE was managed conservatively, was correlated with follow-up non-invasive imaging, and the symptoms resolved completely over a span of 4-5 days.

Conclusions:

Post-angiography neurotoxic encephalopathy, though rare, can be a stroke mimic and can prolong a patient's hospital course. By carefully monitoring all the potential periprocedural factors, we have identified some that clearly seem to contribute, while others do not. This lays the groundwork for further research to clarify the pathophysiology and to mitigate the risk factors for this disease.

Keywords: Aneurysm Embolization, Endovascular, New Innovation, Cerebrovascular Disease, Pathophysiology

Financial Disclosures: The authors had no disclosures.

Grant Support: None.

Poster

Encephaloceles, Epilepsy, Dural Sinus Stenosis: A Pressure Connection?

Michael G Abraham, MD, FAHA¹, Patrick X Landazuri, MD¹, Utku Uysal, MD¹, Carol Ulloa, MD¹, Jennifer Cheng, MD¹, Vishal Shah, MD¹

¹*University of Kansas Medical center, Kansas City, Kansas, United States of America*

Introduction:

Encephaloceles can be an etiology for epilepsy, particularly temporal lobe epilepsy. Epilepsy treatment includes antiseizure medications and when drug resistant, surgical resection. In a portion of our encephalocele cohort, we have noted neuroimaging findings related to idiopathic intracranial hypertension (IIH), most predominantly dural sinus stenosis. We describe three patients who underwent endovascular dural sinus stenting (EDSS).

Methods:

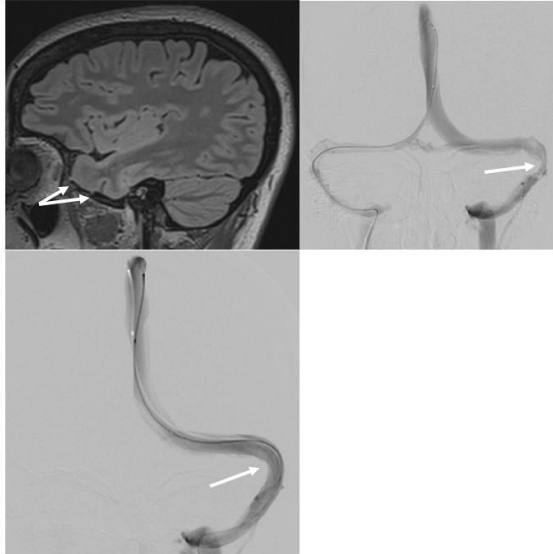Retrospective chart review.

Results:

Three patients with temporal lobe epilepsy secondary to encephaloceles with concomitant dural sinus stenosis underwent EDSS. Patients had no other signs of increased intracranial pressure (ICP) including a lack of papilledema, vision changes, or severe headaches associated with IIH. Two had a pre-stenting lumbar puncture with normal opening pressure. During EDSS, all patients were noted to have an elevated mean pressure gradient (MPG) across the stenosis (10-20 mmHg). All three had normalization of the MPG immediately after stenting. Two long term follow up venograms demonstrated persistence of a normal MPG and the third long term follow up is pending. The first patient underwent right temporal lobectomy with amygdalohippocampectomy, extended superior temporal gyrus resection, and repair of encephaloceles due to persistent seizures and no change in the numerous encephaloceles after EDSS. The second patient, with drug-resistant temporal lobe epilepsy, has been seizure free for 21 months since stenting with the last seizure occurring the day before stenting. The third patient recently underwent stenting, so long term follow-up is not available.

Conclusions:

It is unclear if dural sinus stenosis and resultant increased intracranial venous pressure potentially contributes to the pathogenesis of encephaloceles. EDSS was performed to lower intracranial venous pressure as a potential method of stabilizing existing encephaloceles and/or preventing additional encephaloceles from developing. Interestingly, one of our patients is 21months seizure free. As our cohort is small and this is a newly described treatment, we present the data to introduce this concept and invite collaboration to better understand this disease process and evaluate an alternate treatment strategy.



Keywords: Endovascular Therapy, Interventional Neuroradiology, Intracranial Stenosis Stenting And Angioplasty, New Innovation, Treatment

Financial Disclosures: The authors had no disclosures.

Grant Support: None.

Poster

Chemical Spasmolysis to Treat Ischaemic Stroke Caused by Rare Case of Vasospasm Complicating Bacterial Meningitis

Istafa J Raza, Surgical Resident¹, Charles Li, Neurosurgery Registrar¹, Phillip A Romo, Neurosurgery Registrar¹, Conor Houlihan, Fellow¹, Simon Ellul, ENT Surgeon¹, Anna Balabanski, Neurologist¹, Anoop Madan, Neurointerventionalist¹, Nicholas Maartens, Neurosurgeon¹

¹*Alfred Hospital, Melbourne, Australia*

Introduction:

Cerebral vasospasm (CVS) induced ischemic stroke is a rare complication of bacterial or fungal meningitis. Established endovascular paradigms for CVS are a potential treatment.

Methods:

Case report and systematic literature review.

Results:

A 50-year-old woman with a history of hypertension presented with bacterial meningitis following CSF leak post transsphenoidal resection of Rathke's cleft cyst. She developed acute left sided hemiplegia, left facial droop and right eye deviation with NIH stroke scale (NIHSS) 15. CT angiography demonstrated moderate to severe vasospasm of the right supraclinoid ICA, M1 MCA and A1 ACA segments. CT perfusion demonstrated large ischemic penumbra (Tmax > 6s = 204 ml) in the right cerebral hemisphere with small ischemic core (CBF < 30% = 22 ml). Urgent endovascular chemical spasmolysis via right ICA intra-arterial administration of 3mg nimodipine + 10 mg verapamil showed immediately improved caliber of involved arteries and improved flow in distal MCA branches. Vasopressor support maintaining systolic blood pressure >160 mmHg was instituted. Substantial recovery of left hemiplegia was achieved the next day. MRI 2 days after revealed infarction only in the right caudate head, posterior limb of the internal capsule and anterior hippocampus. The patient regained near complete left sided power within 2 weeks and returned to independent living with NIHSS of 0.

Systematic searches of MEDLINE and PubMed databases identified seven previously reported cases utilizing endovascular management for CVS in the setting of either bacterial (6/7) or fungal meningitis (1/7). Five cases employed chemical spasmolysis such as in this case, 1 case employed transluminal angioplasty and 1 case employed a combination of both. Six cases employed adjunct haemodynamic augmentation. Two cases employed adjunct surgical delivery of spasmolytic via ventricular drain or cisternal microcatheter. One case employed adjunct extra-cranial to intracranial bypass. This is the first case demonstrating salvage of high volume of at-risk brain on CT perfusion.

Conclusions:

CVS should always be considered in patients who develop acute neurological deficits in the setting of infective meningitis. Urgent endovascular chemical or mechanical spasmolysis is a feasible treatment. Adjunct modalities included haemodynamic augmentation, intraventricular or cisternal delivery of spasmolytic via surgical catheter, or intracranial bypass. The current literature advocates urgent consideration of such approaches once the diagnosis is made.

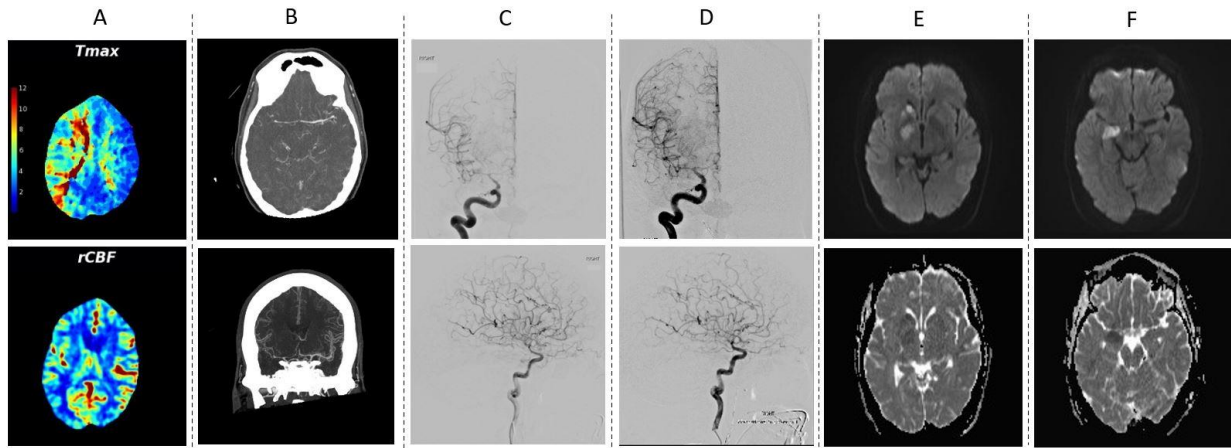


Figure 1: Initial CT perfusion (A) and CT angiogram (B), DSA pre- (C) and post-spasmolysis (D), DWI MRI day 2 post spasmolysis (E, F)

Keywords: Ischemic Stroke, Vasospasm, Angioplasty, Endovascular Therapy, Intra-Arterial Therapy

Financial Disclosures: The authors had no disclosures.

Grant Support: None.

Poster

Efficacy of Woven EndoBridge (WEB) Devices for Intracranial Aneurysms

Sameer Ansari, Mr.¹, Cynthia Zevallos, Dr.¹, Mudassir Farooqui, Dr.¹, Darko Quispe-Orozco, Dr.¹, Alan Mendez-Ruiz, Dr.¹, Andres Dajles, Dr.¹, Sudeepta Dandapat, Dr.², Santiago Ortega-Gutierrez, Dr.¹

¹University of Iowa Hospital and Clinics, Iowa City, Iowa, United States of America; ²Aurora Healthcare, Milwaukee, Wisconsin, United States of America

Introduction:

The Woven EndoBridge (WEB) has recently been approved by FDA for the treatment of saccular, wide-neck bifurcation intracranial aneurysms.^{1,2} Unlike stent-assisted coiling, the WEB device does not require dual anti-platelet therapy, which decreases risk of hemorrhagic complications. However, in aneurysms with irregular morphology, choosing the appropriate device size might be challenging as suboptimal technical and follow up outcomes may occur. The goal of this project is to better characterize the optimal device to aneurysm volume ratio to predict successful WEB device implantation.

Methods:

We performed a retrospective cohort study in patients with intracranial aneurysms who underwent treatment with a WEB device from 2/15/19 – 5/6/2020. We measured aneurysm characteristics including location, height, width, neck size and volume. Aneurysm volume was calculated with pre-treatment 3D DSA reconstruction imaging using proprietary aneurysm software (SIEMENS, Germany). We defined device-aneurysm ratio as device volume / aneurysm volume. We also collected WEB device size, number of attempts, and use of adjunct coil or stent. Successful implantation of the device was defined if the device was completely introduced into the aneurysm with no protrusion. Unsuccessful implantation was considered if the device protrudes out, if a coil or stent was used in conjunction with the WEB device, or if the operator changes the device based on inaccurate measurement/sizing of the aneurysm and WEB device. Radiographic outcome was measured by analyzing the 3-6 month follow-up DSA and stratified using the WEB-IT classification: Grade A (no contrast in aneurysm neck or sac), Grade B (no contrast in aneurysm sac some contrast in neck), and Grade C (contrast in aneurysm sac).²

Results:

We included 45 patients with a total of 47 aneurysms. Majority (78%) were females and the mean age was 64.6 years. The location of the aneurysms were: Basilar (14), Middle Cerebral (11), Internal Carotid (5), Anterior Communicating (14), Posterior Communicating (1), and Anterior Cerebral (2) arteries, respectively. The successful implantation group included 32 aneurysms (68%) while the unsuccessful group had 15 aneurysms (32%). There were no significant differences between successful and unsuccessful groups in Grade A (33% vs. 38%, p=1), Grade B (46% vs. 25%, p=0.420), or Grade C (21% vs. 38%, p=0.378), at their clinical follow-ups respectively. There were eight and seven losses at follow-up in the successful and unsuccessful groups, respectively. A total of 24 aneurysms were also analyzed for their 3D volume. There was no significant difference in the device-aneurysm ratio between the successful (median 0.65 IQR 0.56-0.83) and unsuccessful (median 0.96, IQR 0.47-1.17) implantation groups (p=0.438).

Conclusions:

We did not observe any statistical differences among the successful and unsuccessful groups. However, the successful implantation of the device was highest between 0.6-0.8 aneurysm-volume ratio.

Keywords: Aneurysm, Aneurysm Embolization, Coiling

Financial Disclosures: The authors had no disclosures.

Grant Support: None.

Poster

Endovascular repair for ruptured MCA aneurysms and its association with improved 6-month clinical outcomes

Jose Danilo B Diestro, Fellow¹, Yangmei Li, Research Personnel¹, Jose Danilo B Diestro, Fellow¹, Walter Montanera, Staff¹, Dipanka Sarma, Staff¹, Thomas Marotta, Staff¹, Julian Spears, Staff¹, Aditya Bharatha, Staff¹

¹*University of Toronto, Toronto, Canada*

Introduction:

Middle cerebral artery (MCA) aneurysms were underrepresented in the two largest trials (BRAT and ISAT) for the treatment of ruptured intracranial aneurysms. We compare clinical outcomes of patients presenting with acute subarachnoid hemorrhage from ruptured middle cerebral artery aneurysms undergoing either open or endovascular repair.

Methods:

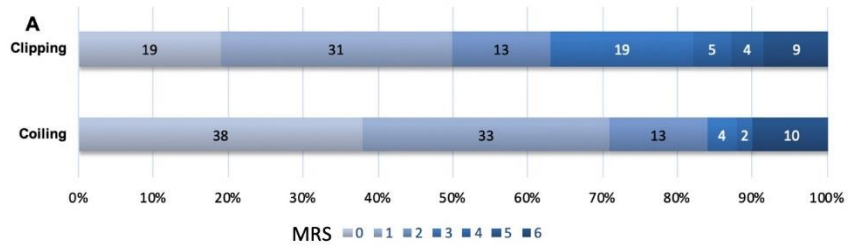
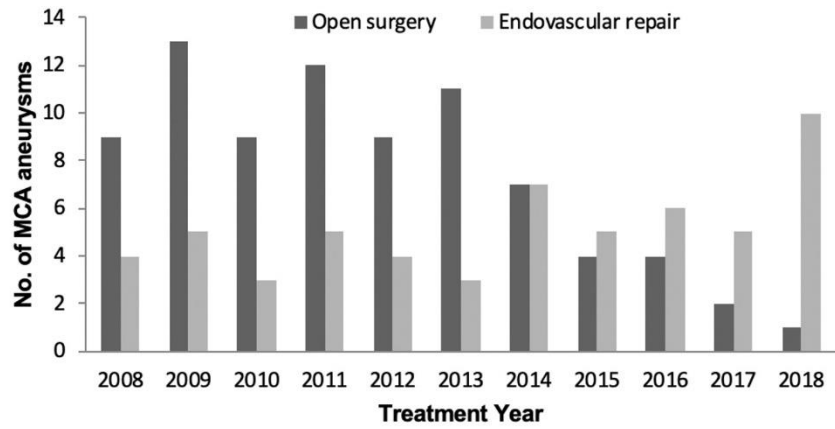
We conducted a retrospective review of 138 consecutive patients with ruptured middle cerebral artery aneurysms admitted into our institution from January 2008 to March 2019.

Results:

Of the ruptured MCA aneurysms, 57 underwent endovascular repair while 81 were treated with open surgery. At 6 months, the endovascular repair group had a higher proportion of patients with good clinical outcomes (mRS 0-2) compared to those undergoing open surgery (83.3% vs 63.2%; $p=0.011$). Four patients underwent retreatment (9.5%) for aneurysm recurrence in the endovascular group. No retreatment was documented in the surgical group. Two patients from each group (3.5% endovascular repair VS 2.4% open surgery) had rebleeding. Over the study period, there was a notable shift in practice toward more frequent endovascular treatment of ruptured MCA aneurysms (31% in 2008 vs. 91% in 2018).

Conclusions:

Our data suggest that endovascular repair is a feasible treatment strategy for acutely ruptured middle cerebral artery aneurysms. Endovascular repair was associated with improved functional outcomes at 6 months. The main limitation of this study is its retrospective design and possible selection bias. Future randomized trials for MCA aneurysms could further clarify the complementary roles of these treatment modalities.



Keywords: Coiling, Subarachnoid Hemorrhage

Financial Disclosures: The authors had no disclosures.

Grant Support: None.

Poster

Y-Configuration of Neuroform Atlas Stents for Treatment of Wide-Neck Intra-cranial Aneurysms

Ashutosh P Jadhav, MD PhD¹, Shashvat M Desai, MD¹, Ricardo A Hanel, MD PhD², Donald Frei, MD³, Ahmad Khaldi, MD⁴, Steven W Hetts, MD⁵, Osama O Zaidat, MD⁶, Brian T Jankowitz, MD⁷

¹Barrow Neurological Institute, Phoenix, Arizona, United States of America; ²Baptist Health, Jacksonville, Florida, United States of America; ³Swedish Medical Center, Englewood, Colorado, United States of America; ⁴Wellstar Medical Group, Atlanta, Georgia, United States of America; ⁵University of California San Francisco, San Francisco, California, United States of America; ⁶Mercy Health, Toledo, Ohio, United States of America; ⁷Cooper University, Camden, New Jersey, United States of America

Introduction:

Endovascular management of wide-necked bifurcation aneurysms poses a therapeutic challenge as coiling often requires the use of multiple adjunctive stent constructs to achieve successful embolization without compromising parent vessel integrity. The Neuroform Atlas Stent System is a novel low-profile, intraluminal remodeling device. The study aims to investigate the safety and efficacy of the Y-configuration constructs with the ATLAS stent for aneurysm coil embolization.

Methods:

Patients undergoing Y-stent assisted coil embolization in the ATLAS IDE trial (Investigational Device Exemption) were identified. The primary efficacy end point was complete aneurysm occlusion (Raymond-Roy class 1) on 12-month angiography, in the absence of retreatment or parent artery stenosis (>50%) at the target location. The primary safety end point was any major stroke or ipsilateral stroke or neurological death within 12 months. Adjudication of the primary end points was performed by an independent Imaging Core Laboratory and the Clinical Events Committee.

Results:

A total of 60 patients were identified. The mean age was 59 and 28.3% were men. The median aneurysm size was 6.7mm with a median neck size of 4.3 mm. Aneurysm locations were as follows: basilar apex (56.7%), basilar trunk (3.3%), anterior communicating artery (20%), anterior cerebral artery (3.3%), internal cerebral artery (3.3%) and middle cerebral artery (13.3%). The composite primary efficacy end point of complete aneurysm occlusion (Raymond-Roy 1) without parent artery stenosis or aneurysm retreatment was achieved in 81.1% of patients. Overall, 1.7% (1/60) of patients experienced a primary safety end point of major ipsilateral stroke or neurological death.

Conclusions:

In the ATLAS IDE aneurysm cohort premarket approval study, the Neuroform Atlas stent with adjunctive Y-stent coiling met the primary end points and demonstrated high rates of long-term complete aneurysm occlusion at 12 months, with low rates of morbidity.

Keywords: Aneurysm, Endovascular, Embolization

Financial Disclosures: The authors had no disclosures.

Grant Support: None.

Poster

REtrospective Multicentre INdian study of Derivo embolization device (REMIND)

Niranjan P Mahajan, Dr¹, Vikram Huded, Senior Consultant and HOD¹, Sukalyan Purkayastha, Head of Department², Nitin Dange, Additional Professor³, Mathew Cherian, Head of Radiology⁴, Vipul Gupta, Chief NVI Surgery⁵, Mudasir Shah, Dr¹

¹Narayana Institute of Neurosciences, Narayana Health City, Bengaluru, India; ²Institute of Neurosciences, Kolkata, India; ³King Edward Memorial Hospital and Seth G. S. Medical College, Mumbai, India; ⁴Kovai Medical College, Coimbatore, India; ⁵Artemis Hospital, Delhi, India

Introduction:

The treatment of aneurysms with complex morphology, wide neck, large size, fusiform and blister types have been revolutionized with the introduction of flow-diverter stents. Though these devices have major advantages over coiling, they have certain important disadvantages like lack of immediate protection against rupture, risk of ischemic stroke, need for antiplatelet therapy, and long latency for complete effect. The Derivo Embolization Device(DED) is a second-generation self-expanding device and claimed to be less thrombogenic than conventional devices.

Methods:

This is a multicentric, retrospective, observational study conducted at 5 high volume endovascular therapy centers in India from May 2018 to June 2020. Peri-procedural demographic, clinical, and angiographic data were collected from retrospective patient chart review.

Results:

A total of 96 patients aged between 16-80 years (60 ± 12.7 years) harboring 106 aneurysms were studied including 56(58.3%) women. Six(6.3%) were noted to harbor multiple aneurysms-5 had two aneurysms each while one individual was noted to have 5 aneurysms. The following aneurysm characteristics were noted- average size- 9.8 ± 8.2 mm, average neck size- 6.9 ± 8.5 mm, wide-necked (>4mm)-63(59.4%), giant(>25mm)-8(7.5%), anterior circulation location-98(92.5%). Eighteen(17%) of these were ruptured. Additional balloon angioplasty was performed in 5(5.2%) patients. Intra-procedural problems were encountered in 3(3.1%) of which only one had clinical implications- device fish-mouthing with stent thrombosis resulting in a malignant middle cerebral artery territory infarction.

Conclusions:

Flow diverters are a feasible and safe treatment option for a wide variety of aneurysms, especially the unruptured ones. DED is a promising newer generation flow diverter stent with a low peri-procedural complication rate.

Keywords: Aneurysm, Flow Diverter, Unruptured, Antiplatelet, Subarachnoid Hemorrhage

Financial Disclosures: The authors had no disclosures.

Grant Support: None.

Poster

Comparison of Surgical Clipping vs Endovascular Coiling for Posterior Projecting Anterior Communicating Artery Aneurysm

Noor ul h Maria, PGR¹, Ali Hammed, Postgrad Resident²

¹Punjab Institute of Neurosciences, LAHORE, Pakistan; ²Tishreen University Hospital, Lattakia, Syrian Arab Republic

Introduction:

Objective: To compare surgical clipping with endovascular coiling for posterior projecting anterior communicating artery aneurysm in terms of peroperative technical feasibility and possible complications such as rupture ,perioperative complications and postoperative mortality and morbidity

Posterior projecting aneurysms are technically not as straight forward as anterior projecting ones. In the literature it has been mentioned that Posteriorly projecting ACoA aneurysms are arguably the most challenging one to clip. The technical difficulties in clipping these include difficulty identifying the perforators that might jeopardize preservation of potentially important perforators. These aneurysms may be displaced laterally, causing obstacles in application of clip blades. They may be displaced posteriorly, where they may elude detection. In addition, the parent arteries of the ACoA complex are interposed between the surgeon and the aneurysm neck, making it more difficult to dissect and apply the clips to the neck In Yasargil's experience with ACoA aneurysms, the superiorly and anteriorly projecting aneurysms were the most common (34% and 23%, respectively), while posteriorly and inferiorly projecting aneurysms were the least common (14% and 13%, respectively). With the advent of endovascular procedures as an attractive options ,there is an absolute need to evaluate this procedure for the treatment of these relatively challenging aneurysms. In this study we have tried to evaluate the endovascular route as an effective alternative for intracranial aneurysms with difficult surgical access.

Methods:

Methodology: The study was conducted at Punjab Institute of Neurosciences. Total 6 cases were studied ,3 of them (n=3, 50%) were operated by surgical clipping and 3 (n=3.50%) underwent endovascular coiling. Average age was 52yrs, 90% were hypertensive, 80% were smokers. All presented through emergency with subarachnoid hemorrhage. 2 of the patients in each surgical and endovascular group presented at ER with Hunt and Hess grade 3 (n=2,33.3%) the others were at Hunt and Hess grade 2 (n=4,66.6%). The average time from hemorrhage to surgery and coiling was 25days. Outcome assessed using modified Rankin score and a score of 2 was considered satisfactory.

Results:

Result: In the surgically treated arm 2 patients had mRS of 2 while the 3 rd one had 4. In the endovascular coiling group 1 had mRS of 1, 1 had mRS 2 and 3 rd had mRS of 3. Despite the very small sample size the outcome in terms of mRS indicated slightly better results for patients undergoing coiling

Conclusions:

Endovascular coiling is better in the treatment of posteriorly projecting anterior communicating artery aneurysm.

Keywords: Aneurysm

Financial Disclosures: The authors had no disclosures.

Grant Support: None.

Poster

Scaffolding Stents Does Not Lower the Efficacy of Flow Diversion

Osman Öcal, MD¹, Ahmet Poker, MD², Ebru Öztürk, MD³, Anil Arat, MD²

¹*Department of Radiology, University Hospital, LMU Munich, Munich, Germany;* ²*Department of Radiology, Hacettepe University Hospital, Ankara, Turkey;* ³*Department of Biostatistics, Hacettepe University Hospital, Ankara, Turkey*

Introduction:

Flow diverter (FD) deployment within a stent remains controversial but FD deployment within a scaffolding stent has been occasionally performed. To date, an analysis of this scaffolding technique has not been reported. We aimed to evaluate whether the scaffolding technique adversely affects the outcomes of flow diversion.

Methods:

Patients who had undergone intracranial aneurysm treatment using a Silk FD with (scaffolded group, SG) or without (bare FD group, BG) a scaffolding stent were identified retrospectively and compared. Propensity score matching (PSM) was used to match the aneurysms in both groups for age; gender; aneurysm size, morphology and location, and previous treatments. Aneurysm occlusion rates and clinical outcomes were compared.

Results:

There were 84 patients (105 aneurysms) in BG and 21 patients (22 aneurysms) in the SG (using 20 Leo stents, 1 Enterprise stent). The aneurysms in SG were larger (13.1 ± 10.7 vs 7 ± 4.5 mm, $P=0.004$) and more likely to be fusiform (40.9% vs 5.7%, $P<0.001$) After 2:1 PSM, 26 BG and 14 SG aneurysms were matched. Aneurysm occlusion rates did not significantly differ the between groups at 1-3 months (58.6 vs 33.3%), at 3-6 months (65.0 vs 66.6%), at 7-12 months (89.5 vs 91.6%) and beyond 1 year (94.4 vs 92.8%). There was no difference in complication rates between the groups ($p=0.648$).

Conclusions:

Placement of a scaffolding stent before flow diversion does not adversely affect aneurysm occlusion or complication rates especially when braided stents are used for scaffolding.

Keywords: Flow Diverter, Intracerebral Aneurysm, Stenting

Financial Disclosures: The authors had no disclosures.

Grant Support: None.

Poster

Performance of Aneurysm Wall Enhancement Compared to Clinical Predictive Scales: PHASES, ELAPSS and UIATS

Ryan P Sabotin, BS¹, Jorge A Roa, MD², Ablerto Varon, MD¹, Ashrita Raghuram, BS¹, Timothy Morris, BS², Daizo Ishii, MD², Yongjun Lu, MD², David M Hasan, MD², Edgar A Samaniego, MD¹

¹Department of Neurology, University of Iowa Hospitals and Clinics, Iowa City, Iowa, United States of America; ²Department of Neurosurgery, University of Iowa Hospitals and Clinics, Iowa City, Iowa, United States of America

Introduction:

Contrast enhancement of unruptured intracranial aneurysms (UIAs) on high-resolution vessel wall imaging (HR-VWI) has been proposed as a biomarker of inflammation and aneurysm instability. PHASES, ELAPSS and UIATS are clinical tools to assess rupture risk, growth and treatment score of UIAs, respectively. This study correlates the presence of wall enhancement on HR-VWI with these three clinical predictive scores.

Methods:

Patients with UIAs prospectively underwent HR-VWI on a 3T Siemens MRI scanner at diagnosis. Aneurysmal wall enhancement was objectively quantified using signal intensity values adjusted for the pituitary stalk on T1 post-contrast to calculate a contrast ratio (CR_{stalk}). UIAs with CR_{stalk} ≥ 0.60 were considered 'enhancing'. Patients' demographics, comorbidities and aneurysms' morphology were reviewed to calculate PHASES, ELAPSS and UIATS scores. Pearson coefficients were applied for statistical correlation. Uni- and multivariable logistic regressions were performed to assess for confounders. Pearson coefficients were applied for statistical correlation. Uni- and multivariable logistic regressions were performed to assess for confounders.

Results:

One-hundred and twenty-three patients harboring 178 UIAs underwent HR-VWI. A total of 101 patients with 135 UIAs were analyzed. Enhancing UIAs were larger (8.4±5.5 mm vs 5.5±2.3 mm, $P<0.001$), had higher aspect ratio (2.3±1.5 vs 1.8±0.7, $P=0.008$), higher size ratio (3.0±1.8 vs 2.4±1.1, $P=0.016$), scored higher on PHASES (5.6±3.9 vs 4.4±2.6, $P=0.04$) and ELAPSS (5.6±3.9 vs 4.4±2.6, $P=0.006$) compared with non-enhancing UIAs. No significant differences were found for UIATS between enhancing and non-enhancing UIAs ($P=0.63$). Multivariable regression demonstrated that size was the only independent factor significantly associated with UIA enhancement (OR 1.76, $P=0.005$).

Conclusions:

Enhancing UIAs score higher in PHASES and ELAPSS scales. This association is largely explained by aneurysm size, suggesting that this variable is the primary determinant of contrast enhancement of UIAs. There was no association between aneurysm enhancement and UIATS.

Keywords: Intracerebral Aneurysm, Scale, Vascular Imaging, MRI

Financial Disclosures: The authors had no disclosures.

Grant Support: This work was supported by the 2019 Brain Aneurysm Research Grant from The Bee Foundation and by a Pilot Research Grant from the Society of Vascular and Interventional Neurology (SVIN), both granted to Edgar Samaniego.

Poster

Morphological Characterization of Cerebral Fusiform Aneurysms

Ryan Sabotin, BS¹, Jorge A Roa, MD², Alberto Varon, MD¹, Ashrita Raghuram, BS¹, Daizo Ishii, MD², Marco Nino, BS³, Adam Galloy, BS³, David M Hasan, MD², Egdar A Samaniego, MD¹

¹Department of Neurology, University of Iowa Hospitals and Clinics, Iowa City, Iowa, United States of America; ²Department of Neurosurgery, University of Iowa Hospitals and Clinics, Iowa City, Iowa, United States of America; ³Roy J. Carver Department of Biomedical Engineering, University of Iowa, Iowa City, Iowa, United States of America

Introduction:

While fusiform aneurysms account for a small percent of UIAs, they are more prone to rupture and become symptomatic more often than saccular aneurysms. The etiology of fusiform aneurysms is not yet completely understood, but possible causes such as dissection, atherosclerosis, and collagen disease represent an underlying pathophysiology that differs from the more prominent saccular aneurysms. Additionally, current treatment options are limited and pose substantial risks. Therefore, there is a need to better characterize these vascular lesions. High-resolution vessel wall imaging (HR-VWI) has emerged as an effective tool in determining the angio-architecture of brain aneurysms and characteristics of the vessel walls. The aim of this study is to use advanced imaging and computational techniques to characterize cerebral fusiform aneurysms and better understand their unique pathophysiology.

Methods:

Patients with UIAs were prospectively imaged from March 2018 to June 2020, undergoing 3T and 7T HR-VWI protocols with intravenous injection of 0.1mmol/kg gadolinium-based contrast agent. Fusiform aneurysms were defined as vessel wall dilation outside of major bifurcations with no discernable aneurysm neck. Aneurysmal wall enhancement was objectively quantified using signal intensity values adjusted for the pituitary stalk on T1 post-contrast. This was used to create a contrast ratio (CR) with a threshold of ≥ 0.60 to determine "enhancement". Additionally, another vessel within the circle of Willis (reference vessel) was analyzed for each patient with a fusiform aneurysm. Several morphological features of each aneurysm were analyzed through segmentation: volume, height, width, and aneurysm boundaries. The presence of microbleed within the aneurysm wall was analyzed with quantitative susceptibility mapping imaging sequences. Computational fluid dynamics and finite element analysis of three patients with fusiform aneurysms was performed in collaboration with the department of biomedical engineering. Morphological parameters were analyzed with two-tailed Student's t tests and Pearson chi-squared tests.

Results:

A total of 130 patients with 160 aneurysms underwent HR-VWI. 136 aneurysms had a saccular morphology and 24 were fusiform. Fusiform aneurysms had a significantly higher CR and diameter when compared to saccular aneurysms, with a multivariable logistic regression demonstrating that diameter was the only independent factor associated with UIA enhancement. Enhancing fusiform aneurysms had significantly larger volumes, diameters, and higher enhancement in a reference vessel compared to non-enhancing fusiform aneurysms. Additionally, fusiform aneurysms with microbleeds had a significantly

higher CR, volume, diameter, and proportion of aneurysms that enhanced when compared to fusiform aneurysms negative for microbleed.

Conclusions:

This study demonstrates significant differences between fusiform and saccular aneurysms, while highlighting morphological characteristics that are unique to fusiform aneurysms. Fusiform aneurysms showed higher rates of enhancement on HR-VWI compared to saccular aneurysms. Similarly, fusiform aneurysms that enhanced had larger diameter and volume measurements compared to non-enhancing fusiform aneurysms. This suggests that aneurysm size is the primary determinant of contrast enhancement in both saccular and fusiform UIAs. However, reference vessels in patients with enhancing fusiform aneurysms displayed a higher degree of enhancement than those with non-enhancing fusiform aneurysms, suggesting a more prominent underlying cerebral vasculopathy in patients with enhancing fusiform aneurysms.

Keywords: Intracerebral Aneurysm, MRI, Pathophysiology, Vascular Imaging

Financial Disclosures: The authors had no disclosures.

Grant Support: This work was supported by the 2019 Brain Aneurysm Research Grant from The Bee Foundation and by a Pilot Research Grant from the Society of Vascular and Interventional Neurology (SVIN), both granted to Edgar Samaniego.

Poster

Safety and Performance of the Penumbra SMART COIL System for Patients with Very Small Aneurysms

Alejandro M Spiotta, MD¹, Richard J Bellon, MD², Bradley Bohnstedt, MD FAANS³, Min S Park, MD⁴, Keith B Woodward, MD⁵

¹Medical University of South Carolina, Charleston, South Carolina, United States of America; ²Swedish Medical Center, Denver, Colorado, United States of America; ³Indiana University Health Physicians (UOHSC), Indianapolis, Indiana, United States of America; ⁴University of Virginia, Charlottesville, Virginia, United States of America; ⁵Fort Sanders Regional Medical Center, Knoxville, Tennessee, United States of America

Introduction:

The Penumbra SMART COIL System includes a novel generation of embolic coils comprised of complex and WAVE shape properties with varying levels of softness to promote dense packing and durable long-term occlusion. We report a subset analysis to assess the safety and performance of the SMART COIL System through one year of follow-up in patients with very small (<4mm) aneurysms enrolled in the SMART registry.

Methods:

The SMART registry is a prospective, multi-center registry study of subjects treated with SMART COIL, Penumbra COIL 400, or Penumbra Occlusion Device as per the indications. SMART registry endpoints include retreatment rates through one year follow-up, procedural device-related serious adverse events (SAE), and the ability to achieve adequate occlusion at immediate post-procedure.

Results:

Of the 905 enrolled patients with aneurysms, 19.0% (172/905) had very small aneurysms (75.6% female; mean age 57.2 ± 13.4 years). Of those with very small aneurysms, 30.8% (53/172) were ruptured of which 50.9% (27/53) had Hunt and Hess grading scale of >3. Total of 79.5% (132/166) were wide-neck (dome-to-neck ratio < 2 or neck width ≥ 4 mm). Stent-assisted coiling and balloon-assisted coiling were performed during treatment in 37.2% (64/172) and 22.1% (38/172) of patients, respectively. Median packing density for very small aneurysms was 41.5 (IQR29.4, 53.0).

In patients with very small aneurysms, Raymond Class I and II was achieved in 89.5% (154/172) at immediate post-procedure and 97.2% (137/141) at one year follow-up. The recanalization rate at one year was 7.1% (10/141). The retreatment rate through one year was 5.6% (8/142). The device-related SAE were observed in 2.9% subjects (5/172). Within 24-hours, cerebral aneurysm perforation was reported in 0.8% (1 case) and intra-operative aneurysm rupture in 0.8% (1 case). The Modified Ranking Scale between 0 to 2 was observed in 86.6% (84/97) at one year follow-up.

Conclusions:

This subset analysis suggests that the SMART COIL System achieves adequate embolization in very small aneurysms (<4mm) with low retreatment rates over one year.

Keywords: Coiling, Clinical Trial, Aneurysm Embolization, Endovascular, Intracerebral Aneurysm

Financial Disclosures: Consulting: Stryker, Penumbra, Terumo Research support: Stryker, Penumbra, Medtronic

Grant Support: None.

Poster

study of pathology, current imaging assessment and treatment strategies in intracranial serpentine aneurysms

Saima Ahmad, Neuroradiologist¹

¹*Lahore General Hospital, Lahore, Pakistan*

Introduction:

Segal and McLaurin (1977) first described giant serpentine aneurysms, based on their distinct angiographic features. These lesions are large, partially thrombosed aneurysms with a patent, serpiginous vascular channel that courses through the aneurysm. There is a separate inflow and outflow of the aneurysm, of which the outflow channel supplies brain parenchyma in the territory of the parent vessel. Given the large size, unique neck, and dependent distal vessels, these aneurysms pose a technical challenge in treatment.

Methods:

Ten patients with giant serpentine aneurysms were studied retrospectively at our institution in the last 5 years. They all underwent CT and MR studies as well as cerebral angiography. Seven patients had endovascular occlusion of the giant serpentine aneurysms, four with detachable coils, and one with detachable balloons, and two with flow diverters. In two patients, bypass surgery was done. One patient was at follow up without any definitive treatment.

Results:

Serpentine aneurysms mimic cerebral neoplasms on CT and MR studies; they are often associated with mass effect and adjacent edema, and they enhance with contrast medium. The cerebral angiogram shows a residual irregular lumen of the partially clotted aneurysm, which continues into normal branches supplying the distal arterial territory. Four patients were treated successfully with an endovascular approach consisting of complete and permanent occlusion of the parent artery. One patient died of complications post-treatment. In one patient coiling of aneurysm resulted in major MCA infarct. In another patient due to the displacement of the flow diverter, another flow diverter had to be deployed.

Conclusions:

A balloon occlusion test or cross compression test is recommended for this evaluation. If the collateral circulation is sufficiently compensatory, direct excision or embolization can be performed. However, if the compensatory collateral circulation is poor, a bypass surgery is necessary. Satisfactory results can be achieved in the majority of SA patients after treatment. However, the size of the aneurysm may increase in some patients after endovascular treatment. Special attention should be paid to cases exhibiting a significant mass effect to avoid subsequent SA excision due to an intolerable mass effect. As techniques and technology have evolved, a combination of surgical bypass grafting and endovascular occlusion has demonstrated promising results with lower morbidity and mortality.

Age/G	Aneurysm Location	Presenting Symptoms & Signs	Imaging Characteristics	Treatment
45y/f	R-ICA	R eye blindness, CN palsies, recurrent TIAs	DSA- R-ICA serpentine aneurysm, L-ICA total occlusion, low flow distally, MRI - edema & thrombosis	High flow bypass
26y/f	B/L ICA, R-PCA	L sided hemiparesis, drowsy, GCS 11	L- ICA serpentine anm whole segment, R-ICA, PCA thrombosed anm with total occlusion of vessels	High flow bypass
14y/m	L-MCA	Presented with right sided hemiparesis	DSA-L-MCA serpentine anm with slow flow in distal MCA branches	Coiling
15y/f	L-ICA	Left sided hemiparesis, headache, fits	DSA-L-ICA large serpentine aneurysm with another blind pouch at distal location, total occlusion beyond L ophthalmic artery	Coiling
48y/m	R-VB	Ictus, recurrent diplopia, headache, basal nerve palsies	DSA-R-VB serpentine anm with distal decrease flow, L VA was atretic, MRI -Perifocal edema, Partial thrombosis	Occlusion of right BA after BTO
18y/f	R-MCA	Ictus, L sided hemiparesis, grade 3 UL/ LL	DSA-R-MCA serpentine vascular channel with distal aneurysms sac	BTO/ coiling
25y/f	L-VB	Vomiting, diplopia, blackouts, left sided hearing loss, headache	DSA-L VB serpentine aneurysm possibly arising from fusiform aneurysm, MRI -Partial thrombosed anm	VP Shunt & flow diverter
65y/m	L-ICA	Headache, left eye blindness & ptosis	DSA-L-ICA serpentine anm involving cavernous and cerebral segment filling from contra lateral ICA	Endovascular / Flow diverter
32y/m	L-ICA	Headache, retro orbital pain in the left eye	DSA- L-ICA serpentine large anm, MRI shows partially thrombosed large ICA anm with edema	Partial coiling (protective)
10y/m	L-VB	Headache and neck pain	DSA- L -VA shows serpentine vertebra basilar aneurysm	Flow diverter

Keywords: Aneurysm, Balloon Assisted, Aneurysm Embolization, Cerebral Blood Flow, Basilar

Financial Disclosures: The authors had no disclosures.

Grant Support: None.

Poster

A Study on Safety and Efficacy in Consecutive Group of 46 Patient and 52 aneurysm

MARCELO BOLCATO, DOCTOR¹, LUIS AGUIAR, DOCTOR¹, LEO DITZ, DOCTORS¹, ANA CAROLINA DALMONICO, DOCTORS¹, SAVIO MACARECH, DOCTORS¹

¹HOSPITAL SANTA CRUZ, CURITIBA, Brazil

Introduction:

Endovascular flow diverters are increasingly used for the treatment of cerebral aneurysms. We assessed the safety and efficacy of the Flow Diverters in a consecutive series of 46 patients and 52 aneurysms

Methods:

Inclusion criteria were wide-neck, blister-like, or fusiform aneurysms independent of size, treated with the FRED, PIPELINE and SILK between December 2014 and December 2019. Assessment criteria were aneurysm occlusion, manifest ischemic stroke, bleeding, or death. The occlusion rate was assessed at 6 months and 1 year with DSA by using the Raymond classification and the O'Kelly-Marotta grading scale.

Results:

Forty six patients with 51 aneurysms were treated with 9 Silk, 30 FREDs and 13 Pipeline. Aneurysm size ranged from 3.0 to 30 mm. Deployment of the Flow diverters was successful in 45 cases. Three patient developed mild stroke symptoms that fully receded within days, 3 patients occlusion total carotid because resistant antiaggregation and another patient's development Swelling syndrome. There has been one death. Initial follow-up at 6

Conclusions:

The flow diverter is a safe device for the treatment of cerebral aneurysms of various types. Our data reveal high occlusion rates at 6 months and 1 year. Long-term occlusion rates are expected.

Keywords: Aneurysm Embolization, Flow Diverter, Cerebral

Financial Disclosures: The authors had no disclosures.

Grant Support: None

Poster

Successful Treatment of Ruptured Mycotic Aneurysm with Endovascular Intervention and Intraventricular tPA

Bhavya Narapureddy, MBBS¹, Neil Suryadevara, MD¹, Grahame C Gould, MD¹ ¹*SUNY Upstate Medical University, Syracuse, New York, United States of America*

Introduction:

Introduction: Intracranial mycotic aneurysms are a rare complication of infective endocarditis. Ruptured aneurysms have been associated with a mortality rate as high as 80%¹ and can be challenging to treat. Current available options to treat ruptured mycotic aneurysm include surgical and endovascular interventions.

Methods:

We present a case of a ruptured intracranial mycotic aneurysm that has been successfully treated with endovascular intervention and intraventricular tPA.

Results:

This is a case of a 23-year-old male diagnosed with culture negative infective endocarditis who underwent mitral and aortic valve replacement and was on active antibiotic treatment. About three weeks later, he had sudden deterioration in his mental status with GCS of 4 on presentation. CT head showed intra-parenchymal hemorrhage with extensive bilateral interventricular extension and obstructive hydrocephalus. Due to recent cardiac surgery, patient was on warfarin which was immediately reversed. CTA head and neck demonstrated a saccular aneurysm measuring 0.9cm by 0.7cm in the right P2/P3 segment of right PCA. He underwent bilateral EVD placement followed by complete occlusion of right P3 with Onyx and coil embolization within 24 hours of presentation. Due to extensive intraventricular hemorrhage, failure of EVD gravity drain and an accelerated need for restarting systemic anticoagulation, treatment with intraventricular tPA was pursued. Per standard protocol, 6 doses of tPA were administered in the left EVD every 8 hours. A repeat CTH 48 hours later showed good clearance of hemorrhage from the third and fourth ventricles along with improved hydrocephalus. By day 12, he met clinical and radiographic criteria for EVD removal. Patient was then restarted on anticoagulation with a successful bridging of heparin to warfarin. On day 20, he was discharged to rehabilitation and a follow up five months later revealed almost complete recovery except visual deficits.

Conclusions:

Conclusion: Urgent angiographic evaluation and coiling of aneurysm can be life-saving in patients with ruptured mycotic aneurysm and is also favorable over surgical approach as it allows early initiation of anticoagulation.^{1,2} Although the use of intraventricular tPA is not advisable in patients with aneurysmal intraventricular hemorrhage, literature shows evidence of its safety after securing the aneurysm, which is further reinforced by our experience in this case.³

Keywords: Intracerebral Aneurysm, TPA, Ruptured, Aneurysm Embolization, Coiling

Financial Disclosures: The authors had no disclosures.

Grant Support: None.

Poster

Potential Perioperative Complications Due To Differences in Timing Of Systemic Heparinization During Ruptured Aneurysm Coiling

Rouzbeh Kotaki, Mr.¹, Ameer Hassan, DO², Wondwossen Tekle, MD³

¹University of Texas Rio Grande Valley- School of Medicine, McAllen, Texas, United States of America;

²Valley Baptist Medical Center, Harlingen, Texas, United States of America; ³Valley Baptist Medical Center, McAllen, United States of America

Introduction:

Systematic heparin anticoagulation is standard in regards to neurovascular intervention. When coiling ruptured aneurysms, many neurointerventionalists have their own protocol for systemic heparinization. Ample literature exists reviewing the frequency of perioperative events, predictors and outcomes, as well as the efficacy in the use of anticoagulants and/or antiplatelets before, during, and after neurovascular procedures to prevent adverse outcomes. However, there currently exists a dearth of research in regarding timing of distribution of heparin intraoperatively and its potential effects on adverse patient outcomes. We performed this analysis to evaluate the effect on the frequency of perioperative complications in relation to when intraoperative systemic heparin is given, particularly if earlier administration increases bleeding diathesis and if later administration increases ischemic events.

Methods:

We used a single hospital retrospective study of patients with a primary diagnosis of subarachnoid hemorrhage due to ruptured aneurysm to assess the differences in timing of intraoperative systemic heparin distribution during coiling. Patients were subdivided into those who received heparin at the start of the procedure and those that received heparin after deployment of first coil. Outcomes of interest were perioperative re-rupture of aneurysm and stroke. Other factors analyzed were age, sex, Hun/Hess Scale, modified Fisher Scale, and aneurysm size. Continuous variables were expressed as the mean with standard error (\pm SE). Categorical variables are expressed as percentages. Comparisons between groups were performed using ANOVA for continuous variables and the Chi-squared test or the Fisher's exact test for categorical parameters. $P < 0.05$ was considered statistically significant.

Results:

We analyzed 246 patients with ruptured aneurysms undergoing endovascular coiling (mean age 57.70 ± 1.00). Perioperative complications were seen in a total of 17 patients (6.91%). In univariate analysis, patients who received systemic heparin at procedure onset vs. those who received it after placement of first coil did not have worse outcomes both in re-rupture of aneurysm (1.08% vs. 6.54%, $p = 0.056$) or perioperative stroke (2.15% vs. 2.61%, $p = 1$). In our analysis, timing of systemic heparin did not seem to influence the rate of these intraoperative complications.

Conclusions:

Timing of systemic heparin distribution and its potential effects on perioperative events remains an understudied area of interventional neurology. However, our data suggests that the different timepoints that are currently regarded as standard for its distribution have little bearing on adverse patient

outcomes intraoperatively. This can lead us to rethink time guidelines for patients and decrease the apprehension in heparin distribution with regards to adverse outcomes.

Table 1	35 U/kg At Start n= 93	35 U/kg After First Coil n= 153	All Patients n= 246	P-Value
Age (mean ± SE)				
	57.30 ± 1.70	57.95 ± 1.23	57.70 ± 1.00	0.95
Sex				
Male (%)	28 (30.11)	39 (25.49)	67 (27.24)	0.46
Female (%)	65 (69.89)	114 (74.51)	179 (72.76)	
Hunt and Hess				
1 (%)	29 (31.18)	19 (12.42)	48 (19.51)	0.74
2 (%)	15 (16.13)	70 (45.75)	85 (34.55)	
3 (%)	25 (26.88)	34 (22.22)	59 (23.98)	
4 (%)	22 (23.66)	22 (14.38)	44 (17.89)	
5 (%)	2 (2.15)	8 (5.23)	10 (4.07)	
Modified Fisher Grade				
1 (%)	1 (1.08)	8 (5.23)	9 (3.66)	0.0006
2 (%)	7 (7.53)	5 (3.27)	12 (4.88)	
3 (%)	37 (39.78)	103 (67.32)	140 (56.91)	
4 (%)	48 (51.61)	37 (24.18)	85 (34.55)	
Aneurysm Size (mean ± SEM)				
Length (mm)	6.17 ± 0.38	6.18 ± 0.25	6.18 ± 0.21	1
Width (mm)	4.78 ± 0.33	4.66 ± 0.20	4.70 ± 0.17	0.94
Perioperative Complications (%)				
Rerupture (%)	1 (1.08)	10 (6.54)	11 (4.47)	0.056
Stroke (%)	2 (2.15)	4 (2.61)	6 (2.44)	1

Keywords: Aneurysm Embolization, Coagulation, Coiling, Interventional Neuroradiology, Medical Management

Financial Disclosures: The authors had no disclosures.

Grant Support: None.

Poster

Differences in Characteristics of Octogenarian Patients Undergoing Carotid-Revascularization: Insights from a Real-World Surgical Quality-Registry

Mohammed Ali Alvi, MBBS, MS¹, Yagiz Yolcu, MD¹, Jacob Kosarchuk, MD², Kenan Rajjoub, MD³, Ozan Dikilitas, MD¹, Luis E Savastano, MD, Ph.D¹, Giuseppe Lanzino, MD¹, Sarosh I Madhani, MD¹

¹Mayo Clinic Rochester, Rochester, Minnesota, United States of America; ²Tufts Medical Center, Boston, Massachusetts, United States of America; ³Buffalo General Medical Center, Buffalo, New York, United States of America

Introduction:

Several clinical trials evaluating the efficacy of a carotid revascularization procedure excluded patients above age 80. In the current study, we sought to assess the differences in characteristics of octogenarians undergoing carotid endarterectomy (CEA) and carotid artery stenting (CAS) for carotid stenosis using “real-world” data from a national surgical quality registry.

Methods:

The National Surgical Quality Improvement Program (NSQIP) targeted datasets for carotid endarterectomy (CEA) and carotid artery stenting (CAS) were queried for patients aged ≥ 80 years between 2012-2018.

Results:

We identified 5,814 patients undergoing CEA and 189 patients undergoing CAS who were 80 or older. Patients in the CAS group were more likely to be ≥ 90 years ($p=0.004$), more likely to be diabetic ($p=0.04$), more likely to have a history of CHF ($p=0.012$) and a bleeding disorder ($p<0.001$). Patients in the CAS group were also more likely to have high risk anatomy ($p<0.001$), high risk physiology ($p=0.028$). Ninety-nine (52.4%) patients in the CAS group and 2,775 (47.7%) in the CEA group were found to be symptomatic at the time of surgery, with most patients in both groups presenting with an ipsilateral stroke. Among asymptomatic patients, 64 (74%) in the CAS group and 2222 (72.7%) in the CEA group were found to have severe stenosis ($>80\%$) of the ipsilateral carotid, while 13 (14.5%) in the CAS group and 302 (11%) in the CEA group were found to have severe stenosis or complete occlusion of the contralateral carotid. Among symptomatic patients, 58 (61.7%) in the CAS group and 1527 (57.5%) in the CEA group were found to have severe stenosis/complete occlusion of the ipsilateral carotid, while 12(12.8%) in the CAS group and 208(7.8%) in the CEA group were found to have severe stenosis or occlusion of the contralateral carotid.

Conclusions:

These analyses from real-world data show that there may be some differences in demographic and comorbid characteristics between octogenarians undergoing CAS and CEA.

Table 1: Demographic and Comorbid Characteristics of the Cohort by Procedure Type

	Carotid Artery Stenting (N=189)	Carotid Endarterectomy (N=5814)	Total (N=6003)	p value
Age Groups				0.004
80-84	123 (65.1%)	3831 (65.9%)	3954 (65.9%)	
85-89	44 (23.3%)	1636 (28.1%)	1680 (28.0%)	
90 And Above	22 (11.6%)	347 (6.0%)	369 (6.1%)	
Sex				0.086
Female	66 (34.9%)	2393 (41.2%)	2459 (41.0%)	
Male	123 (65.1%)	3421 (58.8%)	3544 (59.0%)	
BMI	27.105 (5.141)	26.994 (4.863)	26.998 (4.872)	0.759
Race				0.057
American Indian Or Alaska Native	0 (0.0%)	12 (0.2%)	12 (0.2%)	
Asian	5 (2.6%)	94 (1.6%)	99 (1.6%)	
Black Or African American	11 (5.8%)	197 (3.4%)	208 (3.5%)	
Native Hawaiian Or Pacific Islander	0 (0.0%)	4 (0.1%)	4 (0.1%)	
Unknown	0 (0.0%)	11 (0.2%)	11 (0.2%)	
Unknown/Not Reported	6 (3.2%)	518 (8.9%)	524 (8.7%)	
White	167 (88.4%)	4978 (85.6%)	5145 (85.7%)	
Diabetes				0.044
Insulin	24 (12.7%)	450 (7.7%)	474 (7.9%)	
Non-Insulin	32 (16.9%)	994 (17.1%)	1026 (17.1%)	
Smoker	14 (7.4%)	401 (6.9%)	415 (6.9%)	0.786
Dyspnea				0.090
At Rest	3 (1.6%)	31 (0.5%)	34 (0.6%)	
Moderate Exertion	27 (14.3%)	685 (11.8%)	712 (11.9%)	

Functional Status				0.409
Independent	176 (93.1%)	5548 (95.4%)	5724 (95.4%)	
Partially Dependent	12 (6.3%)	245 (4.2%)	257 (4.3%)	
Totally Dependent	1 (0.5%)	14 (0.2%)	15 (0.2%)	
Unknown	0 (0.0%)	7 (0.1%)	7 (0.1%)	
On Ventilator	0 (0.0%)	1 (0.0%)	1 (0.0%)	0.857
History of COPD	23 (12.2%)	517 (8.9%)	540 (9.0%)	0.121
History of CHF	8 (4.2%)	102 (1.8%)	110 (1.8%)	0.012
Hypertension	157 (83.1%)	4989 (85.8%)	5146 (85.7%)	0.289
Renal Failure	0 (0.0%)	16 (0.3%)	16 (0.3%)	0.470
Dialysis	3 (1.6%)	50 (0.9%)	53 (0.9%)	0.293
History of Hemiplegia	0 (0.0%)	1 (2.6%)	1 (2.4%)	0.819
History of CVA	0 (0.0%)	1 (2.6%)	1 (2.4%)	0.819
Disseminated Cancer	2 (1.1%)	20 (0.3%)	22 (0.4%)	0.110
History of Steroid Use	6 (3.2%)	171 (2.9%)	177 (2.9%)	0.852
Weight Loss	2 (1.1%)	27 (0.5%)	29 (0.5%)	0.247
Bleeding Disorder	73 (51.0%)	1154 (22.4%)	1227 (23.2%)	< 0.001

Keywords: Carotid Stenting And Angioplasty, CEA, Carotid,

Financial Disclosures: The authors had no disclosures.

Grant Support: None.

Poster

Nationwide Trends in Intracranial Angioplasty and Stenting in the United States, 2010-2017

Aayushi Garg, MD¹, Aayushi Garg, MD¹, Darko Quispe Orozco, MD¹, Mudassir Farooqui, MPH¹, Cynthia Zevallos, MD¹, Alan Mendez Ruiz, MD¹, Santiago Ortega, MD¹

¹*University of Iowa Hospitals and Clinics, Iowa City, United States of America*

Introduction:

Intracranial atherosclerosis is a common cause of stroke, the management for which includes the best medical therapy (BMT) and/or intracranial angioplasty and stenting (ICAS). It is unknown how the nationwide practices for the utilization of ICAS have changed following The Stenting and Aggressive Medical Management for Preventing Recurrent Stroke in Intracranial Stenosis (SAMMPRIS) trial in 2011, which showed a higher rate of stroke or death in patients treated with BMT and ICAS, relative to BMT alone. We aimed to evaluate the nationwide trends in ICAS while accounting for the influence of patient-level and hospital-level characteristics.

Methods:

We utilized the Nationwide Readmissions Database 2010-2017 to identify the hospitalizations for ICAS. The unit of analysis was a hospitalization. Survey design methods were used to generate national-level estimates. We reported the rates of ICAS per 100,000 hospitalizations for ischemic stroke or transient ischemic attack (TIA) in each year. The Cochran-Armitage test was used to estimate the P values for linear trend across the years. Poisson regression was used to estimate the risk ratios (RR) and 95% confidence intervals (CI) comparing the change in the rate of ICAS before (2010-2011) and after (2012-2017) the SAMMPRIS trial, stratified by different covariates.

Results:

There were 17,791 hospitalizations for ICAS during the study period. The overall rate of ICAS decreased from 2,610 (332 per 100,000 hospitalizations for stroke/TIA) in 2010 to 2,070 (246 per 100,000 hospitalizations for stroke/TIA) in 2017 ($P < 0.001$ for trend) (Figure 1a). Among the hospitalizations with ICAS, the in-hospital mortality rates did not change during the study period ($P = 0.105$ for trend). After the SAMMPRIS trial (in 2011), statistically significant reductions in ICAS were seen overall (RR 0.83, 95% CI 0.79-0.87, $P < 0.001$) and among all sexes, age groups, insurance type, and hospital types (Figure 1b). There was no decline in the rate of ICAS among the non-elective hospitalizations between the two time periods.

Conclusions:

These data confirm a modest decline in the yearly trends of ICAS in the United States after ICAS was shown to be inferior to the BMT in the SAMMPRIS trial.

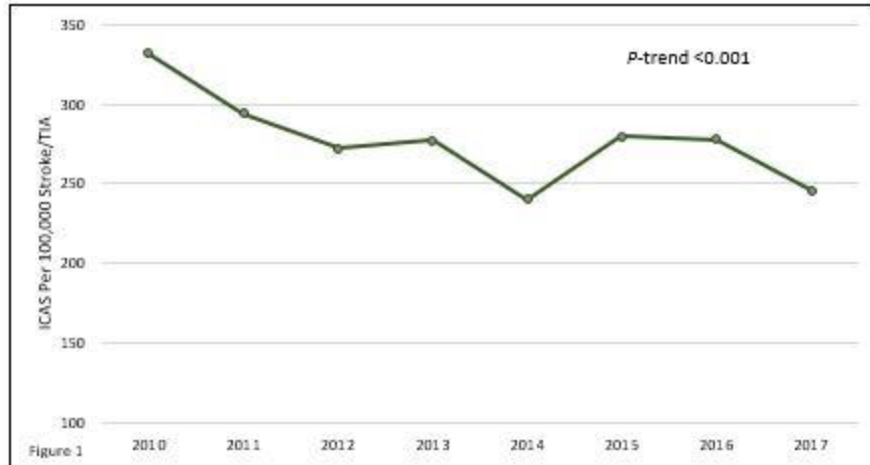


Figure 2. Change in Intracranial Angioplasty and Stenting Before (2010-2011) and After (2012-2017) SAMMPRIS Trial Stratified by Patient and Hospital-Level Characteristics

Characteristic	2010-2011 (N=313)	2012-2017 (N=265)	RR (95% CI)	P-value
Sex				
Male	282	260	0.87 (0.81 – 0.94)	<0.001
Female	338	270	0.80 (0.75 – 0.86)	<0.001
Age, years				
<65	575	487	0.84 (0.79 – 0.90)	<0.001
>65	178	150	0.81 (0.74 – 0.87)	<0.001
Primary Payer				
Medicare	191	158	0.78 (0.72 – 0.84)	<0.001
Other	571	494	0.88 (0.82 – 0.94)	<0.001
Admission type				
Elective	1,942	1,470	0.75 (0.61 – 0.93)	0.009
Non-elective	202	203	1.00 (0.84 – 1.20)	0.973
Teaching Status				
Non-teaching	97	81	0.82 (0.72 – 0.94)	0.003
Teaching	583	388	0.62 (0.59 – 0.65)	<0.001

All numbers are reported per 100,000 hospitalizations for stroke/TIA

Keywords: Intracranial Stenosis Stenting And Angioplasty

Financial Disclosures: The authors had no disclosures.

Grant Support: None.

Poster

30-Day Stroke & Mortality after Carotid Revascularization Among Octogenarians with Symptomatic Carotid-Stenosis: A Real-World Analysis

Mohammed Ali Alvi, MBBS, MS¹, Yagiz Yolcu, MD¹, Jacob Kosarchuk, MD², Kenan Rajjoub, MD³, Ozan Dikilitas, MD¹, Sarosh I Madhani, MD¹, Luis E Savastano, MD, Ph.D¹, Giuseppe Lanzino, MD¹

¹Mayo Clinic Rochester, Rochester, Minnesota, United States of America; ²Tufts Medical Center, Boston, Massachusetts, United States of America; ³Buffalo Regional Medical Center, Buffalo, New York, United States of America

Introduction:

Due to their exclusion from most clinical trials, outcomes of carotid revascularization via a carotid endarterectomy (CEA) or carotid artery stenting (CAS) among octogenarians are not well studied. Herein, we present analysis of thirty-day stroke and mortality of patients aged ≥ 80 using real-world data from a national surgical quality registry.

Methods:

The National Surgical Quality Improvement Program (NSQIP) targeted dataset for CEA and CAS was queried for patients aged ≥ 80 undergoing CEA and CAS between 2012-2018

Results:

A total of 94 and 2,656 patients aged ≥ 80 with symptomatic carotid stenosis undergoing CAS and CEA (respectively) were identified. Patients in the CAS group were more likely to be over 90 ($p=0.006$), more likely to have high-risk anatomy ($p<0.001$) and to be on aspirin preoperatively ($p=0.02$) but less likely to have higher american society of anaesthesiology (ASA) score ($p<0.001$). 43.6% of patients in the CAS group and 41.7% in the CEA cohort had suffered an ipsilateral stroke. The rate of thirty-day composite outcome (stroke or death) was 5.3% in the CAS group and 4.5% in the CEA group ($p=0.714$) (stroke: 2.1% for CAS and 3.2% for CEA; death: 4.3% for CAS and 1.7% for CEA). Upon multivariable analysis, procedure type (CAS vs CEA) was not associated with the composite-outcome (OR 1.1, 95%CI 0.43-2.82, $p=0.836$). Symptom presentation other than ipsilateral stroke was associated with significantly decreased odds of 30-day composite outcome (amaurosis-fugax/transient monocular blindness: OR 0.42, 95%CI 0.21-0.86, $p=0.02$; TIA: OR 0.62, 95%CI 0.42-0.93, $p=0.02$), while higher age was found to be associated with significantly increased odds (OR 1.512, 95%CI 1.01-2.24, $p=0.02$).

Conclusions:

Real world analyses from a surgical quality registry show that both CAS and CEA are associated with equivalent 30-day outcomes among octogenarians with symptomatic carotid stenosis.

Table 1: Demographic and Comorbid Characteristics of the Cohort by Procedure Type

	Carotid Artery Stenting (N=94)	Carotid Endarterectomy (N=2656)	Total (N=2750)	p value
Age				0.006

80-84	52 (55.3%)	1617 (60.9%)	1669 (60.7%)	
85-89	26 (27.7%)	830 (31.2%)	856 (31.1%)	
90+	16 (17.0%)	209 (7.9%)	225 (8.2%)	
Sex				0.665
Female	35 (37.2%)	1048 (39.5%)	1083 (39.4%)	
Male	59 (62.8%)	1608 (60.5%)	1667 (60.6%)	
BMI	27.074 (4.950)	26.888 (4.825)	26.894 (4.829)	0.715
Race				0.128
American Indian or Alaska Native	0 (0.0%)	7 (0.3%)	7 (0.3%)	
Asian	3 (3.2%)	57 (2.1%)	60 (2.2%)	
Black or African American	5 (5.3%)	87 (3.3%)	92 (3.3%)	
Native Hawaiian or Pacific Islander	0 (0.0%)	1 (0.0%)	1 (0.0%)	
White	83 (88.3%)	2144 (80.7%)	2227 (81.0%)	
Unknown	0 (0.0%)	6 (0.2%)	6 (0.2%)	
Unknown/Not Reported	3 (3.2%)	354 (13.3%)	357 (13.0%)	
Diabetes				0.113
No	66 (70.2%)	2002 (75.4%)	2068 (75.2%)	
Insulin	13 (13.8%)	209 (7.9%)	222 (8.1%)	
Non-Insulin	15 (16.0%)	445 (16.8%)	460 (16.7%)	
Smoker	7 (7.4%)	182 (6.9%)	189 (6.9%)	0.823
History of CHF	3 (3.2%)	52 (2.0%)	55 (2.0%)	0.401
Hypertension	74 (78.7%)	2237 (84.2%)	2311 (84.0%)	0.152

Table 2: Presenting Symptoms and Clinical Characteristics of the Cohort by Procedure Type

	Carotid Artery Stenting (N=94)	Carotid Endarterectomy (N=2656)	Total (N=2750)	P value
Symptom Presentation				0.451
Amaurosis fugax or Transient Monocular Blindness, ipsilateral	13 (13.8%)	359 (13.5%)	372 (13.5%)	
Stroke, ipsilateral	41 (43.6%)	1190 (44.8%)	1231 (44.8%)	

Transient ischemic attack, ipsilateral	40 (42.6%)	1107 (41.7%)	1147 (41.7%)	
High Risk Anatomy	27 (28.7%)	277 (10.4%)	304 (11.1%)	< 0.001
High Risk Physiology	14 (14.9%)	268 (10.1%)	282 (10.3%)	0.165
Pre-Op Aspirin	92 (97.9%)	2357 (88.7%)	2449 (89.1%)	0.020
Pre-Op Statin	75 (79.8%)	2119 (79.8%)	2194 (79.8%)	0.820
Pre-Op Beta-Blocker	55 (58.5%)	1436 (54.1%)	1491 (54.2%)	0.491
Baseline Doppler Scan Result of Ipsilateral Carotid Artery				0.778
Mild or no stenosis (estimate of <50%)	1 (1.1%)	44 (1.7%)	45 (1.6%)	
Moderate stenosis (estimate of 50%-79%)	33 (35.1%)	1039 (39.1%)	1072 (39.0%)	
Severe stenosis (estimate of 80% to 99%)	56 (59.6%)	1499 (56.4%)	1555 (56.5%)	
Total occlusion (estimate of 100%)	2 (2.1%)	28 (1.1%)	30 (1.1%)	
Not performed	2 (2.1%)	46 (1.7%)	48 (1.7%)	
Baseline Doppler Scan Result of Contralateral Carotid Artery				0.063
Mild or no stenosis (estimate of <50%)	49 (52.1%)	1438 (54.1%)	1487 (54.1%)	
Moderate stenosis (estimate of 50%-79%)	18 (19.1%)	736 (27.7%)	754 (27.4%)	
Not performed	15 (16.0%)	274 (10.3%)	289 (10.5%)	
Severe stenosis (estimate of 80% to 99%)	8 (8.5%)	159 (6.0%)	167 (6.1%)	

Total occlusion (estimate of 100%)	4 (4.3%)	49 (1.8%)	53 (1.9%)	
ASA Class				< 0.001
1-No Disturb	0 (0.0%)	5 (0.2%)	5 (0.2%)	
2-Mild Disturb	5 (5.3%)	77 (2.9%)	82 (3.0%)	

3-Severe Disturb	59 (62.8%)	1801 (67.8%)	1860 (67.6%)	
4-Life Threat	25 (26.6%)	763 (28.7%)	788 (28.7%)	
5-Moribund	0 (0.0%)	5 (0.2%)	5 (0.2%)	
None assigned	5 (5.3%)	5 (0.2%)	10 (0.4%)	
Emergency Surgery	7 (7.4%)	203 (7.6%)	210 (7.6%)	0.944
Procedure Type	Multiple stents with CPD: 3 (3.2%)	Carotid Endarterectomy: 336 (12.7%)		
	Single straight stent: 10 (10.6%)	Carotid Endarterectomy w/ patch angioplasty: 1162 (43.8%)		
	Single straight stent with cerebral protection device (CPD): 48 (51.1%)	Carotid Endarterectomy w/ patch angioplasty & shunt: 844 (31.8%)		
	Single tapered stent: 3 (3.2%)	Carotid Endarterectomy w/ shunt: 79 (3.0%)		
	Single tapered stent with CPD: 30 (31.9%)	Eversion Carotid Endarterectomy: 234 (8.8%)		

Table 3: Thirty-Day Clinical Outcomes of the Cohort by Procedure Type

	Carotid Artery Stenting (N=94)	Carotid Endarterectomy (N=2656)	Total (N=2750)	-value
SSI : Superficial	1 (1.1%)	4 (0.2%)	5 (0.2%)	0.041
SSI: Deep Incision	0 (0.0%)	1 (0.0%)	1 (0.0%)	0.851
SSI: Organ Space	0 (0.0%)	1 (0.0%)	1 (0.0%)	0.851
Pneumonia	2 (2.1%)	39 (1.5%)	41 (1.5%)	0.604
Unplanned Reintubation	4 (4.3%)	35 (1.3%)	39 (1.4%)	0.018
Cardiac Arrest Requiring CPR	0 (0.0%)	7 (0.3%)	7 (0.3%)	0.618

Intraoperative or Postoperative Transfusion Required	3 (3.2%)	87 (3.3%)	90 (3.3%)	0.964
DVT requiring Therapy	0 (0.0%)	17 (0.6%)	17 (0.6%)	0.437
Distal Embolization	0 (0.0%)	11 (0.4%)	11 (0.4%)	0.532
Post-Procedure MI	5 (5.3%)	77 (2.9%)	82 (3.0%)	0.175
Post-Procedure Distal Embolization	0 (0.0%)	11 (0.4%)	11 (0.4%)	0.532
Post-Procedure TIA	0 (0.0%)	45 (1.7%)	45 (1.6%)	0.203
Post-Procedure Stroke	2 (2.1%)	86 (3.2%)	88 (3.2%)	0.548
Death	4 (4.3%)	44 (1.7%)	48 (1.7%)	0.059
Composite Outcome: Stroke or Death	5 (5.3%)	120 (4.5%)	125 (4.5%)	0.714
Post-Procedure Restenosis	0 (0.0%)	8 (0.3%)	8 (0.3%)	0.594
Follow-up Doppler Scan of Ipsilateral Carotid Artery				0.577
Mild or no stenosis (estimate of <50%)	29 (30.9%)	843 (31.7%)	872 (31.7%)	
Moderate stenosis (estimate of 50%-79%)	3 (3.2%)	62 (2.3%)	65 (2.4%)	

Severe stenosis (estimate of 80% to 99%)	0 (0.0%)	2 (0.1%)	2 (0.1%)	
Total occlusion (estimate of 100%)	1 (1.1%)	6 (0.2%)	7 (0.3%)	
Not performed	61 (64.9%)	1743 (65.6%)	1804 (65.6%)	
Target Lesion Revascularization	3 (3.2%)	30 (1.1%)	33 (1.2%)	< 0.001
Most Severe Outcome				

Amaurosis fugax or transient monocular blindness	0 (0.0%)	0 (0.0%)	0 (0.0%)	
Myocardial infarction	0 (0.0%)	3 (2.1%)	3 (2.1%)	
Other	1 (33.3%)	33 (23.2%)	34 (23.4%)	
Stroke	0 (0.0%)	3 (2.1%)	3 (2.1%)	
Transient ischemic attack	0 (0.0%)	3 (2.1%)	3 (2.1%)	
Procedure Specific Complications	Embolization: 1 (1.1%)	Acute occlusion/technical defects requiring revision: 13 (0.5%)		
	Thrombosis/occlusive dissection/vessel closure: 1 (1.1%)	Days from operation until cranial nerve injury: 68 (2.6%)		
	Puncture site Infection/Swelling: 2 (2.1%)			

Table 4: Multivariable Model for Thirty-Day Composite Outcome, Stroke only and Death only

Variable	Composite Outcome		Stroke		Death	
	OR (95% CI)	p-value	OR (95% CI)	p-value	OR (95% CI)	p-value
Age group: 85-89 vs 80-84	1.512 (1.017-2.248)	0.041	1.191 (0.742-1.913)	0.467	2.45 (1.29-4.63)	0.006
Age group - 90 and above vs 80-84	1.728 (0.937-3.186)	0.088	1.114 (0.492-2.523)	0.795	3.1 (1.29-7.46)	0.011
Female vs Male	0.939 (0.642-1.376)	0.748	0.944 (0.6-1.487)	0.807	0.99 (0.54-1.79)	0.979
Symptom: - Amaurosis fugax/TMB ipsilateral vs Stroke, ipsilateral	0.422 (0.208-0.855)	0.02	0.386 (0.151-0.985)	0.047	0.38 (0.13-1.09)	0.073

Symptom: Transient ischemic attack, ipsilateral vs Stroke, ipsilateral	0.625 (0.42-0.93)	0.03	0.881 (0.557-1.392)	0.088	0.28 (0.13-0.59)	0.010
History of Smoking	1.292 (0.656-2.546)	0.459	1.336 (0.599-2.977)	0.478	1.18 (0.4-3.43)	0.757
History of CHF	2.28 (0.838-6.204)	0.107	2.591 (0.848-7.916)	0.095	1.29 (0.16-10.3)	0.806
High Risk Anatomy	1.094 (0.609-1.964)	0.764	1.002 (0.495-2.025)	0.996	1.45 (0.6-3.49)	0.407
High Risk Physiology	0.766 (0.387-1.513)	0.442	0.915 (0.428-1.955)	0.820	0.33 (0.07-1.48)	0.151
No Pre-Op Aspirin Use	0.913 (0.492-1.693)	0.773	0.675 (0.298-1.525)	0.345	1.64 (0.72-3.74)	0.236
No Pre-Op Betablocker Use	0.771 (0.525-1.131)	0.183	0.947 (0.603-1.489)	0.817	0.61 (0.33-1.13)	0.120
No Pre-Op Statin Use	1.426 (0.911-2.235)	0.121	1.201 (0.689-2.095)	0.517	1.71 (0.87-3.34)	0.114
Stenosis Ipsilateral - <80% Stenosis vs >80% Stenosis	0.822 (0.558-1.211)	0.322	0.87 (0.551-1.375)	0.552	0.75 (0.4-1.4)	0.373
Stenosis Contralateral - >80% Stenosis vs <80% Stenosis	1.491 (0.817-2.724)	0.193	1.859 (0.94-3.677)	0.075	1.08 (0.4-2.91)	0.876
Stenosis Contralateral - Not Performed vs <80% Stenosis	1.175 (0.632-2.185)	0.611	1.539 (0.776-3.053)	0.217	0.41 (0.09-1.72)	0.225

Carotid Artery Stenting vs Carotid Endarterectomy	1.104 (0.431-2.828)	0.836	0.61 (0.145-2.556)	0.499	2.5 (0.82-7.59)	0.104
---	------------------------	-------	-----------------------	-------	--------------------	-------

Figure 1: Multivariable Predictive Model for (a) Composite Outcome (Stroke or Mortality), (b) Stroke and (c) Mortality within 30-Days After Carotid Revascularization Among Octogenarians

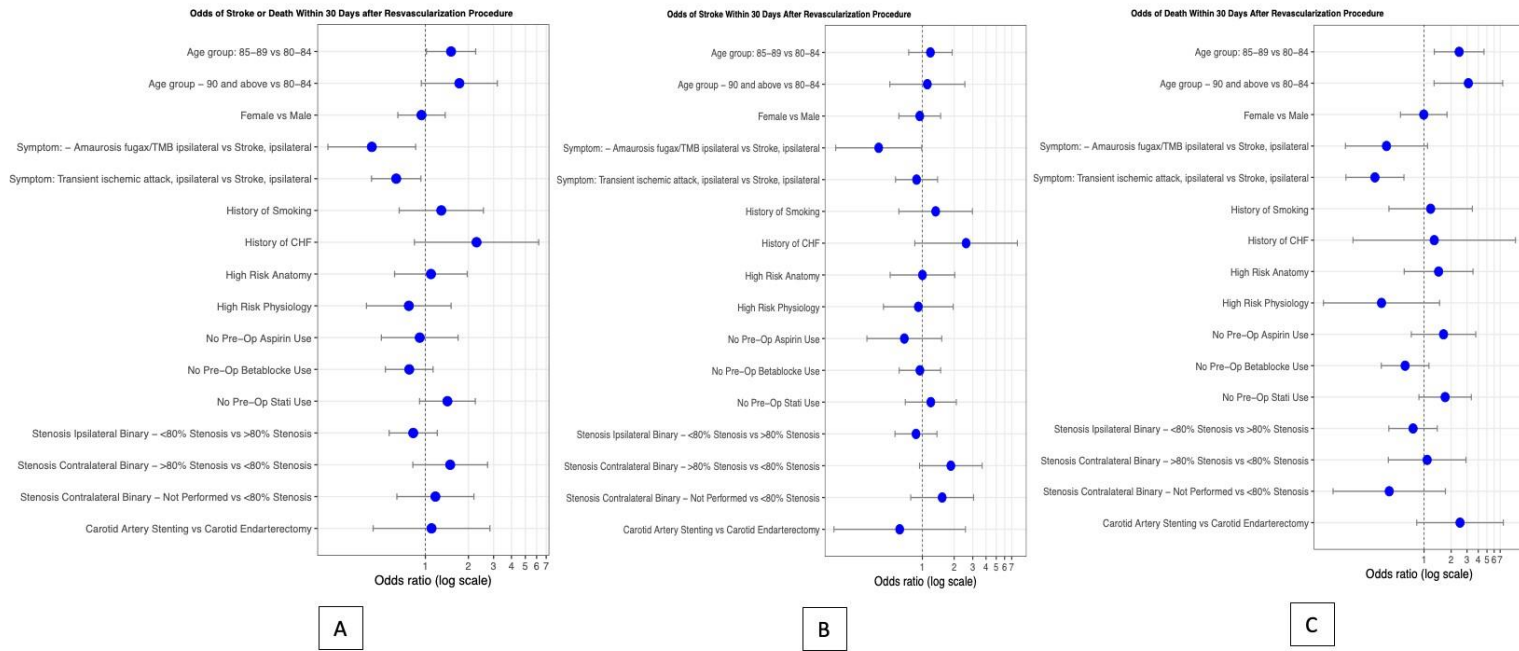


Figure 2: Predictor Importance Analysis for Multivariable Analyses for (a) Composite Outcome (Stroke or Mortality), (b) Stroke and (c) Mortality within 30-Days After Carotid Revascularization Among Octogenarians

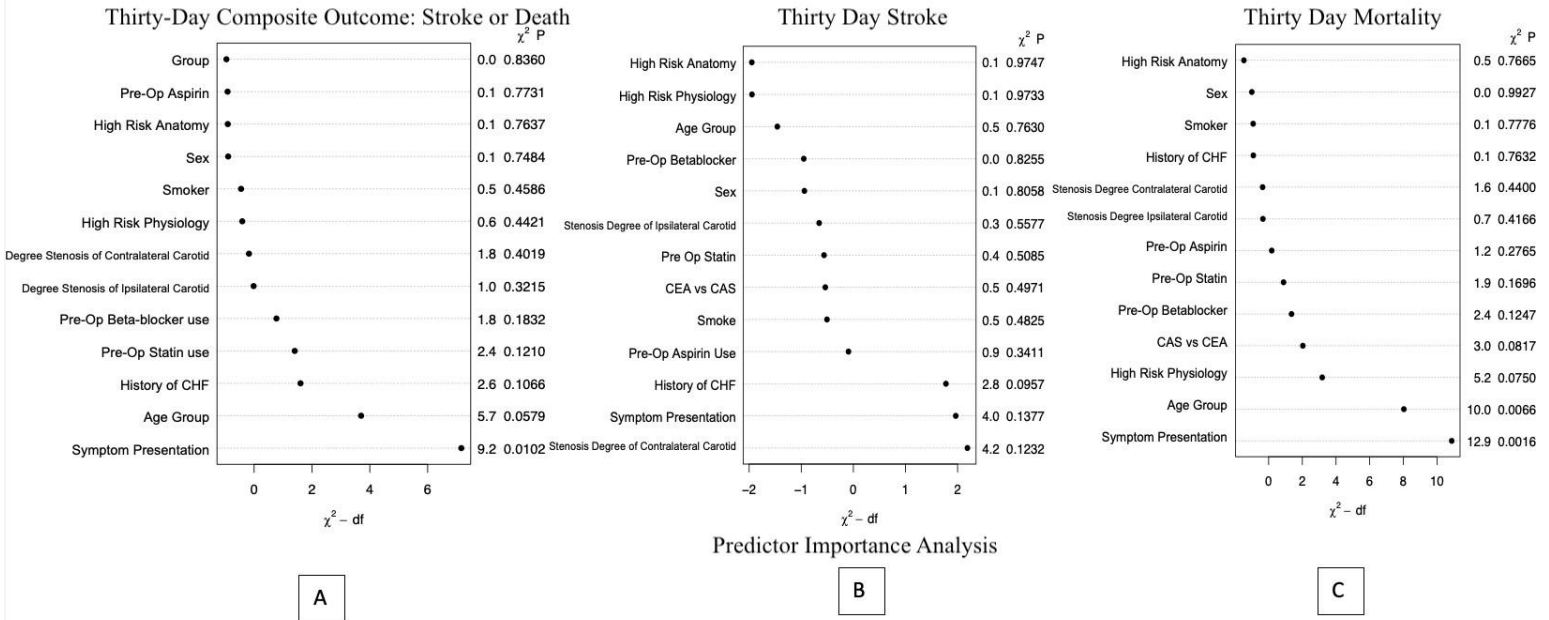
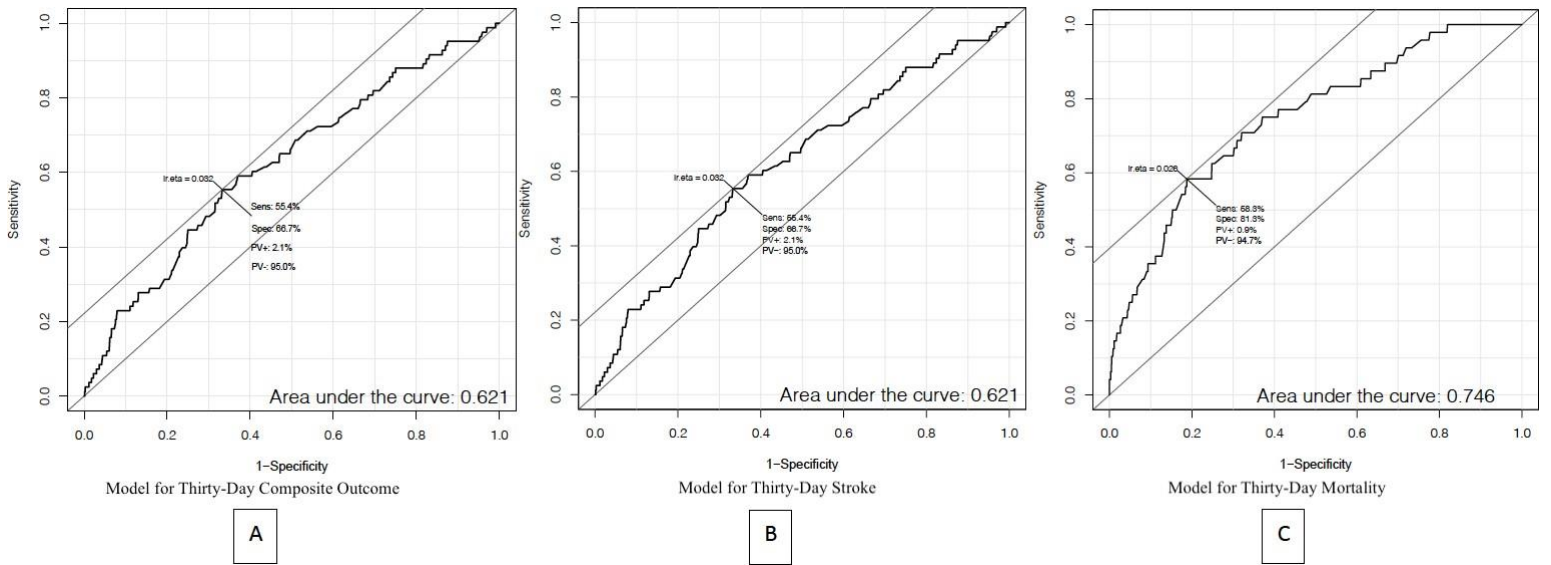


Figure 3: ROC Analyses for Predictive Multivariable Analyses for (a) Composite Outcome (Stroke or Mortality), (b) Stroke and (c) Mortality within 30-Days After Carotid Revascularization Among Octogenarians



Keywords: Carotid Stenting And Angioplasty, Carotid, Intra Caranial Stenosis, CEA,

Financial Disclosures: The authors had no disclosures.

Grant Support: None.

Poster

Economic Outcomes of Carotid-Revascularization Among Octogenarians with Symptomatic Carotid-Stenosis: Insights from A National Surgical Quality-Registry

Mohammed Ali Alvi, MBBS, MS¹, Yagiz Yolcu, MD¹, Jacob Korsachuk, MD², Kenan Rajjoub, MD³, Ozan Dikilitas, MD¹, Sarosh I Madhani, MD¹, Luis E Savastano, MD, Ph.D¹, Giuseppe Lanzino, MD¹

¹Mayo Clinic Rochester, Rochester, Minnesota, United States of America; ²Tufts Medical Center, Boston, Massachusetts, United States of America; ³Buffalo Regional Medical Center, Buffalo, New York, United States of America

Introduction:

Carotid endarterectomy (CEA) and carotid artery stenting (CAS) are two commonly employed procedures for surgical management of carotid stenosis. In the era of value-based care, it is important to identify drivers of low-value outcomes such as prolonged length of stay and discharge destination. In the current study, we sought to evaluate economic outcomes after CEA and CAS for patients aged ≥ 80 with symptomatic carotid stenosis.

Methods:

The National Surgical Quality Improvement Program (NSQIP) targeted datasets for CEA and CAS 2012-2018 were queried for patients aged ≥ 80 with symptomatic carotid stenosis. Outcomes included length of stay, discharge destination, work relative value units (RVUs) and number of CPT codes per case.

Results:

Of the 184 patients undergoing CAS and 5,814 patients undergoing CEA between 2012-2018, a total of 94 and 2,656 patients were symptomatic and were included in this study. Patients in the CAS groups were more likely to be aged 90 years or older (17% vs 7.9%, $p=0.006$). The mean length of stay was found to be similar between the two groups (CAS: mean 4.63 days vs CEA: 4.64 days). Patients in the CAS group were more likely to have a non-routine discharge (30.1% vs 20.6%, $p=0.027$) defined as discharge to a skilled care facility (CAS: 8.5% vs CEA 8.9%), hospice (CAS: 1.1% vs CEA:0.1%) or a separate acute care facility (CAS:2.1% vs CEA:0.9%). Patients in the CAS group had lower RVUs compared to those in the CEA group (19.7 vs 21.2, $p=0.017$). Patients in the CAS group were more likely to have more than one CPT code per case compared to those in the CEA group (19.1% vs 7.4%, $p<0.001$).

Conclusions:

These analyses from real-world data indicate that when compared to each other, CEA has higher RVUs and thus may cost more relative to CAS, while CAS may be associated with higher non-routine discharge and thus more downstream costs relative to CEA.

Table 1: Demographic and Comorbid Characteristics of the Cohort by Procedure Group

	Carotid Artery Stenting (N=94)	Carotid Endarterectomy (N=2656)	Total (N=2750)	p value
Age				0.006

80-84	52 (55.3%)	1617 (60.9%)	1669 (60.7%)	
85-89	26 (27.7%)	830 (31.2%)	856 (31.1%)	
90+	16 (17.0%)	209 (7.9%)	225 (8.2%)	
Sex				0.665
Female	35 (37.2%)	1048 (39.5%)	1083 (39.4%)	
Male	59 (62.8%)	1608 (60.5%)	1667 (60.6%)	
BMI	27.074 (4.950)	26.888 (4.825)	26.894 (4.829)	0.715
Race				0.128
American Indian or Alaska Native	0 (0.0%)	7 (0.3%)	7 (0.3%)	
Asian	3 (3.2%)	57 (2.1%)	60 (2.2%)	
Black or African American	5 (5.3%)	87 (3.3%)	92 (3.3%)	
Native Hawaiian or Pacific Islander	0 (0.0%)	1 (0.0%)	1 (0.0%)	
White	83 (88.3%)	2144 (80.7%)	2227 (81.0%)	
Unknown	0 (0.0%)	6 (0.2%)	6 (0.2%)	
Unknown/Not Reported	3 (3.2%)	354 (13.3%)	357 (13.0%)	
Diabetes				0.113
No	66 (70.2%)	2002 (75.4%)	2068 (75.2%)	
Insulin	13 (13.8%)	209 (7.9%)	222 (8.1%)	
Non-Insulin	15 (16.0%)	445 (16.8%)	460 (16.7%)	
Smoker	7 (7.4%)	182 (6.9%)	189 (6.9%)	0.823
History of CHF	3 (3.2%)	52 (2.0%)	55 (2.0%)	0.401
Hypertension	74 (78.7%)	2237 (84.2%)	2311 (84.0%)	0.152

Table 2: Economic Outcomes of the Cohort by Procedure Type

	Carotid Artery Stenting (N=94)	Carotid Endarterectomy (N=2656)	Total (N=2750)	p value
Hospital Length of Stay, Mean (SD)	4.628 (5.195)	4.643 (5.595)	4.643 (5.581)	0.979
Prolonged Length of Stay (>75th Percentile), n (%)	16 (17.0%)	632 (23.8%)	648 (23.6%)	0.127
Discharge Destination, n (%)				0.041
Against Medical Advice (AMA)	0 (0.0%)	2 (0.1%)	2 (0.1%)	
Facility Which was Home	1 (1.1%)	35 (1.3%)	36 (1.3%)	
Home	64 (68.1%)	2060 (77.6%)	2124 (77.3%)	
Hospice	1 (1.1%)	2 (0.1%)	3 (0.1%)	
Rehab	17 (18.1%)	281 (10.6%)	298 (10.8%)	
Separate Acute Care	2 (2.1%)	24 (0.9%)	26 (0.9%)	
Skilled Care, Not Home	8 (8.5%)	235 (8.9%)	243 (8.8%)	
Unknown	0 (0.0%)	2 (0.1%)	2 (0.1%)	
Discharge Destination (Binary) , n (%)				0.027
Non Routine	28 (30.1%)	544 (20.6%)	572 (20.9%)	
Routine	65 (69.9%)	2095 (79.4%)	2160 (79.1%)	
Total RVUs, Mean (SD)	19.683 (5.266)	21.240 (6.215)	21.186 (6.191)	0.017
Total CPTs, Mean (SD)	0.298 (0.685)	0.092 (0.376)	0.099 (0.392)	
Cases with More than One CPT, n (%)	18 (19.1%)	197 (7.4%)	215 (7.8%)	< 0.001
Total CPTs, n (%)				< 0.001
0	76 (80.9%)	2459 (92.6%)	2535 (92.2%)	
1	10 (10.6%)	165 (6.2%)	175 (6.4%)	
2	6 (6.4%)	22 (0.8%)	28 (1.0%)	

3	2 (2.1%)	7 (0.3%)	9 (0.3%)	
4	0 (0.0%)	2 (0.1%)	2 (0.1%)	
7	0 (0.0%)	1 (0.0%)	1 (0.0%)	

Keywords: Carotid Stenting And Angioplasty, CEA, Carotid

Financial Disclosures: The authors had no disclosures.

Grant Support: None.

Poster

Alarming Downtrend In Mechanical Thrombectomy Rates In Black Patients During COVID-19 Pandemic

Sami Al Kasab, MD¹, Eyad Almallouhi, MD¹, Ali Alawieh, MD², Pascal Jabbour, MD³, Ahmad Sweid, MD³, Robert Starke, MD⁴, Vasu Saini, MD⁴, Stacey Wolfe, MD⁵, Kyle M Fargen, MD⁵, Adam S Arthur, MD⁶, Nitin Goyal, MD⁶, Ilko Maier, MD⁷, Jonathan Grossberg, MD², Brian Howard, MD², Stavropoula I Tjoumakaris, MD³, Ansaar Rai, MD⁸, Min S Park, MD⁹, Justin Mascitelli, MD¹⁰, Marios Psychogios, MD¹¹, Alejandro M Spiotta, MD¹

¹MUSC, Charleston, South Carolina, United States of America; ²Emory, Atlanta, Georgia, United States of America; ³Thomas Jefferson, Philadelphia, Pennsylvania, United States of America; ⁴University of Miami, Miami, Florida, United States of America; ⁵Wake Forest, Winston Salem, North Carolina, United States of America; ⁶Semmes Murphy, Memphis, Tennessee, United States of America; ⁷University Medical Center Göttingen, Göttingen, Germany; ⁸West Virginia School of Medicine, Morgantwon, West Virginia, United States of America; ⁹University of Virginia, Charlottesville, Virginia, United States of America; ¹⁰UTH SA, San Antonio, Texas, United States of America; ¹¹University of Basel, Basel, Switzerland

Introduction:

Coronavirus disease (COVID-19) pandemic has affected stroke care globally. In this study, we aim to evaluate the impact of the current pandemic on racial disparities among stroke patients receiving mechanical thrombectomy (MT).

Methods:

We used the prospectively collected data in the Stroke Thrombectomy and Aneurysm Registry (STAR) from 12 thrombectomy capable stroke centers in the US and Europe. We included acute stroke patients who underwent MT between January 2017 and May 2020. We compared baseline features, vascular risk factors, location of occlusion, procedural metrics, complications, and discharge outcomes between patients presenting before (before February 2020) and those who presented during the pandemic (February to May 2020).

Results:

We identified 2083 stroke patients; of those 235 (11.3%) underwent MT during COVID-19 pandemic. Compared to pre-pandemic, stroke patients who received MT during the pandemic had longer procedure duration (44 vs. 38 minutes, $p=0.006$), longer length of hospitalization (6 vs. 4 days, $p<0.001$), and higher in-hospital mortality (18.7% vs. 11%, $p<0.001$). Importantly, there was a lower number of black patients undergoing MT during COVID-19 pandemic (609 (32.9%) vs. 56 (23.8%); $p=0.004$).

Conclusions:

The COVID-19 pandemic has affected the care process for stroke patients receiving MT globally. There is a significant decline in the number of black patients receiving MT, which mandates further investigation.

Tables:

Table 1: Characteristics, procedural metrics and outcomes of stroke patients receiving mechanical thrombectomy before and during COVID-19 pandemic.

	Thrombectomy patients during COVID-19 pandemic (n=235)	Thrombectomy patients before COVID-19 pandemic (n=1848)	P-value†
Age, median (IQR)	71 (59-79)	69 (58-79)	0.058
Females, n (%)	113 (48.1%)	901 (48.8%)	0.846
Black, n (%)	56 (23.8%)	609 (32.9%)	0.004
Admission NIHSS, median (IQR)	16 (10-21)	16 (10-21)	0.898
IV-tPA, n (%)	106 (45.1%)	831 (45%)	0.968
ASPECTS, median (IQR)§	9 (7-10)	9 (7-10)	0.225
Posterior circulation occlusion, n (%)	21 (8.9%)	195 (10.6%)	0.444
Symptom-onset to groin, median (IQR)	343 (202-576)	288 (178-575)	0.065
Number of passes, median (IQR)	2 (1-3)	2 (1-3)	0.921
mTICI≥2b, n (%)	196 (83.4%)	1588 (85.9%)	0.228
Procedure duration, median (IQR)	44 (25-73)	38 (21-63)	0.006
Procedure complications, n (%)	20 (8.5%)	163 (8.8%)	0.874
sICH, n (%)	15 (6.4%)	108 (5.8%)	0.741
Length of hospitalization, median (IQR)	6 (3-10)	4 (2-5)	<0.001
DC mRS, median (IQR)	4 (2-5)	3 (2-4)	0.015
Functional independence on discharge (mRS 0-2), n (%)	77 (32.8%)	637 (34.5%)	0.604
In-hospital mortality, n (%)	44 (18.7%)	203 (11%)	<0.001

Keywords: Endovascular, Mechanical Thrombectomy

Financial Disclosures: The authors had no disclosures.

Grant Support: None.

Poster

Transcervical Access To Bail Out Failed Transfemoral&Transbrachial Access In A Patient With Aortic Stent-Graft

Sinan Balci, MD¹, Mehmet A Topcuoglu, MD², Murat Arsava, MD², Anil Arat, MD¹

¹Hacettepe University Faculty of Medicine Department of Radiology, Ankara, Turkey; ²Hacettepe University Faculty of Medicine Department of Neurology, Ankara, Turkey

Introduction:

Endovascular mechanical thrombectomy has been the standard of care for acute ischemic stroke due to large vessel occlusion. Although transfemoral route is the most common access site, presence of anatomical difficulties such as aortic aneurysmal dilatation, tortuosity of aorta and supraaortic vessels preclude successful catheterization and thrombectomy especially among elderly patients. We report a case of mechanical thrombectomy in a patient with aortic stent graft and aneurysmal dilatation of aorta performed via direct carotid puncture after unsuccessful attempts of catheterization via transfemoral and transbrachial routes.

Methods:

A 71-year-old woman presented to the Emergency Department with loss of consciousness, right hemiparesis and aphasia. Her admission NIHSS score was 21. She had recent history of cardiovascular surgery due to hemopericardium and Stanford type A aortic dissection involving right coronary artery and aortic stent graft placement. Initial noncontrast CT examination was normal. CT angiography revealed left MCA cut-off at M2 segment and a dilated/elongated aortic arch as well as stent – grafts in the descending aorta. During mechanical thrombectomy, due to descending aortic dissection, aortic arch tortuosity and aneurysmal dilatation, catheterization attempts via right transfemoral and transbrachial access were unsuccessful. Direct left common carotid puncture was performed with a 5F short vascular sheath. 5F guiding catheter was navigated over a 0.016 microguidewire and a 0.027 microcatheter. Thrombus located at the MCA was removed via aspiration.

Results:

Final angiograms revealed TICI 2B revascularization at the left MCA territory and a parietal cortical branch filling in a retrograde fashion. Groin-to-revascularization time was 90 minutes. Local hemostasis at femoral and brachial puncture sites was achieved via manual compression whereas left carotid artery entry site was closed surgically. Her discharge NIHSS was 18 and mRs at 90 days was 3.

Conclusions:

Alternative access sites other than lower or upper extremities should be considered in cases with tortuous vascular anatomy and occlusion / stenosis of proximal vessels and access sites. Threshold to switch arterial access should not be high in case of failure of conventional access.

Keywords: Mechanical Thrombectomy

Financial Disclosures: The authors had no disclosures.

Grant Support: None.

Poster

Proximal Balloon Guide Catheter Assistance versus Distal Intermediate Catheter Assistance During Embotrap Stentriever Mechanical Thrombectomy

Hormozd Bozorgchami, MD¹, Osama Zaidat, MD², Jacob Bagley, MD¹, Jeffrey L Saver, MD³, Heinrich Mattle, Prof⁴, Marc Ribo, MD⁵, Tommy Andersson, MD PhD⁶

¹Oregon Health and Science University, Portland, Oregon, United States of America; ²St Vincent Mercy Hospital, Toledo, Ohio, United States of America; ³UCLA, Los Angeles, California, United States of America; ⁴University of Bern, Inselspital, Bern, Switzerland; ⁵Hospital Vall d'Hebron, Barcelona, Spain; ⁶Karolinska University Hospital, Stockholm, Sweden

Introduction:

The standard of care for the management of acute ischemic stroke (AIS) due to large vessel occlusion (LVO) changed with the publication of several randomized controlled trials in 2015, which demonstrated the efficacy and safety of mechanical thrombectomy using a stentriever device. There are a variety of different techniques that interventionalists deploy in order to perform mechanical thrombectomy with a stentriever, and there is little consensus on which method is superior. The aim of this analysis is to compare angiographic and clinical outcomes between balloon guide catheter (BGC, Proximal Assist) and Intermediate Catheter (IC, Distal Assist) use during mechanical thrombectomy (MT) for acute ischemic stroke.

Methods:

Data from the Analysis of Revascularization in AIS With EmboTrap (ARISE-2) trial were used. Patients who underwent MT with either a BGC (Proximal Assist) or IC (Distal Assist) as a first approach for treatment of anterior circulation stroke were included. Combined approach use was excluded. Outcomes were the first pass effect (FPE) and 90-day mRS rates (blinded to the assist approach).

Results:

A total of 136 and 53 patients met the inclusion criteria and had the BGC and IC as the first approach, respectively. Patients had similar baseline characteristics. The primary outcome of FPE-mTICI_{2b} was achieved in 79/136(58.1%) BGC vs. 22/53(41.5%) IC patients (p=0.04) and FPE-TICI_{≥2c} in 63/136(46.3%) BGC vs. 15/52 (28.3%) IC patients (p=0.02). The final excellent reperfusion (mTICI_{≥2c}), rates were higher in the BGC 110/136 (80.9%) versus IC patients 35/53(66%) (p=0.03). BGC use was associated with a higher rate of functional independence (mRS 0-2) at 3 months, 72.0%(95/132) vs 54.9%(28/52) (p=0.03). Multivariate analysis is ongoing but showing similar results.

Conclusions:

In ARISE 2, MT with proximal BGC assistance was associated with better clinical and angiographic outcomes than distal IC assistance alone. The study is limited by the sample size and smaller internal diameter of IC (<0.70").

Keywords: Mechanical Thrombectomy, Acute Ischemic Stroke Intervention, Balloon Guide Catheter, Access Catheters, Stentriever

Financial Disclosures: Consultant for Cerenovus. Modest payment

Grant Support: None.

Poster

Do outcomes between females and males differ after endovascular thrombectomy? A meta-analysis

Jose Danilo B Diestro, Fellow¹, Adam A Dmytriw, Fellow¹, Jerry C Ku, Resident¹, Victor Yang, Staff¹, Nicholas Hui, Student², Kazutaka Uchida, Staff³, Takeshi Morimoto, Staff³, Julian Spears, Staff¹, Thomas Marotta, Staff¹, Jose Danilo Diestro, Fellow¹

¹University of Toronto, Toronto, Canada; ²University of New South Wales, Sydney, Australia; ³Hyogo College of Medicine, Hyogo, Japan

Introduction:

Researches on the presence sex-based differences in the outcomes of patients undergoing endovascular thrombectomy for acute ischemic stroke have reached differing conclusions. Our paper aims to determine if sex influences the outcomes of large vessel occlusion stroke patients undergoing endovascular thrombectomy (EVT).

Methods:

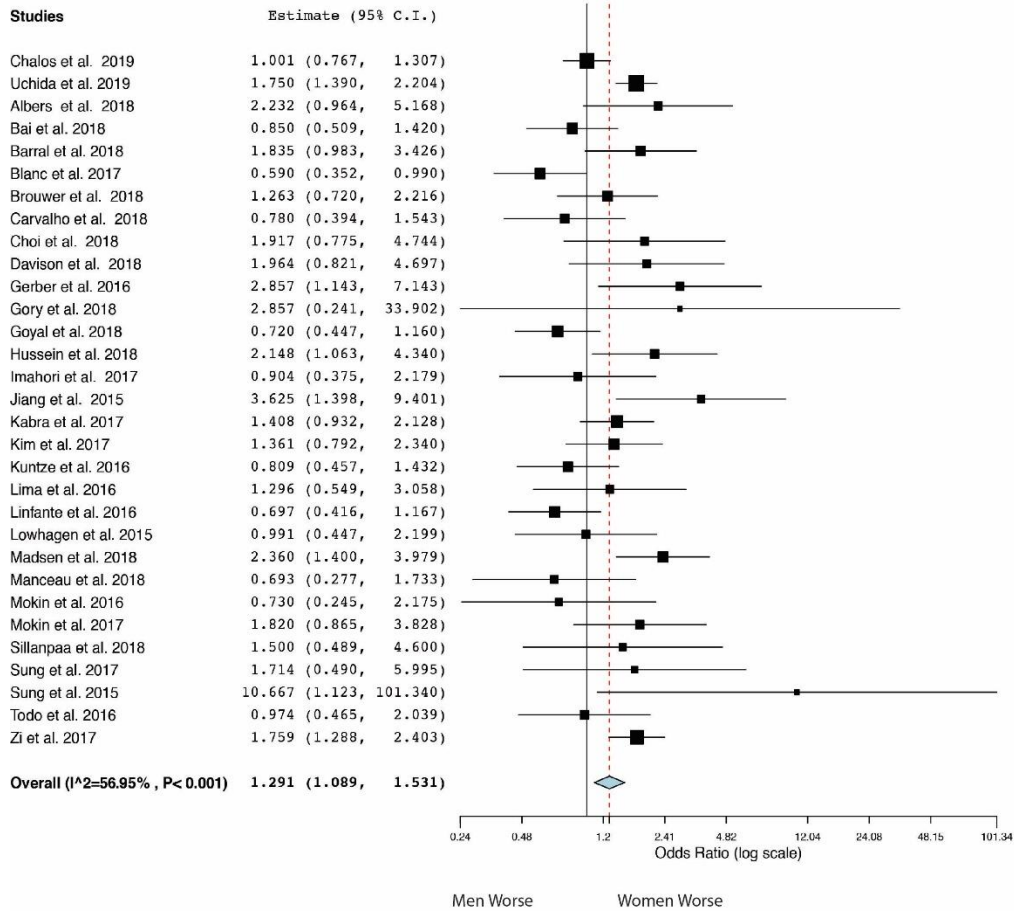
We performed a systematic review and meta-analysis of EVT studies with either stratified cohort outcomes according to sex (females versus males) or reported an effect size for the consequence of sex versus outcomes reported. We pooled odds ratios (OR) for 90-day modified Rankin scale (mRS) score, 90-day mortality, symptomatic intracranial hemorrhage (sICH) and recanalization.

Results:

We included 33 articles with 7,335 patients. Pooled 90-day good outcomes (mRS <2) was better for males than females (OR: 1.29, 95% CI: 1.09-1.53, $p < 0.001$, $I^2 = 56.95\%$). The odds of the other outcomes, recanalization (OR: 0.94, 95% CI: 0.77-1.15, $p = 0.38$, $I^2 = 0\%$), 90-day mortality (OR: 1.11, 95% CI: 0.89-1.38, $p = 0.093$, $I^2 = 0\%$) and sICH (OR: 1.40, 95% CI: 0.99-1.99, $p = 0.069$, $I^2 = 0\%$), were comparable between males and females.

Conclusions:

Females undergoing EVT for large vessel occlusion have inferior 90-day clinical outcomes. Careful attention to sex and reporting of specific outcomes in future trials as well as pathophysiologic studies should be done to investigate this phenomenon further.



Keywords: Mechanical Thrombectomy

Financial Disclosures: The authors had no disclosures.

Grant Support: None.

Poster

Utility of Mechanical Thrombectomy in Large Vessel Occlusions in Acute Ischemic Strokes with Low NIHSS

Sachin A Kothari, BS¹, Uttam Verma, MBBS², Michael Nahhas, MD³, Jennifer Waller, PhD¹, Jeffrey Switzer, DO¹, Dan-Victor Giurgiutiu, MD¹

¹Medical College of Georgia, Augusta, Georgia, United States of America; ²University of North Carolina, Chapel Hill, North Carolina, United States of America; ³University of Texas Health Science Center at Houston, Houston, Georgia, United States of America

Introduction:

Endovascular thrombectomy in moderate and severe acute ischemic strokes (NIHSS > 8) is proven to be successful; but remains controversial in milder acute ischemic strokes (NIHSS < 8).¹ This study was performed to provide insight on the utility of endovascular thrombectomy in large vessel occlusion ischemic strokes with low NIHSS scores.

Methods:

We retrospectively reviewed 49 patients presenting with an acute ischemic stroke, large vessel occlusion (LVO), and NIHSS < 8 who underwent either medical therapy (n=27), rescue (n=10), or urgent thrombectomy (n=12). The therapy decision was made by the vascular neurologist and neurointerventionalist on call based on clinical course and perfusion imaging. The urgent group included patients who underwent endovascular thrombectomy in less than 6 hours from presentation. The rescue group included patients that underwent endovascular thrombectomy beyond 6 hours from presentation with increasing NIHSS. Some patients in all groups received IV tPA according to institutional guidelines. Differences in risk factors, modified Rankin scale (mRS), thrombolysis in cerebral infarction (TICI) scores, perfusion maps, and occlusion sites were studied with analysis of covariance (ANCOVA), chi-square, and one-way analysis of variance models (ANOVA). For the ANOVA and ANCOVA models, a Tukey-Kramer multiple comparison test was used to examine post hoc pairwise differences between intervention groups.

Results:

Arrival NIHSS was significantly higher in the urgent group (5.4) compared to the rescue (2.7, p=0.009) and medical (3.9, p=0.034). The urgent thrombectomy group had a discharge NIHSS improvement (>1) in 92% compared to rescue (50%) and medical (52%) groups (p=0.02). Modified Rankin Scores (mRS) ≤ 2 on discharge were 75% for urgent, 50% for rescue, and 55.6% for medical (p=0.25) treatment groups. The urgent thrombectomy group displayed TICI reperfusion scores of 2b/3 in 100% of patients while the rescue thrombectomy group displayed TICI reperfusion scores of 2b/3 in 80% and 1/2a in 20% (p=0.076). The perfusion core (Cerebral Blood Flow (CBF) < 30%) was similar between the groups (2.1 cubic centimeter (cc), 1 cc, 9.2 cc, for urgent, rescue, and medical, respectively). The perfusion penumbra (Time to max (T_{max}) > 6 sec) and mismatch (T_{max} - CBF) was significantly larger for the urgent thrombectomy and rescue group. Penumbra volume was 80cc, 108cc, versus 51cc, p=0.0022, and for mismatch, 78 cc, 106cc, versus 42cc for, p=0.0022 for urgent and rescue thrombectomy versus medical therapy.

Conclusions:

Our data suggest a benefit of thrombectomy in urgent cases in acute ischemic strokes with low NIHSS scores. Drivers for reperfusion were a larger penumbra and a higher presenting NIHSS. A larger proportion of patients improved in the urgent than in the medical and rescue groups. However, the decision for treatment was ad hoc. Finally, larger perfusion defects were associated with rescue therapy. Indications for, and results from thrombectomy in LVO presenting with NIHSS < 8 should be investigated in randomized controlled clinical trials.

Keywords: Stroke, NIHSS, Mechanical Thrombectomy

Financial Disclosures: The authors had no disclosures.

Grant Support: None.

Poster

The Effect of Unfavorable Vascular Anatomy on MT for MCA Occlusion Preliminary Evaluation of AIM2 Score System

Okkes Kuybu, MD¹, Mahmoud Mohammad, MD¹, Diogo C Haussen, MD¹, Alhamza R Al-bayati, MD¹, Michael R Frankel, MD¹, Samir R Belagaje, MD¹, Raul G Nogueira, MD¹

¹Emory University, Atlanta, Georgia, United States of America

Introduction:

Time to reperfusion remains one of the strongest predictors of outcome in large vessel occlusion strokes (LVOS). Herein, we aim to assess the impact of unfavorable vascular anatomy on mechanical thrombectomy (MT) number of passes and procedural times.

Methods:

Retrospectively review of a prospective MT database spanning January-July 2018 including acute LVOS involving the middle cerebral artery-M1 segment and available baseline CT angiography. The AIM2 score (Table 1) was applied with patients categorized as favorable (AIM2: 0-2) versus unfavorable (AIM2: ≥ 3) anatomy. The primary outcome was the rate of < 3 device passes. Secondary outcomes included procedural times and the rates of successful reperfusion (mTICI2b-3) and 90-day mRS 0-2. Safety measures included rates of sICH and 90-day mortality.

Results:

Patients with unfavorable anatomy (n=15) were significantly younger (52 ± 19 , $p=0.02$) and had lower rates of hypertension (46% vs 80%, $p=0.01$) and smoking (0% vs 39%, $p<0.001$) versus those with favorable anatomy (n=50). Successful reperfusion with < 3 passes was more often achieved with AIM2 scores 0-2 vs. ≥ 3 (84% vs 60%, $p=0.04$). There were no significant difference in other outcome measures (Table 2).

Conclusions:

The AIM2 score system represents a simple method for the systematic evaluation of vascular anatomy in MT and correlates significantly with increased number of MT passes.

	Favorable Anatomy N=50	Unfavorable Anatomy N=15	P value
Demographic and comorbidities, n (%)			
Age, years mean±SD	67±15	52±19	0.02
Female	26(52)	4(26)	0.8
BMI > 25	29 (58)	8 (53)	0.74
HTN	40(80)	7(46)	0.01
HLD	17(34)	4(26)	0.56
A Fib	22(44)	3(20)	0.09
DM	10(20)	4(26)	0.58
Current smoking	17(39)	0(0)	<0.001
Clinical and procedure characteristics, n (%)			
Initial blood glucose, mg/dl median [IQR]	145 [70-220]	133 [90-176]	0.82
Baseline NIHSS score median [IQR]	17 [11-23]	15 [11-19]	0.23
IV-TPA	18(36)	6(40)	0.77
First-line Technique, Stent Retriever	31(62)	7(46)	<0.001
First-line Technique, Contact Aspiration	6(12)	7(46)	
First-line Technique, Combined	13(26)	1(6)	
LKN-Puncture, minutes median [IQR]	464 [83-845]	380 [137-623]	0.75
Procedure duration, minutes median [IQR]	61 [21-101]	44 [27-61]	0.37
Outcome, n (%)			
Number of passes (< 3)	42(84)	9(60)	0.04
Successful reperfusion (mTICI2-3)	24(48)	6(40)	0.58
Complete reperfusion (mTICI3)	19(38)	5(20)	0.73
Symptomatic ICH	2(4)	2(13)	0.18
90-day mRS 0-2	16/36(44)	7/12(58)	0.4
90-day mortality	5/36(13)	1/12(8)	0.6

Table 2: Demographic, comorbidities, procedural characteristics and outcome among favorable and unfavorable anatomy groups.

Table 1: AIM2 (Aortic Arch [A]; types I-III and bovine, intracerebral artery [I]; cervical and cavernous, middle cerebral artery [M]; ICA to MCA angle and M1 to M1 angle) Vessel Score Calculation Criteria

Criteria	Points
Aortic Arch or Bovine	
1. Aortic Arch Type	
Type I	0
Type II	1
Type III	2
2. Bovine	
Yes	1
No	0

Intracerebral Artery	
1. Cervical ICA	
Staight or Tortuosity	0
Coiling or KinKing	1
2. Cavernous ICA	
Type 1a, 1b and 2	0
Type 3 and 4	1
Middle Cerebral Artery Angles	
1. ICA-MCA	
> 90 °	0
≤ 90 °	1
2. M1-M1	
> 90 °	0
≤ 90 °	1

Keywords: Mechanical Thrombectomy, Acute Ischemic Stroke Intervention

Financial Disclosures: The authors had no disclosures.

Grant Support: None.

Poster

IGR Predictors and Impact of Age/Stroke Laterality on FIV Prediction of Outcome in MCA Occlusion

Mahmoud H Mohammaden, MD, MSc¹, Diogo C Haussen, MD¹, Alhamza R Al-Bayati, MD¹, Nirav Bhatt, MD¹, Bernardo liberato, MD¹, Nicolas Bianchi, MD¹, Michael Frankel, MD¹, Raul G Nogueira, MD¹

¹Grady Memorial Hospital, Emory University School of Medicine, Atlanta, Georgia, United States of America

Introduction:

Infarct growth rate (IGR) among patients with acute ischemic stroke (AIS) is highly variable. We aimed to evaluate the predictors of IGR which might help in streamlining patient triage and inter-institutional transfer.

Methods:

We reviewed a prospectively maintained database of AIS patients treated with mechanical thrombectomy (MT) from January-2012 through November-2019. All consecutive patients with isolated middle cerebral artery-M1 segment occlusion who achieved complete reperfusion (mTICI2c-3) and had a witnessed symptom onset were included. IGR was calculated as final infarct volume (FIV) (ml)/ symptom onset-Reperfusion time (hours) and was dichotomized according to the median value into slow (SP) versus fast progressors (FP). The primary analysis aimed to identify predictors of IGR. A secondary analysis was performed to evaluate the impact of age and stroke laterality on FIV prediction of 90-day functional outcome (modified Rankin Scale, mRS) by comparing the area under the receiver operating characteristic curves using the DeLong test.

Results:

Among 1744 MT a total of 134 patients with a mean age of 64±16 years were eligible for the analysis. The median IGR was 5.89 ml/hour. The SP group had a higher proportion of females (59.7% vs. 37.3%, p=0.01) and patients with hypoperfusion intensity ratio (HIR) ≤4 on CT Perfusion (60% vs. 21.3%, p<0.001) as well as higher median ASPECTS (9 vs. 8, p<0.001). SP showed higher 90-mRS 0-2 (69.6% vs. 35.8%, p<0.001) on univariate analysis. After adjustments, high ASPECTS (OR, 1.859; 95%CI [1.250-2.763], p=0.002) and HIR ≤4 (OR, 3.431; 95%CI [1.277-9.219], p=0.01) were found independently associated with slow IGR. In patients with left hemisphere stroke (n=53), the FIV had an AUC of 0.900 (95%CI [0.820-0.980], p<0.001). However, in the right hemispheric strokes (n=53) the FIV had an AUC of 0.687 (95%CI [0.543-831], p=0.02). FIV on the left hemisphere was more predictive of functional outcome compared to the right (DeLong test; p=0.0118). Similarly, in patients ≥70 years old (n=39) the FIV had an AUC of 0.917 (95% CI [0.818-1.00], p<0.001) compared to patients <70 years old (n=67) where FIV had an AUC of 0.745 (95% CI [0.626-0.864], p=0.001). FIV in elderly patients ≥70 years-old was more predictive of outcome than that of younger adults (DeLong test; p=0.0267).

Conclusions:

High ASPECTS and HIR ≤4 were associated with slower IGR. FIV in elderly patients ≥70 years old and those with left hemisphere stroke had a higher prediction of functional outcome. Large multicenter studies are warranted.

Table 1. Demographics, clinical, procedural characteristics and outcome in slow vs. fast progressors

	All Patients n = 134	Slow Progressor n = 67	Fast Progressor n = 67	P value
Demographic characteristics & Comorbidities n (%)				
Age (years) mean± SD	64±16	64.8±16.6	63.4±15.4	0.60
Ethnic background:				
White	63 (47)	27 (40.3)	36 (53.7)	
African American	56 (41.8)	33 (49.3)	23 (34.3)	
Other	15 (11.2)	7 (10.4)	8 (11.9)	0.21
Female	65 (48.5)	40 (59.7)	25 (37.3)	0.01
Body mass index median [IQR]	n=115 28.10 [24.29-32.65]	n=56 27.89 [24.65-31.50]	n=59 28.31 [24-35.87]	0.48
Initial glucose level median [IQR]	126 [106-156]	123 [101-151]	128 [112-160]	0.25
Hypertension	103 (76.9)	52 (77.6)	51 (76.1)	0.84
Diabetes mellitus	36 (26.9)	17 (25.4)	19 (28.4)	0.70
Dyslipidemia	36 (26.9)	16 (23.9)	20 (29.9)	0.44
Atrial fibrillation	56 (41.8)	29 (43.3)	27 (40.3)	0.73
Current smoking	23 (17.2)	11 (16.4)	12 (17.9)	0.82
Stroke etiology				
Cardioembolic	84 (62.7)	43 (64.2)	41 (61.2)	
Large vessel atherosclerosis	6 (4.5)	2 (3)	4 (6)	
ICAD	7 (5.2)	5 (7.5)	2 (3)	
Others	37 (27.6)	17 (25.4)	20 (29.9)	0.52
Clinical and Procedure Characteristics n (%)				
Symptom to Reperfusion time (min) median [IQR]	269.5 [208-358.5]	268 [205-385.5]	271 [209-356]	0.78
Baseline NIHSS score mean± SD	16.8±5.5	16.2±5.6	17.4±5.4	0.21
ASPECTS median [IQR]	n=112 8 [7-9]	n=60 9 [8-10]	n=52 8 [7-8.8]	<0.001
HIR ≤ 0.4	n=97 40 (41.2)	n=50 30 (60)	n=47 10 (21.3)	<0.001
Favorable collaterals	51/77 (66.2)	29/36 (80.6)	22/41 (53.7)	0.01
IV-tPA	87 (4.9)	41 (61.2)	46 (68.7)	0.37
Left hemisphere	65 (48.5)	35 (52.2)	30 (44.8)	0.39
General anesthesia	16 (11.9)	6 (9)	10 (14.9)	0.29
Minimum BP before reperfusion				
Systolic	120 [100-131]	120 [100-130]	120 [100-136]	0.15
Diastolic	60 [50-70]	60 [55-70]	60 [50-70]	0.86
Outcome n (%)				
Final infarct volume (ml) median [IQR]	28.13 [11.20-71.85]	11.22 [5.76-17.81]	71.28 [42.2-110.1]	<0.001
Parenchymal hematoma type2	2 (1.5)	0 (0)	2 (3)	0.50
90-day mRS 0-2	58/109 (53.2)	39/56 (69.6)	19/53 (35.8)	<0.001
90-day mortality	18/109 (16.5)	6/56 (10.7)	12/53 (22.6)	0.09

Abbreviations: IQR; interquartile range, NIHSS; National Institute of Health Stroke Scale, ASPECTS; Alberta Stroke Program Early CT Score, HIR; Hypoperfusion Intensity Ratio, IV-tPA; intravenous tissue plasminogen activator, ICH; intracerebral hemorrhage, mRS; modified Rankin Scale

Table 2. Multivariable regression analysis for slow progressors

	OR	95% CI	P value
ASPECTS	1.859	1.250 - 2.763	0.002
HIR ≤0.4	3.431	1.277 - 9.219	0.01
Female	2.406	0.917 - 6.314	0.075

Keywords: Acute Stroke, Aspects, MCA, Ct Perfusion

Financial Disclosures: The authors had no disclosures.

Grant Support: None.

Poster

Self-Expandable Stent Versus Balloon-Mounted Stent for Refractory Thrombectomy in Anterior Circulation Large Vessel Occlusion

Mahmoud H Mohammaden, MD, MSc¹, Diogo C Haussen, MD¹, Alhamza R Al-Bayati, MD¹, Nirav Bhatt, MD¹, Dinesh V Jillella, MD¹, Samir R Belagaje, MD¹, Michael R Frankel, MD¹, Raul G Nogueira, MD¹

¹Grady Memorial Hospital, Emory University School of Medicine, Atlanta, Georgia, United States of America

Introduction:

Successful recanalization is an important predictor of the outcome after mechanical thrombectomy (MT). Acute intracranial stenting has been utilized as a rescue procedure for refractory thrombectomy. Two types of intracranial stents can be deployed - self-expandable stents (SES) and balloon mounted stents (BMS). Herein, we aimed to study whether the type of stent affects the outcome of MT.

Methods:

A prospectively maintained database of all MT procedures from January 2011 to April 2020 was reviewed. Patients were included if they had an anterior circulation large vessel occlusion stroke treated with intracranial stent deployment. The population was divided into two groups - SES group and BMS group. The primary outcome was successful recanalization (mTICI2b-3) at the end of the procedure. Secondary outcomes were complete reperfusion (mTICI3) at the end of the procedure and functional independence that was defined as a 90-day mRS of 0-2. Safety outcomes included symptomatic intracranial hemorrhage (SICH), which was defined as intracranial hemorrhage leading to neurologic deterioration as reflected by NIHSS score worsening of ≥ 4 points, and 90-day mortality.

Results:

Among 2170 MT patients, 68 were eligible for analysis. The mean age was 64.3 ± 13.6 years, 34 (50%) were females, the mean baseline NIHSS score was 16.3 ± 6 and the median ASPECTS was 8 [7-9]. There was a trend toward higher rates of favorable collaterals (94.7% vs. 66.7%, $p=0.07$) and pre-morbid mRS 0-2 (94.6% vs. 77.4%, $p=0.07$) in SES group ($n=37$) as compared to BMS group ($n=31$). Other baseline demographics, clinical and procedural characteristics were comparable between both groups. SES and BMS groups had similar rates of successful reperfusion (81.1% vs. 83.9%, $p=0.76$), SICH (2.7% vs. 3.2%, $p>0.99$) and functional independence (23.3% vs. 25%, $p=0.89$). The rate of 90-day mortality was non-significantly lower in SES group as compared to BMS group (18.8% vs. 38.5%, $p=0.095$). After adjustment for potential confounders, stent type was not a predictor of successful reperfusion (SES; OR 0.444, 95%CI[0.049-4.055], $p=0.47$), SICH (SES; OR 0.793 95%CI[0.786-1.110], $p=0.44$), 90-day functional independence (SES; OR 1.125, 95%CI[0.233-5.438], $p=0.88$) or 90-day mortality (SES; OR 0.227 95%CI[0.033-1.567], $p=0.13$).

Conclusions:

In the setting of rescue stenting for refractory anterior circulation large vessel occlusion strokes, SES and BMS were comparable in terms of safety and outcome measures. Large prospective studies are warranted to confirm these findings.

Table 1. Baseline demographics, clinical, procedural characteristics, and outcome among SES and BMS group

	All Patients N=68	SES N=37	BMS N=31	P value
Demographic and clinical characteristics n (%)				
Age, years mean±SD	64.3±13.6	63.1±13.5	65.7±13.8	0.43
Female	34 (50)	17 (45.9)	17 (54.8)	0.47
Ethnicity:				
White	25 (36.8)	10 (27)	15 (48.4)	
African Americans	30 (44.1)	16 (43.2)	14 (45.2)	
Hispanic	6 (8.8)	5 (13.5)	1 (3.2)	
Asian	2 (2.9)	2 (5.4)	0 (0)	
Others	5 (7.4)	4 (10.8)	1 (3.2)	0.15
Arterial Hypertension	57 (83.8)	33 (89.2)	24 (77.4)	0.32
Diabetes Mellitus	24 (35.3)	15 (40.5)	9 (29)	0.32
Atrial Fibrillation	8 (11.8)	4 (10.8)	4 (12.9)	>0.99
Current smoker	14 (20.6)	6 (16.2)	8 (25.8)	0.33
Hyperlipidemia	25 (36.8)	16 (43.2)	9 (29)	0.23
Stroke etiology:				
Cardioembolic	13 (19.1)	7 (18.9)	6 (19.4)	
Large vessel atherosclerosis	10 (14.7)	4 (10.8)	6 (19.4)	
ICAD	38 (55.9)	22 (59.5)	16 (51.6)	
Others	7 (10.3)	4 (10.8)	3 (9.7)	0.82
Baseline NIHSS score mean±SD	16.3±6	15.7±6	17±6.3	0.36
ASPECTS median [IQR]	(N=59) 8[7-9]	8[7-9]	8[7-9]	0.28
Favorable collaterals	(N=34)	18/19 (94.7)	10/15 (66.7)	0.07
Premorbid mRS0-2	59 (86.8)	35 (94.6)	24 (77.4)	0.07
IV-tPA	16 (23.5)	6 (16.2)	10 (32.3)	0.12
LKN to Puncture, min median [IQR]	452[204-731.8]	491.5[200.8-742]	422[206-755.5]	>0.99
Procedural characteristics n (%)				
Site of occlusion:				
Internal carotid artery	19 (27.9)	8 (21.6)	11 (35.5)	
Middle cerebral artery				
M1	44 (64.7)	25 (67.6)	19 (61.3)	
M2	5 (7.4)	4 (10.8)	1 (3.2)	0.34
General anesthesia	27 (39.7)	16 (43.2)	11 (35.5)	0.52
Number of passes before stenting	1[1-2]	2[1-2]	1[1-2]	0.40
Procedure duration, min median [IQR]	112[84.3-133.3]	133[88.5-134.5]	101[70.5-134]	0.35
Outcome n (%)				
Successful reperfusion (mTICI2b-3)	56 (82.4)	30 (81.1)	26 (83.9)	0.76
Full reperfusion (mTICI3)	32 (47.1)	18 (48.6)	14 (45.2)	0.77
sICH	2 (2.9)	1 (2.7)	1 (3.2)	>0.99
24 hours NIHSS score mean±SD	(N=54) 12.3±7	12.6±6.8	11.9±7.5	0.71
90-day mRS0-2	(N=50) 12 (24)	7 (23.3)	5 (25)	0.89
90-day mortality	(N=58) 16 (27.6)	6/32 (18.8)	10/26 (38.5)	0.095

Keywords: Acute Ischemic Stroke Intervention, Mechanical Thrombectomy, Stenting,

Financial Disclosures: The authors had no disclosures.

Grant Support: None.

Poster

Comparison Of Transradial Artery Versus Transfemoral Artery Access For Solumbra Technique In Mechanical Thrombectomy

Taha Nisar, MBBS¹, Jimmy Patel, MD PhD Candidate¹, Muhammad Zeeshan Memon, MBBS¹, Amit Singla, MBBS¹, Priyank Khandelwal, MBBS¹

¹Rutgers New Jersey Medical School, Newark, New Jersey, United States of America

Introduction:

Solumbra technique involves the simultaneous use of stent-retriever and large-bore aspiration for clot retrieval in mechanical thrombectomy (MT). We aim to compare various time parameters in patients who undergo MT via solumbra technique via transradial artery (TRA) approach vs. transfemoral artery (TRF) approach.

Methods:

We performed a retrospective chart review of patients who underwent MT via solumbra technique for anterior circulation large vessel occlusion at a comprehensive stroke center from 7/2014 to 5/2020. We compared time to recanalization parameters, score of $TICI \geq 2b$, and functional independence (3-month $mRS \leq 2$) in patients who underwent MT via TRA vs. TRF approach via the solumbra technique. A binary logistic regression analysis was performed, controlling for age, sex, pre-treatment-NIHSS, type of anesthesia (general vs. moderate), laterality, and clot location [proximal (internal carotid or M1 segment of the middle cerebral artery) vs. distal (M2 or M3 segment of the middle cerebral artery)].

Results:

A total of 98 patients met our inclusion criteria. The mean age was 63.59 ± 14.40 years. 18 (18.37%) patients underwent MT through transradial approach. In our cohort, there was a significant association of TRA with shorter angio suite arrival-time to puncture-time (22.12 ± 9.92 mins vs. 28.83 ± 12.26 mins; OR, 0.94; 95% CI, 0.88-1; P 0.026), but not with puncture-time to recanalization-time (84.34 ± 61.34 mins vs. 63.73 ± 35.29 mins; OR, 1.01; 95% CI, 1-1.03; P 0.085), angio suite arrival-time to recanalization-time (103.12 ± 51.29 mins vs. 93.42 ± 39.08 mins; OR, 1.01; 95% CI, 1-1.02; P 0.524), number of passes to recanalization (1.78 ± 1.36 vs. 1.68 ± 1.05 ; OR, 1.03; 95% CI, 0.66-1.63; P 0.899), number of patients with $TICI \geq 2b$ (83.34% vs. 91.25%; OR, 0.68; 95% CI, 0.14-3.4; P 0.633), and functional independence (66.67% vs. 78.75%; OR, 0.49; 95% CI, 0.13-1.86; P 0.292), when compared to TRF approach for MT using solumbra technique.

Conclusions:

Our study demonstrates a significant association between TRA approach with shorter angio suite arrival-time to puncture-time but not with overall time to recanalization, number of patients with $TICI \geq 2b$, and functional independence, when compared to TRF approach for MT using solumbra technique.

Keywords: Acute Stroke, Stroke, Endovascular Therapy

Financial Disclosures: The authors had no disclosures.

Grant Support: None.

Poster

Association Of 24-hour Blood Pressure Parameters Post-thrombectomy With Mortality In Basilar Artery Occlusion

Taha Nisar, MBBS¹, Toluwalase Tofade, MD¹, Osama Abu-hadid, MD¹, Muhammad Zeeshan Memon, MBBS¹, Amit Singla, MBBS¹, Priyank Khandelwal, MBBS¹

¹Rutgers New Jersey Medical School, Newark, New Jersey, United States of America

Introduction:

Higher blood pressure (BP) after endovascular mechanical thrombectomy (MT) is associated with worse outcomes in patients with anterior circulation large-vessel-occlusion. There is a paucity of data with respect to the role of BP post-MT in patients with basilar-artery-occlusion (BAO). We aim to investigate the association of different 24-hour-BP parameters post-MT with 3-month mortality in patients with BAO.

Methods:

We performed a retrospective chart review of patients who underwent MT for BAO at a comprehensive stroke center from July-2014 to May-2020. We obtained the BP values recorded in the electronic medical record over a period of 24-hours post-MT. A binary logistic regression analysis was performed, controlling for age, sex, pre-treatment-NIHSS, TICI score $\geq 2b$, onset to recanalization time, and administration of intravenous-alteplase (IV-rtPA), with the BP parameters as the predictors. The primary outcome was mortality at 3 months.

Results:

16 patients met our inclusion criteria. 12 (75%) patients were male. The mean age was 61.69 ± 14.81 years. 11 (65.75%) patients had 3-month mortality. The mean pre-treatment NIHSS was 19.19 ± 7.82 . 2 (12.6%) patients developed sICH. In our cohort, the 24-hours-post-MT-BP parameters of higher mean systolic blood pressure (SBP) (146.44 ± 14.88 vs. 138.49 ± 12.9 ; OR, 0.91; 95% CI, 0.75-1.12; P 0.367), higher mean diastolic blood pressure (DBP) (83.76 ± 15.37 vs. 70.22 ± 7.27 ; OR, 0.86; 95% CI, 0.62-1.2; P 0.363), and higher mean higher mean arterial pressure (MAP) (104.21 ± 14.71 vs. 92.98 ± 6.49 ; OR, 0.89; 95% CI, 0.67-1.19; P 0.423) were not significantly associated with mortality at 3 months.

Conclusions:

Our study did not demonstrate a significant association of 24-hours-post-MT-BP parameters with 3-month-mortality in patients with BAO. Further studies need to be done to confirm the findings of our research.

BP Variables	mRS ≤5	Mortality	Multivariate analysis
(mm Hg)	N=5	N=11	P
Mean SBP 24-hours	146.44±14.88	138.49±12.9	OR, 0.91; 95% CI, 0.75-1.12; P 0.367
Mean DBP 24-hours	83.76±15.37	70.22±7.27	OR, 0.86; 95% CI, 0.62-1.2; P 0.363
Mean MAP 24-hours	104.21±14.71	92.98±6.49	OR, 0.89; 95% CI, 0.67-1.19; P 0.423
Maximum SBP	172.5±13.03	172.73±20.01	OR, 1.05; 95% CI, 0.93-1.18; P 0.483
Minimum SBP	119.8±13.96	108.41±13.96	OR, 0.97; 95% CI, 0.86-1.1; P 0.626
SBP Range	52.7±13.75	64.32±18.58	OR, 1.04; 95% CI, 0.96-1.13; P 0.42
Maximum DBP	107.2±24.82	89.96±9.63	OR, 0.89; 95% CI, 0.72-1.1; P 0.264
Minimum DBP	64.6±15.79	54.55±7.04	OR, 0.99; 95% CI, 0.85-1.15; P 0.824
Pulse Pressure	62.69±8.6	68.28±14.79	OR, 1.01; 95% CI, 0.83-1.24; P 0.937
Standard Deviation SBP	13.17±3.24	17.26±6.91	OR, 1.18; 95% CI, 0.87-1.61; P 0.296
Coefficient Variation SBP	9.08±2.44	12.52±4.95	OR, 1.27; 95% CI, 0.84-1.92; P 0.257
Standard Deviation DBP	10.4±3.43	9.79±3.48	OR, 0.55; 95% CI, 0.19-1.61; P 0.272
Coefficient Variation DBP	12.33±3.44	14.09±5.44	OR, 0.68; 95% CI, 0.25-1.85; P 0.441
Standard Deviation MAP	10.74±3.43	11.06±4.08	OR, 0.83; 95% CI, 0.47-1.47; P 0.518
Coefficient Variation MAP	10.3±3.04	11.9±4.39	OR, 0.94; 95% CI, 0.55-1.62; P 0.821

Table: Multivariate Binary Logistic Regression Analysis of 24-hours-post-MT-BP parameters in patients with Basilar Artery Occlusion, associated with the 3-month mortality.

Abbreviation: BP, Blood Pressure; SBP, Systolic Blood Pressure; DBP, Diastolic Blood Pressure; MAP, Mean Arterial Pressure; CV, Coefficient Variability; SD, Standard Deviation; MRS, Modified Rankin Scale, MT, Mechanical Thrombectomy.

Keywords: Basilar, Blood Pressure Management In Acute Stroke

Financial Disclosures: The authors had no disclosures.

Grant Support: None.

Poster

Association Of Anemia With Functional Outcomes In Patients With Mechanical Thrombectomy

Taha Nisar, MBBS¹, Osama Abu-hadid, MD¹, Toluwalase Tofade, MD¹, Sara Shapouran, MD¹, Muhammad Zeeshan Memon, MBBS¹, Amit Singla, MBBS¹, Priyank Khandelwal, MBBS¹

¹Rutgers New Jersey Medical School, Newark, New Jersey, United States of America

Introduction:

Anemia at presentation is associated with worse outcomes in patients with acute ischemic stroke. We aim to investigate the association of anemia upon presentation with functional outcomes in patients who undergo mechanical thrombectomy (MT).

Methods:

We performed a retrospective chart review of patients who underwent MT for anterior circulation large vessel occlusion at a comprehensive stroke center from 7/2014 to 5/2020. Anemia was considered a dichotomous categorical variable with a cutoff point of hemoglobin <12.0 g/dL in women and <13.0 g/dL in men, as per the definition of the World Health Organization. A binary logistic regression analysis was performed, controlling for age, pre-treatment-NIHSS, ASPECTS ≥ 6 , TICI score $\geq 2b$, onset to recanalization time, and administration of intravenous-alteplase (IV-rtPA), with the presence of anemia as the predictor. The primary outcome was a good functional outcome at 3-months (mRS of ≤ 1). The secondary outcomes were 3-month mortality, sICH (ECASS-II criteria), and infarct volume on follow-up CT Head.

Results:

177 patients met our inclusion criteria. The mean age was 64.34 ± 15.16 years. 93 (52.54%) patients were men. 34 (19.21%) patients had 3-month mRS ≤ 1 . 11 (6.21%) patients developed sICH. Among men, there was a significant association of anemia with lesser chance of good functional outcome (5.89% vs. 23.73%; OR, 6.1; 95% CI, 1.3-30.5; P 0.028), higher mortality (52.94% vs. 30.51%; OR, 2.9; 95% CI, 1.1-7.8; P 0.038), and a larger infarct volume (106.12 ± 109.78 mls vs. 73.02 ± 74.36 mls.; OR, 1.1; 95% CI, 1.1-1.1; P 0.032), but not with sICH (5.89% vs. 5.26%; OR, 1.6; 95% CI, 0.2-12.2; P 0.681). Among women, there was no significant association of anemia with any outcome measures: mRS ≤ 1 (25% vs. 31.25%; OR, 0.84; 95% CI, 0.27-2.59; P 0.754), mortality (25% vs. 23.08%; OR, 1.26; 95% CI, 0.4-3.97; P 0.693), infarct volume (60.08 ± 94.46 mls vs. 69.05 ± 97.74 mls.; OR, 1; 95% CI, 1-1.01; P 0.981), and sICH (9.37% vs. 5.89%; OR, 1.52; 95% CI, 0.26-8.88; P 0.643).

Conclusions:

Our study demonstrates a gender difference in outcomes in patients with anemia at presentation who undergo MT. In our cohort, men had an association between anemia and mRS ≤ 1 , mortality, and a larger infarct volume, unlike women.

Keywords: Acute Stroke

Financial Disclosures: The authors had no disclosures.

Grant Support: None.

Poster

Feasibility of Intracranial Navigation of 088 Large Bore Aspiration Catheters During Stroke Thrombectomy

Raul G Nogueira, MD¹, Mahmoud H Mohammaden, MD, MSc¹, Alhamza R Al-Bayati, MD¹, Michael Frankel, MD¹, Diogo C Haussen, MD¹

¹Grady Memorial Hospital, Emory University School of Medicine, Atlanta, Georgia, United States of America

Introduction:

Thromboaspiration technology continues to evolve at an accelerated pace with the increasing availability of larger and more navigable devices. Herein, we provide our initial experience with the intracranial navigation of novel large-bore (.088" inner diameter) aspiration catheters during stroke mechanical thrombectomy (MT).

Methods:

Retrospective review of consecutive emergent large vessel occlusion stroke (ELVO) patients in whom a TracStar[®] or Zoom 88[®] (Imperative Care, Campbell, CA) large-bore catheters were utilized in MT. The primary outcome was successful reperfusion (eTICI2b-3) at the end of the procedure. Safety measures included procedural complications and rates of symptomatic intracranial hemorrhage (SICH).

Results:

Four patients (age, ~50-85 years; baseline NIHSS, 17-23) were treated. The .088" catheters were used as the primary tool for contact aspiration in one patient with distal basilar artery occlusion and one patient with proximal MCA occlusion with complete thrombus ingestion (eTICI3) during the first pass on both cases. Another patient was treated with a combination of stent-retriever and .070" aspiration catheter for an M2 occlusion with placement of the .088" catheter in the distal M1 segment for flow control resulting in eTICI3 reperfusion. In the fourth patient, the .088" catheter was navigated into the cavernous ICA to support .071" aspiration catheter treatment of an M2 occlusion resulting in eTICI2b67 reperfusion. Procedural duration ranged between 14 and 33 minutes. There were no adverse events.

Conclusions:

Intracranial navigation of novel .088" large-bore catheters in MT appears technically feasible and safe technically feasible. Larger prospective studies are warranted.

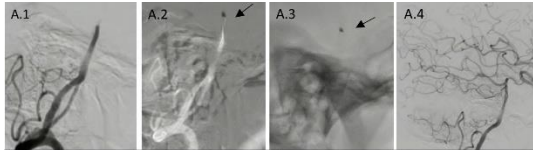


Figure 1 shows the lateral angiographic view for the baseline top of basilar artery occlusion (A.1) and the tip of the .088[™] catheter (arrow) at the distal basilar artery on roadmap (A.2) and native unsubtracted (A.3) images. Final angiography, lateral view shows full reperfusion (eTICI 3) (A.4).

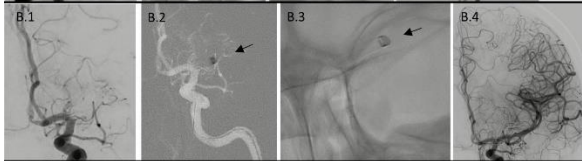


Figure 2 shows anterior-posterior view for the baseline angiography illustrates a proximal MCA-M1 occlusion (B.1) and the tip of the .088[™] catheter (arrow) at the mid MCA-M1 segment on roadmap (B.2) and native unsubtracted (B.3) images. Final angiography shows full reperfusion (eTICI 3) (B.4).

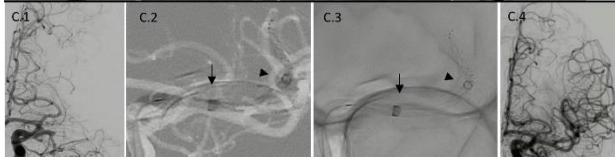


Figure 3 demonstrates anterior-posterior view for the baseline angiography showing complete occlusion of the proximal MCA-M1 segment (C.1) and the tips of the .088[™] (arrow) and Sofia Plus (arrowhead) catheters in the mid MCA-M1 and distal M2, respectively, with a Trevo XP 4 x 30 mm extending into the M3 on roadmap (C.2) and native unsubtracted (C.3) images. Note that original occlusion migrated from the proximal M1 into the distal M2 after the initial microcatheterization. Final angiography shows full reperfusion (eTICI 3) (C.4).

Keywords: Acute Ischemic Stroke Intervention, Mechanical Thrombectomy

Financial Disclosures: Consulting; Stryker Neurovascular, Cerenovus, Medtronic, Phenox, Anaconda, Genentech, Biogen, Prolong Pharmaceuticals, Imperative Care

Grant Support: None.

Poster

Safety of Eptifibatide use in Thrombectomy for Treatment of Large Vessel Occlusion Stroke

Ameena Rana, BA¹, Siyuan Yu, BS¹, Scott Kamen, BS¹, Justin Gold, BS¹, Mark Heslin, BS¹, Lauren Thau, BS¹, James Siegler, MD², Olga Thon, MD², Hamza Shaikh, MD², Brian Jankowitz, MD², Tudor Jovin, MD², Jesse Thon, MD²

¹Cooper Medical School of Rowan University, Camden, New Jersey, United States of America; ²Cooper University Hospital, Camden, New Jersey, United States of America

Introduction:

Recent studies have shown that eptifibatide, when used with intravenous thrombolysis for acute stroke, was not associated with an increased intracerebral hemorrhage (ICH) risk.^{1,2,3} The safety of eptifibatide in large vessel occlusion (LVO) stroke is unknown, and we evaluated its use in combination with endovascular therapy (EVT) for treatment of LVO.

Methods:

A single-center retrospective cohort of patients with LVO who underwent EVT (04/2019-08/2020) was queried for treatment with eptifibatide and compared to a contemporaneous group that did not receive eptifibatide. The primary safety outcome was symptomatic ICH (sICH), defined by worsening on NIHSS of 4 points within 24 hrs (+/- 6 hrs if not evaluated at 24 hrs) of angiography, with PH1 or PH2 grade or IVH and/or SAH, and deemed responsible for the clinical worsening. Secondary outcomes included any ICH and in-hospital mortality or hospice care. Descriptive statistics were used for between group comparisons. Multivariable logistic regression was used to estimate the association of eptifibatide with sICH, after adjustment for age, NIHSS, baseline ASPECTS, and treatment with IV thrombolysis.

Results:

A total of 100 patients treated with EVT were included (median age 69 [SD 20], NIHSS 15 [IQR 3-27]), 43 of whom received eptifibatide (Table). Patients in the eptifibatide group had lower rates of hypertension, atrial fibrillation, and heart failure ($p < 0.05$, Table). sICH occurred in 5 (11.6%) patients in the eptifibatide group compared to 1 (1.8%) in the control group (OR 7.37, 95%CI .828-65.58 $p = 0.082$), a difference that reached statistical significance with multivariable adjustment (OR 16.81; 95 CI .998-283.17, $p = 0.05$). There were no significant differences between any ICH (eptifibatide group 53.5% vs. 40.4%, $p = 0.23$) or in-hospital mortality/hospice care (30.2% vs. 26.3%, $p = 0.82$).

Conclusions:

Our single-center experience suggests a potentially elevated risk of sICH associated with eptifibatide use in patients undergoing EVT for LVO. However, unmeasured confounders leading to the decision to treat with eptifibatide likely also contributed to this risk. Randomized controlled trials are needed to confirm our findings.

Table: Baseline characteristics and safety outcomes in patients undergoing thrombectomy treated with or without eptifibatide

	Total	Thrombectomy	Eptifibatide + Thrombectomy	Significance
	(N=100)	(N= 57))	(N= 43)	(p-value)
Age, mean y (SD-15)	68 (53-83)	69 (53-85)	66.00 (52-80)	0.222
Female, no. (%)	47 (47.0)	30 (52.6)	17 (39.5)	0.228
IV thrombolysis Administration no. (%)	25 (25.0)	15 (26.3)	10 (23.3)	.818
NIHSS median (IQR)	15 (9-21)	16 (9-24)	12 (8-20))	0.224
Baseline ASPECT Score, Median (ITQ), N= 86	9 (8-10)	9 (8-10), N=59	9 (8-10), N=27	0.260
Pre-Hospital mRS Median, (IQR) N=97	0 (0-2)	0 (0-2), N=59	0 (0-2), N=38	0.961
Past Medical History				
Prior stroke	22 (22.2%)	14 (25.4%)	8(17.1%)	0.627
Diabetes	27 (27.0%)	15 (26.3%)	12 (27.9%)	1.000
Hypertension	72 (72.0%)	49 (86.%)	23 (53.5%)	0.001

Coronary artery disease	12 (12.1)	8 (13.6%)	4 (9.8%)	0.547
Dyslipidemia	48 (48.0%)	32 (56.1%)	16 (37.2%)	0.071
Congestive Heart Failure	17 (17.2%)	15 (26.3%)	2 (4.7%)	0.006
Atrial fibrillation	26 (26.3%)	21 (36.8%)	5 (11.6%)	0.004
<i>Safety Outcomes</i>				
In Hospital Mortality/ Hospice/LTAC no. (%)	28 (28.0)	15 (26.3)	13 (30.2)	0.822
New Intracranial Hemorrhage on follow up imaging no. (%)	46 (46.0)	23 (40.4)	23 (53.5)	0.227
Symptomatic Intracranial Hemorrhage no. (%)	6 (6.0)	1 (1.8)	5 (11.6)	0.082

Keywords: Acute Ischemic Stroke Intervention, Acute Stroke, Endovascular Therapy, Ischemic Stroke

Financial Disclosures: The authors had no disclosures.

Grant Support: None.

Poster

Single Comprehensive Stroke Center Experience of Endovascular Therapy vs Medical Management: Extended Window with Poor ASPECTS

Ameena Rana, BA¹, Siyuan Yu, BS¹, Justin Gold, BS¹, Scott Kamen, BS¹, Mark Heslin, BS¹, Lauren Thau, BS², Brian Jankowitz, MD², Tudor Jovin, MD², Jesse Thon, MD², Hamza Shaikh, MD², James Siegler, MD²

¹Cooper Medical School of Rowan University, Camden, New Jersey, United States of America; ²Cooper University Hospital, Camden, New Jersey, United States of America

Introduction:

The HERMES collaboration demonstrated that endovascular therapy (EVT) within 6 hours of anterior circulation large vessel occlusion (LVO) and low ASPECTS (<6) is associated with better long-term outcomes than medical management.^{1,2} The benefit of thrombectomy in patients with low ASPECTS in the extended window is less clear.

Methods:

A single-center retrospective cohort of adult patients admitted 04/2015-07/2020 with anterior LVO and low ASPECTS who underwent EVT in the extended window (6-24 hours after last known well) was compared to a contemporaneous group that received only medical management. The odds of poor long-term outcome (3-month modified Rankin Scale score 3-6) were estimated using logistic regression, and were adjusted for age and baseline NIHSS.

Results:

Of the 324 patients who underwent thrombectomy during the study period, after excluding 40 patients with unavailable initial CT, 20 patients met inclusion criteria (7.04%), 8 of whom underwent EVT (Table). EVT was not associated with a higher odds of poor long-term outcome in unadjusted (OR 0.818, 95%CI 0.023-28.598) or adjusted logistic regression (adjusted OR 0.811, 95%CI 0.23-28.598), although most patients in both groups were ultimately transitioned to comfort measures during their hospitalization (63% EVT and 67% medical management). There were no cases of sICH in patients who had undergone EVT or medical management.

Conclusions:

Preliminary findings from this single-center retrospective cohort suggest EVT was associated with similar, poor long-term functional outcomes when compared to medical management in patients with low ASPECTS who presented in the extended time window. Any benefit of EVT in this cohort may be confounded by the high proportion of patients who transitioned to comfort care. A subgroup analysis of patients who pursued intensive medical treatment is planned once a larger sample size is reached.

Table. Baseline characteristics of patients undergoing EVT and medical treatment for LVO and ASPECTS <6 in the extended window.

	Medical treatment (N=12)	EVT (N=8)	Significance
Age (median, ITQ)	64 (53-78)	71 (62-82)	0.27
Male, no. (%)	8 (66.7%)	4 (50%)	0.648
Baseline Aspect Score (ITQ)	4 (3-5)	4.5 (2.5-5)	0.335
Baseline mRS score (ITQ)	0 (0-1)	0 (0-1)	1
NIHSS score on admission (ITQ)	21.5 (15-28.5)	20.5 (14-21)	0.384
Last known well time to hospital/groin puncture, min (ITQ)	1290 (775-1658)	728(416-1011)	0.069
Wake up stroke, no. (%)	6 (50.0%)	4 (50.0%)	1
Past Medical History, no. (%)			
Hypertension	8 (66.7%)	2 (25.0%)	0.17
Hyperlipidemia	9 (75.0%)	1 (12.5%)	0.02
Diabetes	7 (58.3%)	5 (62.5%)	1
Prior Stroke/TIA	4 (33.3%)	0 (0.0%)	0.117
Atrial Fibrillation	2 (16.7%)	4 (50.0%)	0.161
Peripheral Vascular Disease	0 (0.0%)	1 (12.5%)	0.4
TICI Score \geq 2B (N=8), no. (%)	-	6 (75%)	-
	5 (41.7%)	4 (50.0%)	1

ICH on follow up imaging,
no. (%)

Symptomatic ICH no. (%)	0	0	
Fazekas Score ≥ 1 (N=6), no. (%)	1 (25%)	1 (50%)	1
90-day mRS (mRS >2) (N=15), no. (%)	9 (90.0%)	6 (85.7%)	1
Comfort Care, no. (%)	8 (66.7%)	5 (62.5%)	1
Mortality 90-day mRS=6, no (%)	6 (50%)	6 (75%)	0.373

Keywords: Acute Ischemic Stroke Intervention, Aspects, Acute Stroke, Endovascular Therapy

Financial Disclosures: The authors had no disclosures.

Grant Support: None.

Poster

Mechanical thrombectomy in patients on warfarin with a therapeutic international normalized ratio

Vera Sharashidze, MD¹, Vasu Saini, MD¹, Amer Malik, MD¹, Seemant Chaturvedi, MD², Dileep Yavagal, MD¹

¹University of Miami Miller School of Medicine, Miami, Florida, United States of America; ²University of Maryland, Baltimore, United States of America

Introduction:

There is limited data on risks and benefits in patients who undergo mechanical thrombectomy (MT) for acute ischemic stroke (AIS) in the setting of therapeutic international normalized ratio (INR).

Methods:

A single-center retrospective study of consecutive AIS patients from February 2015 to September 2018 who underwent MT in the setting of therapeutic INR ≥ 2.0 on warfarin. Baseline characteristics, procedural details, safety, and functional outcomes on discharge were assessed.

Results:

Among 347 patients who underwent MT, 24 (7%) were on warfarin. 8/24 (33%) had therapeutic INR. The mean \pm SD age of the patients was 63 \pm 12 years, the median pre-thrombectomy NIH Stroke Scale score was 16 (IQR 5.25-17.75). Severe left ventricle hypokinesia or akinesia was noted in 5/8 patients. Successful recanalization (TICI $\geq 2b$) was achieved in 6/8 (75%) patients. 4/8 (50%) achieved TICI 3 recanalization and first-pass success was documented in 6/8 (75%) cases. Stent retriever only was used in 5/8 patients, Solubra technique was used for 2/8 and ADAPT technique for 1/8 patients. Symptomatic (post-MT NIHSS worsening ≥ 4 points) hemorrhagic transformation was noted in 1/8 (12.5%) patients. Modified rankin scale of ≤ 3 on discharge was achieved in 5 patients (62.5%). Mortality rate was 25% (2/8 patients).

Conclusions:

Patients with therapeutic INR ≥ 2.0 undergoing MT achieved favorable procedural and functional outcomes. Study limitations include small sample size and retrospective nature of the analysis, however, further prospective study is warranted.

Keywords: Angiographic Technology, Acute Stroke, Endovascular

Financial Disclosures: The authors had no disclosures.

Grant Support: None.

Poster

Aspiration Via 0.088"-Caliber Catheters is Feasible in Acute Middle Cerebral Artery Stroke: Initial Human Experience

Stavros Matsoukas, Dr.¹, Devin Bageac, Dr.¹, Tomoyoshi Shigematsu, Dr.¹, J Mocco, Dr.¹, Reade De Leacy, Dr.¹, Hazem Shoirah, Dr.¹, Shahram Majidi, Dr.¹, Johanna Fifi, Dr.¹

¹*Department of Neurosurgery, Icahn School of Medicine at Mount Sinai, New York City, New York, United States of America*

Introduction:

Stroke thrombectomy with larger bore aspiration catheters has been shown to provide faster treatment times and improved recanalization grades. Catheters with up to 0.072" internal diameter (ID) have achieved FDA approval with the indication for aspiration in acute stroke. Experimentally, and as a physical principal, increasing ID results in higher aspiration force and ability to completely ingest thrombus. However, development of intracranially trackable, larger caliber catheters has been challenging. We report the initial human experience of 0.088" ID catheters advanced into the middle cerebral artery (MCA) for clot aspiration in acute stroke.

Methods:

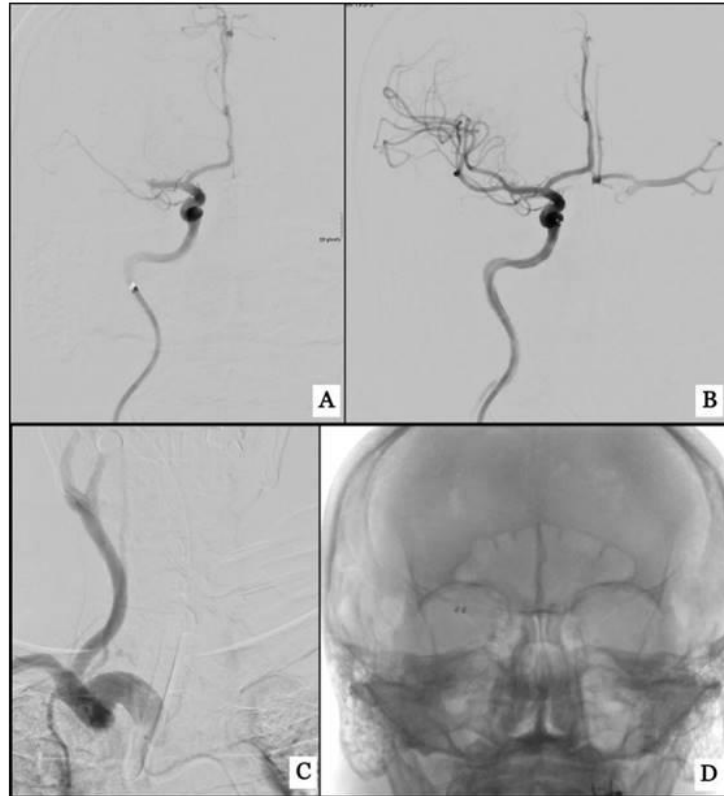
This is a single institution, first experience, consecutive case series of aspiration in the MCA M1 segment and petrous Internal Carotid Artery (ICA) via an 0.088" ID aspiration catheter. We retrospectively assessed cases treated with the Zoom™ 88 Large Distal Platform (Zoom 88) catheter (Imperative Care, Inc). With 110 cm of length and 18 cm of distal flexibility, Zoom 88 is designed for intracranial access. We selected those cases where the Zoom 88 was used, off label, directly for aspiration. Pertinent endpoints were intraarterial access (IA) to first clot touch time, IA to recanalization time, final TIC1 recanalization grade, number of passes needed, postoperative NIHSS, and discharge NIHSS and mRS. Occlusion location and final TIC1 grade were adjudicated by independent observers.

Results:

Seven patients aged 20-86 years (mean 68.5) were treated with aspiration via the Zoom 88 for M1 segment petrous ICA occlusion. The initial NIHSS scores ranged between 9-26 and ASPECTS scores ranged between 8-10. Recorded IA-to-first touch of the clot time ranged between 7-26 minutes and IA-to-complete recanalization times were 14-30 minutes and 97 minutes for a complicated case. Full recanalization (TIC1 score of 3) was achieved on the first pass in all 6 patients. One case was complicated with distal M2 embolism requiring multiple unsuccessful passes. Figure 1 contains images of a representative case. No complications were noted on final angiography or CT imaging post procedure in the six cases. All patients had immediate post-operative improvement and uneventful hospital courses. Already discharged patients' NIHSSs were 0-1.

Conclusions:

Aspiration of M1 segment thrombus in acute stroke is feasible, fast, and safe in this small initial patient series. This provides initial evidence that rapid recanalization times and high complete recanalization rates can be achieved with larger ID, trackable catheters designed for intracranial use. Larger studies are needed to confirm efficacy and safety across a broad population.



Legend: A: Right middle cerebral artery mid-M1 segment occlusion before recanalization, B: TICI 3 Recanalization Grade after first pass aspiration with a 0.088" lumen catheter, C: Type II aortic arch of the same patient with moderate tortuosity of the cervical vessels, D: 0.088" lumen catheter over a 0.071" lumen catheter in the mid-M1 segment of the right middle cerebral artery.

Keywords: Access Catheters, Acute Ischemic Stroke Intervention, Mechanical Thrombectomy, New Technique, Neurointerventional Education

Financial Disclosures: The authors had no disclosures.

Grant Support: None.

Poster

Endovascular Therapy of Anterior Circulation Tandem Occlusions: Pooled Analysis from the TITAN and ETIS Registries

Mohammad Anadani, MD¹, Gaultier Marnat, MD², Arturo Consoli, MD MSc³, Panagiotis Papanagiotou, MD PhD⁴, Raul G Nogueira, MD⁵, Adnan Siddiqui, MD PhD⁶, Marc Ribo, MD PhD⁷, Maeva Kyheng, BST⁸, Julien, Labreuche, BST⁹, Adam de Havenon, MD¹⁰, Benjamin Gory, MD PhD¹¹

¹Washington University in St. Louis, St. Louis, Missouri, United States of America; ²University Hospital of Bordeaux, Bordeaux, France; ³Foch Hospital, Suresnes, France; ⁴Hospital Bremen-Mitte, Bermen, Germany; ⁵Emory University/Grady Hospital, Atlanta, United States of America; ⁶State University of New York, Buffalo, United States of America; ⁷Hospital Vall D'Hebron, Barcelona, Spain; ⁸CHU, Lille, France; ⁹University Lille, Lille, France; ¹⁰University of Utah, salt lake, Utah, United States of America; ¹¹CHU, Nancy, France

Introduction:

Endovascular therapy (EVT) for anterior tandem occlusion (TO) strokes is effective and safe treatment. The best treatment approach for cervical internal carotid lesion (c-ICA) is still unknown. In this study, we aimed to compare functional and safety outcomes between different treatment approaches for c-ICA during EVT for acute ischemic stroke (AIS) due to TO.

Methods:

This is a pooled analysis of the TITAN (Thrombectomy In TANdem lesions) and ETIS (Endovascular Treatment in Ischemic Stroke) registries. Patients were divided based on c-ICA lesion treatment into EVT with carotid artery stenting group (EVT/CAS+) and EVT without carotid stenting (EVT/CAS-). Outcomes were compared between the two treatment groups using Inverse probability treatment weighting (IPTW) propensity score methods.

Results:

A total of 603 patients were included, of whom 341 treated with MT/CAS+. MT/CAS+ group had higher rate of favorable outcome (modified Rankin Scale [mRS]0-2) (57% vs. 45%) and excellent outcome (mRS 0-1) (40% vs. 27%) compared to MT/CAS- group. In IPTW propensity score analysis, MT/CAS+ group had higher odds of favorable outcome (OR=1.09; 95% CI: 1.01 to 1.19) and successful reperfusion (OR=1.19; 95%CI, 1.11 to 1.27). However, MT/CAS+ group also had higher odds of any intracerebral hemorrhage (OR=1.10; 95%, 1.02 to 1.19), but not higher rate of symptomatic intracerebral hemorrhage or parenchymal hematoma type 2. Subgroup analysis demonstrated heterogeneity according to lesion type (atherosclerosis vs. dissection; P for heterogeneity=0.01) and baseline NIHSS (<10 vs. ≥10; P for heterogeneity=0.018).

Conclusions:

This is the largest study of patients with tandem occlusion. In this study, patients treated with EVT/CAS+ had higher odds of a favorable outcome and successful recanalization compared to patients treated with EVT/CAS-, despite higher odds of intracerebral hemorrhage.

Keywords: Acute Ischemic Stroke Intervention, Carotid Stenting And Angioplasty

Financial Disclosures: The authors had no disclosures.

Grant Support: None.

Poster

Aspiration Thrombectomy of M2 Occlusion: Subset Analysis of the COMPLETE Study

Johanna T Fifi, MD FAHA FSVIN¹, Ameer E Hassan, DO FAHA FSVIN², Osama O Zaidat, MD MS FAHA FAAN FSVIN³

¹*Icahn School of Medicine at Mount Sinai, New York, New York, United States of America;* ²*University of Texas Rio Grande Valley at Valley Baptist Medical Center, Harlingen, Texas, United States of America;*

³*Mercy Health St. Vincent Medical Center, Toledo, Ohio, United States of America*

Introduction:

Although the benefits of thrombectomy for treating acute ischemic stroke (AIS) caused by proximal large vessel occlusion have been established, few studies have evaluated aspiration thrombectomy of more distal occlusions. The objective of this study was to evaluate the effectiveness and safety of aspiration thrombectomy in patients with M2 middle cerebral artery (MCA) occlusion.

Methods:

This is a subset analysis of a global prospective multicenter registry (COMPLETE) that enrolled adults with large vessel occlusion AIS and a pre-stroke modified Rankin Scale (mRS) score of 0-1 who underwent aspiration thrombectomy with the Penumbra System. The primary efficacy endpoints were post-procedure angiographic revascularization, as defined by a modified thrombolysis in cerebral infarction (mTICI) score of $\geq 2b$, and good 90-day functional outcome, as defined by an mRS of 0-2. The primary safety endpoint was 90-day all-cause mortality. Imaging endpoints were assessed by a core lab and safety endpoints were adjudicated by independent medical reviewers.

Results:

Out of 650 patients enrolled in the COMPLETE study, 113 patients had M2 MCA as the primary occlusion. Average patient age was 71.1 years (SD 14.0) and 60 (53.1%) patients were female. Median time from onset of symptoms to hospital admission was 177.5 minutes (IQR 70.5-343.5). The median Alberta Stroke Program Early CT score (ASPECTS) was 9 (IQR 8-10) and the median National Institutes of Health Stroke Scale (NIHSS) score was 10 (IQR 6-16). The frontline procedure was aspiration thrombectomy alone in 60.2% (68/113) of cases and was aspiration thrombectomy plus stent retriever in 39.8% (45/113) of cases.

Successful revascularization (mTICI $\geq 2b$) was achieved in 79.6% (90/113) of patients post-procedure and in 49.6% (56/113) of patients after first pass. Median time from puncture to revascularization or final angiogram was 31 minutes (IQR 19-45.5). Good functional outcome at 90 days (mRS of 0-2) was achieved in 72.5% (79/109) of patients. The rate of all-cause mortality at 90 days was 8.8% (10/113) patients. Device-related serious adverse events (SAEs) occurred in 0.9% (1/113) of patients within 24 hours and in 1.8% (2/113) of patients overall. Procedure-related SAEs occurred in 3.5% (4/113) of patients within 24 hours and in 5.3% (6/113) of patients overall. Embolization in previously uninvolved (or new) territories at the end of the procedure (ENT) occurred in 3.5% (4/113) of patients. Symptomatic intracranial hemorrhage (ICH) within 24 hours occurred in 3.5% (4/113) of patients.

Conclusions:

Aspiration thrombectomy performed in the M2 MCA location appears to be safe and effective.

	Entire cohort (N = 650)	M2 occlusion (N = 113)
Baseline data		
Age, years (mean (SD))	68.4 (14.2)	71.1 (14.0)
Female	54.0%	53.1%
Medical history		
Atherosclerosis	11.1%	14.2%
Atrial fibrillation	33.4%	40.7%
Diabetes	23.7%	24.8%
Hypertension	72.0%	74.3%
Time from onset to hospital admission, hrs (median [IQR])	3.2 [1.4-6.3] (N = 631)	3.0 [1.2-5.7] (N = 108)
ASPECTS, per imaging core lab (median [IQR])	8 [7-9] (N = 597)	9 [8-10] (N = 112)
NHSS score (median [IQR])	15 [9-20] (N = 648)	10 [6-16]
Pre-stroke mRS		
0	72.8%	73.5%
1	27.2%	26.5%
IV tPA pre-procedure	49.2%	57.5%
Procedural data		
Frontline procedure		
Aspiration thrombectomy alone	62.9%	60.2%
Aspiration thrombectomy plus 3D Revascularization Device	35.2%	38.1%
Time from puncture to revascularization or final angiogram, min (median [IQR])	27 [16-44] (N = 646)	31 [19-45.5] (N = 112)
Primary endpoints		
Efficacy		
mTICI 2b-3 post-procedure*	87.8% (571/650)	79.6% (90/113)
mRS 0-2 at 90 days	55.8% (342/613)	72.5% (79/109)
Safety		
All-cause mortality at 90 days	15.5% (101/650)	8.8% (10/113)
Other endpoints		
mTICI 2b-3 post-first pass*	47.8% (311/650)	49.6% (56/113)
Device-related SAEs, ≤ 24 hrs [†]	0.6% (4/650)	0.9% (1/113)
Device-related SAEs, overall [†]	1.1% (7/650)	1.8% (2/113)
Procedure-related SAEs, ≤ 24 hrs [‡]	5.8% (38/650)	3.5% (4/113)
Procedure-related SAEs, overall [‡]	7.7% (50/650)	5.3% (6/113)
ENT at end of procedure*	2.8% (18/650)	3.5% (4/113)
Symptomatic ICH at 24 hrs [†]	3.8% (25/650)	3.5% (4/113)
Vessel perforation	0.3% (2/650)	0.9% (1/113)
Vessel dissection	0.9% (6/650)	0.0% (0/113)

*Per imaging core lab

[†]Per independent medical reviewer

[‡]Per independent medical reviewer else PI

Keywords: Acute Ischemic Stroke Intervention, Clinical Trial, MCA, Mechanical Thrombectomy, Penumbra

Financial Disclosures: Grant/research support: Microvention, Penumbra, Stryker. Consultant: Microvention, Stryker. Other financial or material support: Ownership interest: Imperative Care

Grant Support: None.

Poster

Safety and Efficacy of Large-Bore Reperfusion Catheters for Acute Stroke Thrombectomy in the COMPLETE Registry

Ameer E Hassan, DO FAHA FSVIN¹, Johanna T Fifi, MD FAHA FSVIN², Osama O Zaidat, MD FAHA FAAN FSVIN³

¹University of Texas Rio Grande Valley at Valley Baptist Medical Center, Harlingen, Texas, United States of America; ²Icahn School of Medicine at Mount Sinai, New York, United States of America; ³Mercy Health St. Vincent Medical Center, Alameda, United States of America

Introduction:

To report on the real-world experience using the Penumbra JET 7 (JET 7), a new generation larger bore reperfusion catheter, in patients with acute ischemic stroke due to large vessel occlusions (LVO).

Methods:

Baseline Characteristics	JET 7 ADAPT (N=155)	Other-PS (N=495)	p-value
NIHSS, median [IQR]	16 [IQR 10-21]	14 [IQR 9-19]	0.027
ASPECTS, median [IQR]	8 [IQR 7-9]	8 [IQR 7-9]	0.035
IV tPA administered, %	46.5%	50.1%	0.43
Primary Occlusion Location, % (n/N)			
ICA/ICA-T	17.4% (27/155)	17.4% (86/495)	0.99
MCA M1	64.5% (100/155)	52.3% (259/495)	0.0077
MCA M2	10.3% (16/155)	19.6% (97/495)	0.0078
Posterior	7.7% (12/155)	7.9% (39/495)	0.96
Study Endpoints, % (n/N)	JET 7 ADAPT (N=155)	Other-PS (N=495)	p-value
Reperfusion (mTICI 2b-3) post-frontline (first-pass success), % (n/N)	63.2% (98/155)	54.8% (270/493)	0.064
Reperfusion (mTICI 2b-3) post-procedure, % (n/N)	89.7% (139/155)	87.3% (432/495)	0.42
Procedure completed in one pass, % (n/N)	57.4% (89/155)	44.8% (222/495)	0.0063
90-day mRS 0-2, % (n/N)	62.2% (89/143)	53.8% (253/470)	0.076
90-day all-cause mortality, % (n/N)	15.5% (24/155)	15.6% (77/495)	0.98
Time from Puncture to mTICI 2b-3 else Final Angiogram Core Lab else PI, minutes, median [IQR]	19.0 [13.0, 31.0]	28.0 [17.0, 43.0]	0.001
Device-related SAE within 24 hours, % (n/N)	1.3% (2/155)	0.4% (2/495)	0.22

Procedure-related SAE within 24 hours, % (n/N)	7.1% (11/155)	5.5% (27/495)	0.45
Symptomatic ICH, % (n/N)	3.9% (6/155)	3.8% (19/495)	0.99
Embolization into new territory, % (n/N)	3.9% (6/155)	2.4% (12/495)	0.34
Vessel perforation, % (n/N)	0.6% (1/155)	0.2% (1/495)	0.38
Vessel dissection, % (n/N)	0.6% (1/155)	1.0% (5/495)	0.68

COMPLETE is an international, multi-center, prospective, single-arm registry, and included patients with intracranial LVO and planned frontline treatment with the Penumbra System (PS). We compared cases that used frontline ADAPT with JET 7 (inner diameter 0.072 inches, recently launched in the U.S.), with those that did not (other-PS) including ADAPT and ADAPT with 3D techniques. Primary endpoints included post-procedural revascularization success (mTICI \geq 2b), good functional outcome (mRS 0-2), and all-cause mortality at 90 days. Secondary endpoints included time to revascularization, and device- and procedure-related complications. This study was core-lab adjudicated and safety events reviewed by external medical reviewers.

Results:

Among 650 subjects included in the study, 155 were frontline JET 7 ADAPT cases (mean age 67.1 \pm 14.2; 47.1% female) and 495 were frontline other-PS cases (mean age 68.8 \pm 14.2; 56.2% female). Baseline characteristics and study endpoints are reported in the table. The rate of procedures completed in a single pass was significantly higher in the JET 7 vs other-PS group (p=0.0063), and the median puncture-to-reperfusion time was significantly faster with JET 7 compared with other-PS (p=0.001). There were no significant differences in other endpoints, although rates of first-pass success (63.2% vs 54.8%) and good functional outcome (62.2% vs 53.8%) were numerically higher in the JET 7 group. Complication rates did not differ between groups (JET 7, other-PS) for symptomatic ICH (3.9%, 3.8%), embolization into new territory (3.9%, 2.4%), vessel perforation (0.6%, 0.2%), and vessel dissection (0.6%, 1.0%).

Conclusions:

Aspiration thrombectomy with the new Penumbra JET 7 catheter yielded faster procedure times and may have higher rates of successful first pass revascularization, as compared with other smaller-size catheters.

Keywords: Acute Ischemic Stroke Intervention, Revascularization, Clinical Trial, Endovascular Therapy, Penumbra

Financial Disclosures: Consultant: GE Healthcare, Genentech, Medtronic, Microvention, Penumbra, Stryker Speakers bureau: GE Healthcare, Genentech, Medtronic, Microvention, Penumbra, Stryker

Grant Support: None.

Poster

First Experience In Retrieval Of Fibrin Rich Clots With Cerenovus Nimbus Retriever

Hannes Nordmeyer, MD¹, René Chapot, Prof², John Thornton, MD³, Timo H Phung, MD⁴, Jack Alderson, MD³, Pascal J Mosimann, PhD², Tommy Andersson, PhD⁵, Sarah Power, MD³, Alan O'Hare, MD³

¹radprax Neurocenter, Solingen, Germany; ²Interventional Neuroradiology, Alfried Krupp Foundation, Essen, Germany; ³Interventional Neuroradiology, Beaumont Hospital, Dublin, Ireland; ⁴Interventional Neuroradiology, radprax Neurocenter, Solingen, Germany; ⁵Interventional Neuroradiology, Karolinska Sjukhus, Stockholm, Sweden

Introduction:

Mechanical thrombectomy represents the most effective treatment in acute large cerebral vessel occlusion with overall high success rates. Difficult to remove white clots still account for a substantial percentage of technical failure. With the Cerenovus Nimbus retriever a new device architecture aims at succeeding in difficult situations by entangling the most intractable clots with a proximal spiral portion followed by a distal regular mesh.

Methods:

Nimbus was used as first or second line device in high volume neurocenters during the early series. Numbers of passes, timelines, macroscopic clot description and all clinical as well as procedural data were prospectively recorded. Clots were assembled and shipped to the central lab (NUI, Galway) and examined using a battery of histological tests, including Martius Scarlet Blue. Due to the COVID-19 pandemic, clot analysis was interrupted but recently resumed.

Results:

30 consecutive patients were treated in six centers. Nimbus was used as 1st and 2nd line device in 8 and 22 patients respectively. Overall success rate was 79% with 88% and 73% in 1st and 2nd line cases respectively. Decision to utilize Nimbus GCE as a primary device was left to the interventionalists discretion. In successful cases (TICI 2b-3) Nimbus was used for the last pass in 87%. Reasons for failure were either Calcification (n=2), underlying stenosis (n=2), severe M1 elongation (n=1) or unknown (n=2). In 5 early evaluation cases 23 clots were histologically analyzed. Fibrin and platelets represented 77% of clot components, collagen/calcification accounted for 8%, whereas the remaining 15% were red and white blood cells.

Conclusions:

Preliminary data from a series of markedly fibrin and platelet rich thrombi showed safety and high efficacy for the Nimbus retriever in typically challenging situations.

Keywords: Mechanical Thrombectomy, Ischemic Stroke, Stent retriever, New Technique, New Innovation

Financial Disclosures: The authors had no disclosures.

Grant Support: None.

Poster

Association Of Pre-mechanical Thrombectomy Collateral Scores With Functional Outcome

Taha Nisar, MBBS¹, Osama Abu-Hadid, MD¹, Toluwalase Tofade, MD¹, Muhammad Zeeshan Memon, MBBS¹, Amit Singla, MBBS¹, Priyank Khandelwal, MBBS¹

¹Rutgers New Jersey Medical School, Newark, New Jersey, United States of America

Introduction:

Cerebral collateral circulation refers to the anastomoses that reroute the blood flow to the ischemic penumbra in the event of a large vessel occlusion (LVO). We aim to determine if pre-mechanical-thrombectomy (MT) collateral scores are associated with a good functional outcome, lower risk of symptomatic intracerebral hemorrhage (sICH), and infarct volume after MT.

Methods:

We performed a retrospective chart review of patients who underwent MT for anterior circulation LVO at a comprehensive stroke center from 7/2014 to 5/2020. The collateral grading scales of Miteff >2, Mass ≥3, and modified-Tan >50% were used to designate good collaterals on the pre-MT CT Angiogram. A binary logistic regression analysis was performed, controlling for age, sex, pre-treatment-NIHSS, ASPECTS ≥6, TICl score ≥2b, onset to recanalization time, and administration of intravenous-alteplase (IV-rtPA), with the pre-MT collateral grading scores as predictors. The primary outcome was good functional outcome (3-month mRS ≤1). The secondary outcomes were sICH (ECASS-II criteria) and infarct volume on follow-up CT Head.

Results:

173 patients met our inclusion criteria. The mean age was 64.29±14.08 years. 34 (19.65%) patients had 3-month mRS ≤1. 11 (6.36%) patients developed sICH. The pre-MT collateral grading score of Miteff >2 was associated with mRS ≤1 (36.36% vs. 13.95%; OR, 0.37; 95% CI, 0.37-0.87; P 0.022), and a larger infarct volume (92.12±127.95mls vs. 70.63±78.09mls; OR, 1.01; 95% CI, 1.01-1.01; P 0.01) but not with sICH (9.09% vs. 5.47%; OR, 1.95; 95% CI, 0.52-7.33; P 0.325). The pre-MT score of Mass ≥3 was associated with a smaller infarct volume (39.83±55.01mls vs. 91.08±101.77mls; OR, 1; 95% CI, 0.99-1.00; P 0.008) but not with mRS ≤1 (26.53% vs. 16.93%; OR, 0.67; 95% CI, 0.28-1.61; P 0.363) or sICH (2.04% vs. 8.13%; OR, 0.15; 95% CI, 0.02-1.35; P 0.089). The pre-MT score of modified-Tan was not associated with any outcome measures: mRS ≤1 (22.78% vs. 15.28%; OR, 0.69; 95% CI, 0.29-1.67; P 0.409), sICH (8% vs. 4.17%; OR, 1.82; 95% CI, 0.45-7.34; P 0.406) and infarct volume (72.48±76.41mls vs. 78.74±104.24mls; OR, 1.01; 95% CI, 1.-1.01; P 0.141).

Conclusions:

Our study demonstrates an association between pre-MT score of Miteff >2 and a good functional outcome at 3 months.

Keywords: Collateral

Financial Disclosures: The authors had no disclosures.

Grant Support: None.

Poster

Infarct Growth Rate is an Independent Predictor of Poor Outcome After Successful Reperfusion Mechanical Thrombectomy

Darko Quispe-Orozco, Dr.¹, Darko Quispe-Orozco, Dr.¹, Joel M Sequeiros, Dr.², Cynthia B Zevallos, Dr.¹, Mudassir Farooqui, Dr.¹, Andres Dajles, Mr.¹, Alan Mendez-Ruiz, Dr.¹, Cindy K Nguyen, Mrs.³, Jessica Kobsa, Mrs.³, Ayush Prasad, Mr.³, Krithika Peshwe, Mrs.³, Sreeja Kodali, Mrs.³, Nils Petersen, Dr.³, Santiago Ortega-Gutierrez, Dr.¹

¹University of Iowa Hospitals and Clinics, Iowa city, Iowa, United States of America; ²University of Tennessee Health Science Center, Memphis, Tennessee, United States of America; ³Yale New Haven Hospital, New Haven, Connecticut, United States of America

Introduction:

Despite treatment with mechanical thrombectomy (MT), some patients fail to regain functional independence at 90 days. The growth of the ischemic core varies across patients, and likely reflects differences in collateral flow and ischemic tolerance. In this study, we sought establish the optimal infarct growth rate (IGR) threshold to differentiate between slow and fast progressors and assess its ability to predict poor outcome.

Methods:

We retrospectively identified patients with anterior large-vessel occlusion (LVO) stroke with successful MT (mTICI \geq 2b) at two comprehensive stroke centers. Final infarct volume (FIV) was calculated from post-MT Diffusion-weighted MRI. Assuming relative stability of the FIV after successful reperfusion, we defined IGR as [FIV (ml)] / [Time from stroke onset to reperfusion (hours)]. Good clinical outcome was defined as a modified Rankin scale score (mRS) \leq 2. We used Receiver Operating Characteristics (ROC) analysis to calculate the optimal IGR threshold with high specificity for predicting a poor outcome. Multivariate logistic regression analysis was performed to evaluate the association of fast progressors (IGR \geq 7.14 ml/h) on the poor functional outcome and mortality.

Results:

Of the 212 patients (age 68 ± 15 , 51% female, NIHSS 15 ± 7) included, 110 (51.8%) patients had a poor outcome. The median IGR was significantly higher in patients with poor compared to good outcome (7 ml/h vs. 3.1 ml/h, $p < 0.001$). An IGR \geq 7.14 ml/h showed a sensitivity of 0.49 and a specificity of 0.7 to predict a poor outcome with an area under the ROC curve of 0.65 (95% CI, 0.58-0.73). IGR \geq 7.14 ml/h was an independent predictor of poor outcome (OR 2.2, 95% CI 1.1-4.6, $p = 0.036$) and mortality (OR 4.2, 95% CI 1.8-10.6, $p = 0.001$) after adjusting for age, sex, atrial fibrillation, NIHSS and ASPECTS. Ordinal regression showed that the odds of having better outcomes decrease 60% in fast progressors (OR 0.40, 95% CI: 0.22-0.70, $p = 0.001$) after adjusting for age, sex, atrial fibrillation, NIHSS, and ASPECTS.

Conclusions:

IGR is an independent predictor of poor outcome and mortality in patients with successful MT. Early identification of this population might help to institute therapeutic strategies of accelerating reperfusion and slowing the IGR.

Keywords: Acute Ischemic Stroke Intervention, Acute Stroke, Ct Perfusion, Imaging, Mechanical Thrombectomy

Financial Disclosures: The authors had no disclosures.

Grant Support: None.

Poster

Characterization of Infarct Growth Rate Patterns in Patients with Large-Vessel Occlusion Stroke Undergoing Mechanical Thrombectomy.

Darko Quispe-Orozco, Dr.¹, Darko Quispe-Orozco, Dr.¹, Cynthia B Zevallos, Dr.¹, Mudassir Farooqui, Dr.¹, Andres Dajles, Mr.¹, Alan Mendez-Ruiz, Dr.¹, Cindy K Nguyen, Mrs.², Jessica Kobsa, Mrs.², Ayush Prasad, Mr.², Krithika Peshwe, Mrs.², Sreeja Kodali, Mrs.², Nils Petersen, Dr.², Santiago Ortega-Gutierrez, Dr.¹

¹University of Iowa Hospitals and Clinics, Iowa city, Iowa, United States of America; ²Yale New Haven Hospital, New Haven, Connecticut, United States of America

Introduction:

Infarct growth is affected by the collateral blood supply and ischemic tolerance and thus unlikely linear. This study aimed to better characterize infarct growth rates (IGR) after large-vessel occlusion (LVO) stroke.

Methods:

We retrospectively identified patients with anterior LVO stroke who underwent mechanical thrombectomy (MT) at two comprehensive stroke centers. Core infarct volumes at presentation (CBF<30%) were estimated using RAPID software. Final infarct volume (FIV) was measured on post-MT MRI. We estimated IGR during two intervals: IGR 1 defined as CBF<30% (ml) / Time from onset to CTP (hours); and IGR 2 as [FIV – CBF<30% (ml)] / Time from CTP to reperfusion (hours). To calculate IGR 2, we only analyzed patients with successful MT (mTICI ≥ 2b) assuming no significant infarct growth after reperfusion. Functional outcome was assessed using the modified Rankin scale (mRS) at 90 days. We performed the Receiver-operating characteristic (ROC) analysis for each interval to best classify patients into slow and fast progressors.

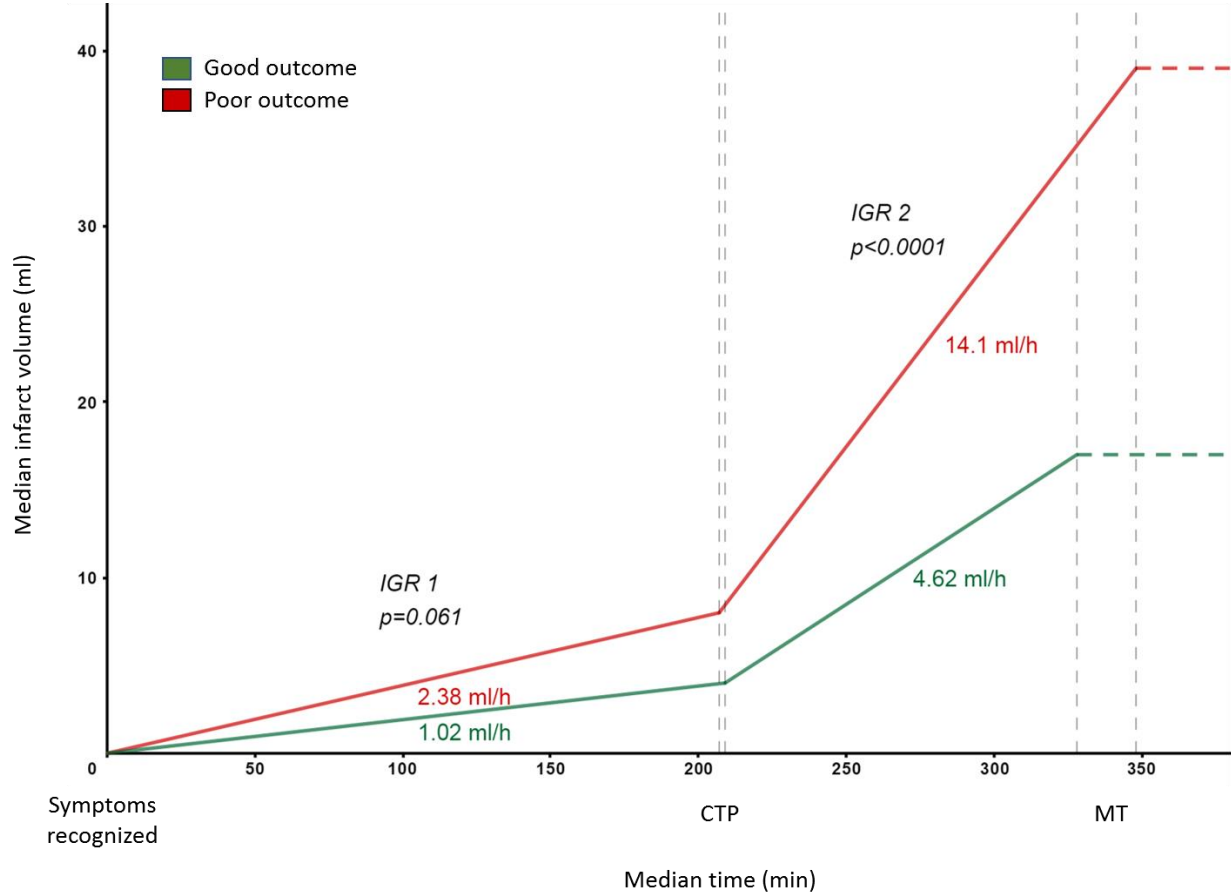
Results:

Of the 361 patients (age 68 ± 15, 55% female, NIHSS 14 ± 6) included in the analysis, 282 (78.1%) had successful reperfusion, and 150 (41.6%) achieved a good outcome (mRS ≤2). IGR showed an exponential growth pattern (Figure 1). There was no significant difference in the median IGR 1 between the poor and good outcome groups (2.3 vs. 1 ml, p=0.061). The median IGR 2 in patients with poor outcome was significantly higher when compared to those in the good outcome group (IGR 14.1ml/h vs. 4.62ml/h, p<0.0001). IGR 2 ≥ 12.2ml/h had a sensitivity of 0.56 and a specificity of 0.77 (AUC 0.67) for predicting poor outcome.

Conclusions:

We identified an exponential infarct growth pattern after LVO stroke that differs in relation to outcome. High IGR in the interval from CTP to reperfusion is associated with worse outcomes, emphasizing the importance of future research into therapeutic approaches to slow down infarct progression.

Figure 1. Infarct Growth Rate Patterns and Functional Outcome



Keywords: Acute Ischemic Stroke Intervention, Ct Perfusion, Imaging, Acute Stroke, Cerebral Physiology

Financial Disclosures: The authors had no disclosures.

Grant Support: None.

Poster

Region-Specific Infarct Topography After Endovascular Thrombectomy and Long-Term Outcomes

Robert W Regenhardt, MD, PhD¹, Anna K Bonkhoff, MD¹, Martin Bretzner, MD¹, Mark R Etherton, MD, PhD¹, Alvin S Das, MD¹, Naif M Alotaibi, MD¹, Justin E Vranic, MD¹, Christopher J Stapleton, MD¹, Aman B Patel, MD¹, Thabele M Leslie-Mazwi, MD¹, Natalia S Rost, MD, MPH¹

¹Massachusetts General Hospital, Boston, Massachusetts, United States of America

Introduction:

Endovascular thrombectomy (EVT) has revolutionized the care of large vessel occlusion (LVO) stroke patients. However, over half remain functionally disabled or die despite treatment. Understanding long-term outcomes may influence EVT selection, novel therapies, and prognostication. We sought to identify associations between outcomes and region-specific brain regions involved in acute infarcts after EVT.

Methods:

For consecutive LVO patients with post-EVT MRI, acute ischemic lesions were manually segmented from DWI and spatially normalized. Individual lesion volumes were automatically parcellated (atlas-defined 94 cortical regions, 14 subcortical nuclei, 20 white matter tracts) and then reduced to ten anatomically plausible lesion patterns using unsupervised dimensionality reduction techniques. Ninety-day modified Rankin Scale (mRS) was modeled via Bayesian regression, taking the ten lesion patterns as inputs and controlling for lesion size, age, sex, acute NIH Stroke Scale, alteplase, and TICl 2b-3 reperfusion.

Results:

We identified 153 LVO patients with mean age 68±15 years and 51% female. Median NIHSS was 16 (IQR 13-20), 56% received alteplase, and 84% achieved TICl2b-3. The lesion patterns predictive of 90-day mRS involved bilateral subcortical nuclei, pre- and postcentral gyri, insular and opercular cortex, as well as left-sided inferior frontal and angular gyri.

Conclusions:

These data describe the relative significance for outcomes of specific brain regions involved in infarcts on MRI after EVT. Future work in additional datasets is needed to confirm these findings.

Keywords: Endovascular Therapy, Mechanical Thrombectomy, Imaging, Ischemic Stroke, MRI

Financial Disclosures: The authors had no disclosures.

Grant Support: None.

Poster

Extended Stent Retriever Deployment with Eptifibatide for Intracranial large Vessel Occlusion due to Atherosclerotic Disease

Jeremy M Liff, Physician¹, David T Parrella, Physican¹, Karthikeyan Arcot, Physicain¹, Ambooj Tiwari, Physician¹, Omar Tanweer, Physicain¹, Ketevan Berekashvili, Physician¹, Miguel Litao, Physician¹, Jeffrey Farkas, Physician¹

¹*NYU Langone Medical Center Winthrop, Mineola, New York, United States of America*

Introduction:

Thrombectomy for Emergent Large Vessel Occlusion (ELVO) is often challenging when the occlusive etiology is in-situ rupture of an Intracranial Atherosclerotic Disease (ICAD) plaque. Additionally, acute re-occlusion following initial revascularization is often observed.

Previous reports have described advancements in balloon angioplasty and permanent stent placement as treatment for these more challenging scenarios.

We describe the successful treatment of ELVO due to in-situ plaque rupture using extended-time deployment of a retrievable stent combined with Eptifibatide administration; an alternative approach that does not involve permanent stent placement.

Methods:

An 86 year old woman with a history of ICAD had Aspirin discontinued for a spine injection three days prior to admission. She presented with fluctuating confusion, dysarthria, and right sided face and arm weakness. CT Angiogram showed left M1 occlusion and CT perfusion showed a large area of salvagable territory. Emergency Angiogram reconfirmed the occlusion and also demonstrated robust pial collaterals.

Emergency thrombectomy using the "Solumbra" technique was performed; a Solitaire 6x60mm retrievable stent was deployed for 5 minutes along with the concurrent use of a Penumbra .068 Aspiration catheter. Repeat imaging showed recanalization of the MCA occlusion. However, serial imaging over ten mintues showed progressive worsening of the luminal caliber to impending occlusion. Given known ICAD, a fluctuating syndrome with M1 occlusion, robust collaterals, and deterioration following initial successful pass, it was concluded that in-situ plaque rupture was the etiology of the patient's ELVO.

An intravenous Eptifibatide bolus (45mcg/kg) was given and continuous infusion (1 mcg/kg/min) was started.

Ten minutes following the start of the Eptifibatide infusion, the stent retriever was again deployed across the occlusion. Next an Eptifibatide bolus (45 mcg/kg) was injected via the aspiration catheter into the origin of the left MCA and through the stent retriever. After fifteen minutes, the aspiration catheter was advanced over the proximal end of the stent retriever (Solumbra technique) and the construct was removed.

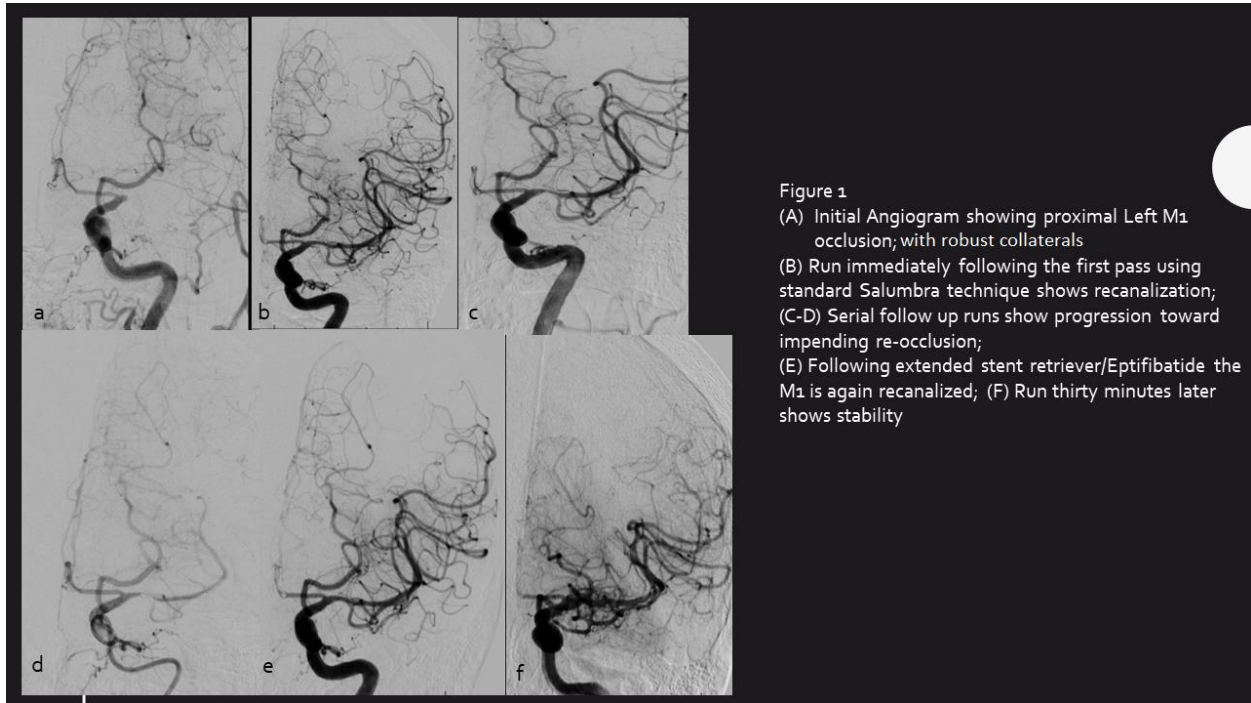
Results:

Angiography showed recanalization and continued patency on serial imaging over the next 30 minutes. The patient was loaded with clopidogrel 450mg and aspirin 81mg. Eptifibatide was discontinued 4 hours later.

She was discharged on dual anti-platelets and was symptom free at six months.

Conclusions:

Extended stent retriever deployment with Eptifibatide administration can treat ELVO due to atherosclerosis. The success of the technique is presumably related to the administration of a potent platelet inhibitor directed specifically to the lesion and aided by flow permitted by the angioplasty effect of the retrievable stent.



Keywords: Acute Ischemic Stroke Intervention, Mechanical Thrombectomy, New Technique, Intra-Arterial Therapy, Atherosclerosis

Financial Disclosures: The authors had no disclosures.

Grant Support: None.

Poster

Endovascular therapy of stroke patients with distal to proximal aspiration technique underflow arrest (DPAT-BG)

Atila O Ozdemir, NA¹, Ozlem Aykac, NA¹, Demet Bas, NA²

¹Eskisehir Osmangazi University, Eskisehir, Turkey; ²İzmir Tepecik Teaching Hospital, İzmir, Turkey

Introduction:

There is strong evidence suggesting the endovascular treatment for emergent large vessel occlusion (ELVO). Recently two randomized trials confirmed the non-inferiority of aspiration alone compared to stent retrievers. However, the role of balloon guiding catheter has not been established. Our goal is to determine the role of new aspiration technique underflow arrest on first pass recanalization, successful recanalization, 90-day functional outcome, complication rates

Methods:

We performed a retrospective analysis of a prospectively maintained Eskisehir Interventional Neurology Database on anterior cerebral circulation stroke thrombectomy cases with DPAT -BG technique as a first-line device from January 2018 to January 2020. First pass recanalization, successful recanalization, 90-day functional outcome, complication, and bleeding rates are reported. Technically, the thrombus was passed with microcatheter and micro-guidewire. The large bore-catheter was deployed over the microcatheter underflow arrest. The large-bore catheter was located distal to the occlusion. Afterward the large-bore catheter was withdrawn gently into the balloon guiding catheter underflow arrest.

Results:

Fifty patients were treated for DPAT-BG technique. The mean age was 55.9 ±15.6, and the median baseline NIHSS was 15, the median value of initial ASPECT score was 9.

Twenty-eight of 50 patients had internal carotid artery occlusion, and the rest (22/50) had proximal MCA occlusion. The first-pass recanalization rate of mTICI 2c/3 was 40% and the final TICI 2c/3 rate was 60%. The number of the median pass was two. The overall mRS 0–2 was 60 % (50/118) patients. One patient experienced new territorial embolism. No patient experienced type 2 parenchymal hematoma, and one patient had symptomatic type 1 intracerebral hematoma.

Conclusions:

In our experience, despite the higher rate of internal carotid occlusions compared to previous studies, DPAT-BG technique demonstrated high first pass and overall recanalization rates together higher with a good safety profile.

Details of endovascular treatment (50 patients)

Groin puncture-recanalization (TICI 2c-3), min	n (%) 42 (22.5-68.5)
Excellent final recanalization (mTICI 2c-3)	30 (60%)

First pass mTICI 2c-3 recanalization	20 (40%)
mTICI 2c-3 recanalization within 45 min	25 (50%)
Number of passes, median (IQR)	2 (1-4)
Symptomatic intracerebral hemorrhage	1 (2%)
Embolization to new territory	1 (2%)
Favorable outcome (mRS 0-2)	30 (60%)

Values are mean (SD), median (IQR), or n (%) as appropriate

Keywords: Acute Stroke, Endovascular Therapy, Mechanical Thrombectomy

Financial Disclosures: The authors had no disclosures.

Grant Support: None.

Poster

Tandem Occlusion in Anterior Circulation Stroke-a single centre experience

Apratim Chatterjee, Fellow¹, Anshu Mahajan, Consultant¹, Vineet Banga, Fellow¹, Gaurav Goel, Director and head¹

¹Medanta, The Medicity, Gurugram, India

Introduction:

Tandem occlusion in stroke as defined by proximal cervical internal carotid artery stenosis along with distal middle cerebral artery occlusion is a dilemma in stroke management because of difficulty in access of distal site of occlusion and inadequacy of IV thrombolytic agent to reach the distal occlusion past the proximal extracranial occlusion. There is no consensus as to the right approach in such cases.

Methods:

Current study aims to compare the antegrade vs retrograde approach in such cases and share experience of outcomes in such cases. A total of 13 cases were obtained over a span of two years in which patients presenting with acute stroke and having intracranial vessel occlusion of the anterior circulation and simultaneously having internal carotid artery stenosis or occlusion and underwent mechanical thrombectomy in the hospital were studied retrospectively from 1st April 2017- 30th April 2019. Clinical and angiographic data were retrospectively reviewed by two interventional neuroradiologists.

Results:

Antegrade approach was used in 3 patients and retrograde approach in rest of 9 patients. The door to recanalization at 3 months was much better in retrograde (75.3 min in antegrade vs 61 min in retrograde [p=0.19]) as compared to antegrade approach. 2 mortalities noted were due to symptomatic intracerebral bleed and sepsis. Factors like young age, better collaterals and low NIHSS were found added factors for a good prognosis. However in expert hands the 3 months mRS status did not vary much in between the two approaches(0.67 for antegrade and 1.7 for retrograde).The technical aspects for both the procedures were reviewed and retrograde approach often tended to avoid stenting in acute cases (only 4 cases had to be stented out of 13) thereby avoiding risk of bleeding due to antiplatelets.

Conclusions:

The study thus gives an outline into the approach which can be followed for better outcomes in such cases.

Keywords: Acute Ischemic Stroke Intervention, Acute Stroke, Mechanical Thrombectomy, Thrombosis, Endovascular Therapy

Financial Disclosures: The authors had no disclosures.

Grant Support: None.

Poster

Predictors of False-Positive Transfers Directly to Angio for Endovascular Thrombectomy

Keiko A Fukuda, MD¹, Whitfield Lewis, MD¹, Shashvat Desai, MD², Ashutosh P Jadhav, MD, PhD²

¹University of Pittsburgh Medical Center, Pittsburgh, Pennsylvania, United States of America; ²Barrow Neurological Institute, Phoenix, Arizona, United States of America

Introduction:

Bypassing the Emergency Department (ED) and going directly to the angiography suite (DTA) has been shown to reduce the door to groin puncture and door to recanalization time in patients undergoing endovascular thrombectomy (EVT) for acute ischemic stroke (AIS). Careful selection of patients is warranted to avoid patients unnecessarily undergoing a cerebral angiogram without the need for EVT, termed a false-positive DTA transfer. Patient characteristics associated with false-positive DTA transfers were elucidated in this study.

Methods:

This was a retrospective review of a prospectively maintained database. The study period ranged from January 2018 to August 2020. Patients presenting with AIS transferred from an outside hospital (OSH) to our Comprehensive Stroke Center (CSC) were initially separated into two groups. One group was comprised of patients that were sent DTA, bypassing the ED. The other group included all other patients. The DTA cohort was further divided into patients that successfully underwent EVT and patients who did not undergo EVT for varying reasons. Patients were further separated into those who did not undergo angiography all together. NIHSS upon presentation to the CSC and the use of IV-tPA were compared across these subpopulations.

Results:

A total of 1,216 patients with suspected LVO were transferred from outside hospitals to our CSC between January 2018 to August 2020. Of them, 24% (n=292) were transferred DTA. Mean age was 70 +/- 14 and 51% (n=150) were males. Median NIHSS score on arrival was 18 (14-23) and 44% (n=129) received IV-tPA. After DTA, 7.6% (n=20) did not undergo EVT. Of those, 35% (n=7) did not undergo digital subtraction angiography (DSA). Mean NIHSS on presentation was 15 for those who had DSA but no EVT, compared to a mean NIHSS of 3 for those who had no DSA. The most common reasons for false-positive DTA transfers were improvement in NIHSS (40%) and the absence of LVO on DSA (35%). The mean improvement in NIHSS was 4 among false-positive DTA transfers. Rates of IV-tPA administration were significantly higher amongst DTA patients not undergoing EVT (82% vs 44%, p=0.002). Mean NIHSS on admission to our CSC was significantly lower amongst DTA patients not receiving EVT (11 +/- 7 vs 19 +/- 7, p<0.01). Rate of false-positive DTA transfers reduce to 4.4% and 3.2% with an NIHSS score threshold of 10 and 15, respectively.

Conclusions:

Factors associated with an increased the chance of a false-positive DTA transfer were lower NIHSS on arrival, improvement in NIHSS following transfer, and tPA administration. These factors should be considered to improve selection and avoid unnecessary procedures. These factors could be used to develop a stratification score for DTA transfers in the future.

Keywords: Acute Ischemic Stroke Intervention, Endovascular Therapy, Door To Groin Puncture, Mechanical Thrombectomy, NIHSS

Financial Disclosures: The authors had no disclosures.

Grant Support: None.

Poster

Impact of Direct To Angio on Time to Reperfusion and Outcomes—Analysis of Trevo Retriever Registry

Ashutosh P Jadhav, MD PhD¹, Shashvat M Desai, MD¹, Tudor G Jovin, MD², Ronald Budzik, MD³, Antonin Krajina, MD⁴, Ali R Malek, MD⁵, Amrou Sarraj, MD⁶, Joey English, MD⁷, Ana Paula Narata, MD⁸, Muhammad Taqi, MD⁹, Timothy Miller, MD¹⁰, Thomas Grobelny, MD¹¹, Bruno Bartolini, MD¹², Blaise Baxter, MD¹³, David S Liebeskind, MD¹⁴, Raul G Nogueira, MD¹⁵, Rishi Gupta, MD¹⁶, Erol Veznedaroglu, MD¹⁷

¹Barrow Neurological Institute, Phoenix, Arizona, United States of America; ²Cooper University, Camden, New Jersey, United States of America; ³OhioHealth Neuroscience Center, Columbus, Ohio, United States of America; ⁴Simkova Hradec Kralove, Simkova, Czechia; ⁵Palm Beach Neuroscience Institute, West Palm Beach, Florida, United States of America; ⁶University of Texas Houston, Houston, Texas, United States of America; ⁷California Pacific Medical Center, San Francisco, California, United States of America; ⁸University Hospital of Tours, Tours, France; ⁹Los Robles Hospital and Medical Center, Thousand Oaks, California, United States of America; ¹⁰University of Maryland, Baltimore, Maryland, United States of America; ¹¹Advocate Neurovascular Center, Park Ridge, Illinois, United States of America; ¹²Lausanne University Hospital, Lausanne, France; ¹³Lehigh Valley Health Network, Allentown, Pennsylvania, United States of America; ¹⁴University of California Los Angeles, Los Angeles, California, United States of America; ¹⁵Emory University, Atlanta, Georgia, United States of America; ¹⁶Wellstar Medical Group, Atlanta, Georgia, United States of America; ¹⁷Drexel Neurosciences Institute, Philadelphia, Pennsylvania, United States of America

Introduction:

Direct to angio (DTA) is an emerging paradigm of triaging large vessel occlusion (LVO) stroke patients directly to the neuro-angiography suite at the thrombectomy capable center upon transfer from a referral facility. Bypassing the emergency department (and additional imaging) at the thrombectomy center may reduce time to recanalization and improve outcomes. We aim to analyze the impact of DTA on time to recanalization and safety and efficacy outcomes in the Trevo registry.

Methods:

Data were analyzed from the Trevo Retriever Registry – a prospective, open-label, consecutive enrollment, multi-center, international registry of patients undergoing neurothrombectomy with the Trevo device. Anterior circulation LVO (ICA, MCA-M1 and M2) strokes undergoing interfacility transfer were included. Patients who did not go undergo repeat imaging at the hub facility were included in the ‘direct to angio’ (DTA) group compared to patients who underwent repeat imaging via the ED (non-DTA). Univariate analyses and multivariable logistic regression were used to assess the impact of DTA on time metrics and outcomes post thrombectomy.

Results:

Of the 558 transfer patients in the Trevo registry, 37% (209) were in the DTA group. Age (68.4 + 14.3 vs. 66.3 + 14.7, p=.079), % male (46.9 vs. 48.1, p=.78), baseline NIHSS (16.2 + 6.2 vs 15.4 + 6.2, p=.13), % M1 occlusion (57.9 vs.58.7, p=.85), baseline ASPECTS (7.3 + 1.7 vs 7.4 + 1.7, p=.33), and treatment characteristics: % IV-tPA (64.6 vs. 63.4, p=.78), % TIC1 >=2B (80.6 vs. 79.1, p=.68) were comparable in the DTA and non-DTA groups respectively. Mean time from onset to groin puncture (5.3 ±3.3 vs 6.6 ±4.2

hours, $p < 0.001$) and median time from arrival at thrombectomy center to groin puncture (40 vs 63 min, $p < 0.001$) were significantly shorter in the DTA group. Rates of mRS 0-2 (57% vs 58%, $p = 0.84$) and mortality (12% vs 10%, $p = 0.41$) were comparable between the DTA and non-DTA groups. Symptomatic ICH was significantly lower in the DTA group (0% vs 2.3%, $p = 0.028$). A multivariable linear regression identified direct transfer ($p = .002$), administration of IV tPA ($p < .0001$) and M1 occlusion ($p = .001$) as independent predictors of time from symptom onset to recanalization, while a multivariable logistic regression identified age, (OR=0.97, $p = .049$), and discharge NIHSS (OR=0.75, $p < .0001$) as independent predictors of mRS 0-2 at 90 days. Amongst early window (<6 hour) patients with NIHSS >10 and ASPECTS <8, rates of mRS 0-2 were higher in the DTA group compared to the non-DTA group (56% vs 43%, $p = 0.08$).

Conclusions:

Direct transfer to the angi suite is an independent predictor of shorter time to recanalization and may be associated with superior safety and efficacy outcomes in the 0-6 hour time window.

Keywords: Acute Ischemic Stroke Intervention

Financial Disclosures: The authors had no disclosures.

Grant Support: None.

Poster

Factors Associated with Longer Arrival-to-Puncture Time in MRI-Based Triage for Endovascular Thrombectomy

Robert W Regenhardt, MD, PhD¹, Neal A Nolan, MD¹, Joseph A Rosenthal, MD, PhD¹, Alvin S Das, MD¹, Naif M Alotaibi, MD¹, Justin E Vranic, MD¹, Christopher J Stapleton, MD¹, Aman B Patel, MD¹, Natalia S Rost, MD, MPH¹, Thabele M Leslie-Mazwi, MD¹

¹Massachusetts General Hospital, Boston, Massachusetts, United States of America

Introduction:

Given the efficacy of endovascular thrombectomy (EVT), accurate and timely triage of treatment candidates is key. MRI represents the gold standard for infarct core assessment but may require more time to obtain than CT. We sought to identify factors associated with longer arrival-to-puncture time for large vessel occlusion (LVO) stroke patients who underwent MRI-based triage for EVT to develop strategies to improve times.

Methods:

Patients were identified from a prospectively maintained EVT database that included demographics, presentations, treatments, and outcomes. The EVT hub serves a large network of telestroke spoke centers. Time metrics were calculated for the hub. Arrival times, or consult times for inpatient strokes, were obtained from the medical chart. MRI time was obtained from the time stamp on the first sequence obtained. Variables with pre-specified significance of $p < 0.10$ in univariable analysis were subsequently included in a multivariable model. A protocol revision was made in 2015, which was controlled for in a multivariable model.

Results:

We identified 200 LVO patients (mean age 68 ± 16 years, 58% female) who underwent MRI for EVT triage from 2011-2019. Over this wide time period, median arrival-to-MRI time was 42 minutes (IQR 31-57) and median MRI-to-puncture time was 52 minutes (IQR 38-76). A multivariable model showed longer arrival-to-puncture time was associated with Black race/Hispanic ethnicity ($\beta = 0.254$, $p < 0.0001$), coronary artery disease ($\beta = 0.189$, $p = 0.003$), inpatient stroke presentations ($\beta = 0.127$, $p = 0.047$), and general anesthesia ($\beta = 0.389$, $p < 0.0001$).

Conclusions:

Real-world challenges exist to an expedited MRI-based selection protocol for EVT. Understanding variables associated with delay will inform protocol evolution to improve time metrics.

Keywords: Endovascular Therapy, Mechanical Thrombectomy, Ischemic Stroke, MRI, Imaging

Financial Disclosures: The authors had no disclosures.

Grant Support: None.

Poster

Missed treatment opportunities and earlier stroke detection among hospitalized patients at risk of acute infarction

Prasanth Romiyo, BS¹, Parth Patel, BS¹, Lauren Thau, BS¹, Mark Heslin, BS¹, Ainsley Smith, BS¹, Austin Chen, BS¹, Dena Little, DO², Jesse M Thon, MD², James E Siegler, MD²

¹Cooper Medical School, Sewell, New Jersey, United States of America; ²Cooper University Hospital, Camden, New Jersey, United States of America

Introduction:

In preparation for a quality improvement study, we queried our prospective stroke registry for patients who might benefit from prophylactic monitoring in order to estimate the time advantage to monitoring.

Methods:

A prospective, single center registry of adult patients (9/20/19-6/30/20) was queried for in-hospital acute anterior circulation strokes. Indications for hospitalization as well as delays from last known well (LKW) to symptom recognition, imaging, and treatment were explored.

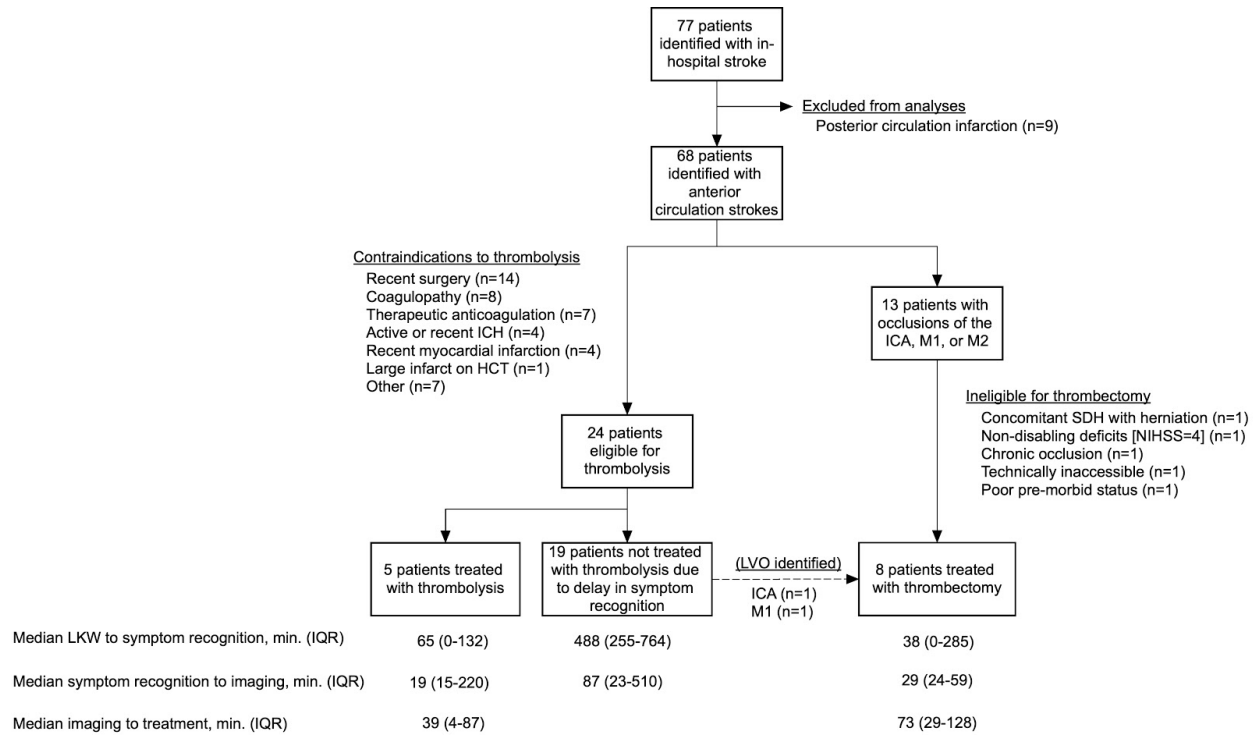
Results:

Of 540 consecutively evaluated adults with acute stroke, 68 (12.6%) developed an anterior circulation infarction while hospitalized, 32 (47.1%) of whom were female with a median age of 66 years (IQR 60-77) and median NIHSS of 14 (IQR 4-22). Four patients (5.9%) received intravenous thrombolysis although another 20 (29.4%) would have been eligible for thrombolysis if not for a delay in symptom recognition. An internal carotid, M1, or M2 occlusion was observed in 13 patients (19.1%), 8 of whom were treated at a median of 198 minutes after LKW (IQR 102-670; **Figure 1**). In patients treated endovascularly or with thrombolytics, the delay from LKW to symptom recognition accounted for 55.5% of the delay in care.

Conclusions:

One-third of patients in this single-center cohort would have been eligible for thrombolysis were it not for delays in symptom recognition. The delay to groin puncture exceeded 3 hours for over half of patients with proximal anterior occlusions. Earlier detection of large vessel occlusions and ischemic stroke waveform patterns using prophylactic monitoring devices has the potential to reduce this major impedance to stroke care and ultimately improve outcomes.

Figure. Patient flowchart.



Keywords: Acute Ischemic Stroke Intervention, Door To Groin Puncture

Financial Disclosures: The authors had no disclosures.

Grant Support: None.

Poster

Global Impact Of Covid-19 Pandemic On Acute Stroke And Mechanical Thrombectomy - An International Survey

Dileep R Yavagal, MD¹, Vasu Saini, MD¹, Violiza Inoa, MD², Hannah E Gardener, PhD¹, Sheila O Martins, MD³, Manav Fakey, BE⁴, Santiago Ortega, MD⁵, Ossama Mansour, MD⁶, Thomas Leung, MD⁷, Ashutosh P Jadhav, MD⁸, Jennifer Potter-Vig, PhD⁹, P N Sylaja, MD¹⁰, Andrew M Demchuk, MD¹¹, MT2020 Global Executive Committee, NA⁹

¹University of Miami Miller School of Medicine, Miami, Florida, United States of America; ²Semmes-Murphey Clinic, Memphis, United States of America; ³Univ Federal of Rio Grande do Sul, Hosp de Clínicas de Porto Alegre, Porto Alegre, Brazil; ⁴Orbees Medical, Delhi, India; ⁵Univ of Iowa Hosp, Iowa City, United States of America; ⁶Alexandria Univ Hosp, Alexandria, Egypt; ⁷The Chinese Univ of Hong Kong, Hong Kong, Hong Kong; ⁸Barrow Brain and Spine Inst, Phoenix, United States of America; ⁹Society of Vascular and Interventional Neurology, Minneapolis, United States of America; ¹⁰Sree Chitra Tirunal Inst for Medical Sciences and Technology, Trivandrum, India; ¹¹Univ of Calgary, Calgary, Canada

Introduction:

The COVID-19 pandemic has strained the healthcare systems across the world but its impact on acute stroke care is just being elucidated. We hypothesized a major global impact of COVID-19 not only on stroke volumes but also on thrombectomy practice.

Methods:

A 19-item questionnaire survey aimed to identify the changes in stroke volumes and treatment practices seen during COVID-19 pandemic was designed using Qualtrics software. It was sent to stroke and neuro-interventional physicians around the world who are part of the executive committee of a global coalition, Mission Thrombectomy 2020 (MT2020) between April 5th to May 15th, 2020.

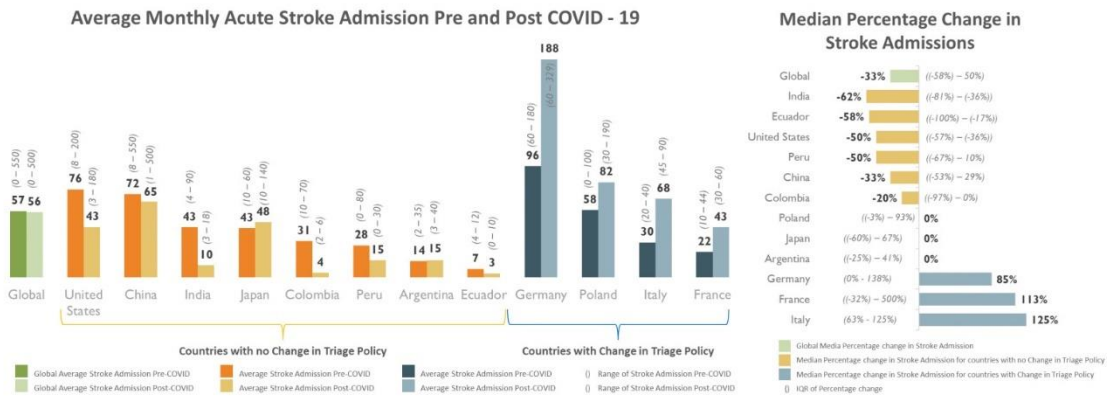
Results:

There were 113 responses across 25 countries. Globally there was a median 33% decrease in stroke admissions and a 25% decrease in mechanical thrombectomy (MT) procedures during COVID-19 pandemic compared to immediately preceding months (Figure 1A-B). This overall median decrease was despite a median increase in stroke volume in 4 European countries which diverted all stroke patients to only a few selected centers during the pandemic. The intubation policy during the pandemic for patients undergoing MT was highly variable across participating centers: 44% preferred intubating all patients, including 25% centers that changed their policy to preferred-intubation (PI) vs 27% centers that switched to preferred-conscious-sedation (PCS). There was no significant difference in rate of COVID-19 infection between PI vs PCS ($p=0.6$) or if intubation policy was changed in either direction ($p=1$). Low-volume (<10 stroke/month) compared with high-volume stroke centers (>20 strokes/month) are less likely to have neurointerventional suite specific written personal protective equipment protocols (74% vs 88%) and if present, these centers are more likely to report them to be inadequate (58% vs 92%).

Conclusions:

Our data provides a comprehensive snapshot of the impact on acute stroke care observed worldwide during the pandemic.

Figure 1. Average monthly stroke admissions (1A) and median percentage change in stroke admissions (1B) pre and post-COVID-19 globally and amongst countries with at least 3 or more responses with or without change in pre-hospital stroke triage policy.



Keywords: Acute Stroke, Acute Ischemic Stroke Intervention, Cerebrovascular Disease, Endovascular Therapy, Mechanical Thrombectomy

Financial Disclosures: Steering committee TIGER clinical trial sponsored by Rapid Medical. Steering committee CALM-2 sponsored by Vascular Dynamics. Consultant Medtronic, Cerenovus, Poseydon, Neurosave, and other Neuralanalytics.

Grant Support: None.

Poster

Incidence And Treatment Of Aneurysmal Subarachnoid Haemorrhage In A Regional Unit Over 5 Years

Peter Crossley, Dr¹, Neil Simms, Mr¹, Karen Thompson, Dr¹

¹*Royal Victoria Hospital, Belfast, United Kingdom of Great Britain and Northern Ireland*

Introduction:

Aneurysmal subarachnoid haemorrhage (aSAH) is associated with high rates of morbidity and mortality. There is a reported global incidence of aSAH of 6.1 per 100,000, decreased from 10.2 per 100,000 in 1980(1). The purpose of this study was to assess change in the incidence, patient demographics and management of aSAH in a small regional unit with a relatively stable population.

Methods:

This was a retrospective analysis of all aSAH patients referred to the neurosurgery service over a 5 year period from 1 Jan 2015 until 31 December 2019 . Data on patients admitted to the unit was taken from the local database. Data on patients not transferred and admitted to their local hospitals was taken from referral documents. Further patient information was gathered from the local Electronic Care Record and PACS systems.

Results:

482 patients with aSAH were referred to the neurosurgery service over the 5 year period with 381(79%) admitted to the unit. 105 patients were referred in 2015 reducing to 80 patients in 2019. The percentage of patients referred who were admitted increased over the study period with 69% admitted in 2015 and 91% admitted in 2019. The mean age of patients admitted to the unit increased from 54 to 59, with a 90 year old patient admitted in 2019. The age of patients who were too unwell to be transferred from their local hospitals also increased in line with this from a mean of 69 to 76 by 2019. The mean number of bed days has remained fairly stable with a mean of 21 days in 2015 compared to 22 days in 2019.

385 patients were treated acutely for their aSAH between 2015 and 2019. Most patients were managed with endovascular treatment (97%). Patients who required acute clipping has remained stable over the study. The most common acute treatment modality is endovascular coiling of the aneurysms with 82% of patients coiled as their only treatment. 11% of patients required acute stenting. The number of patients treated with a WEB device decreased from a peak of 5 in 2017 to 1 in both 2018 and 2019.

Conclusions:

The overall incidence of aSAH is decreasing. This is likely due to better management of hypertension and a decrease in smoking prevalence alongside increased identification of unruptured aneurysms and an associated increase in elective aneurysm treatment. The age of patients admitted to the unit has increased yearly, partly due to an aging population but also as older patients tolerate endovascular treatment better than clipping. Despite the trend towards older patients the number of hospital bed days has remained fairly stable. Most patients are treated endovascularly with coiling however there has been an increase in the role of acute stenting.

Keywords: Aneurysm Embolization, Endovascular Therapy, SAH

Financial Disclosures: The authors had no disclosures.

Grant Support: None.

Poster

A New Era For Cerebral Angiograms: TransRadial (TR) Approach In Neurointerventional Radiology (NIR)

taylor gasparovic, BSN, RN¹, Sarh Cook, MSN, RN¹, Eileen Roach, MSN, RN¹, Kate Spiering, MSN, RN¹, Benjamin Morrow, MSN, RN¹, Stephanie Henry, MSN, RN¹, Ashu Jadhav, PhD, MD¹, Benjamin Zussman, MD¹

¹*UPMC Presbyterian Hospital, Pittsburgh, Pennsylvania, United States of America*

Introduction:

Historically, the femoral artery approach has been the standard for NIR procedures. However, the TR approach is being increasingly implemented across healthcare centers globally within NIR departments. Recent advances in NIR cerebral angiography such as the TR-approach—are currently being adopted into practice by proceduralists at our own facility for diagnostic & interventional procedures. This has created a vacuum in which there is a significant need to improve and standardize post-procedural angiogram care from the nursing perspective, due to the lack of knowledge related to this recently adopted practice. This change necessitates staff competency when caring for TR-approach patients. The project goal was to observe a 25% increase in TR-approach care documentation elements by January 2020.

Methods:

In 2019, our facility received a recommendation for improvement (RFI) from The Joint Commission during the Comprehensive Stroke Center survey related to incomplete post-procedure documentation. Upon initiation of TR documentation audits, documentation compliance rates of 46.2% for both deflation volumes and TR band removal were discovered. In August 2019, education created by NIR manager was shared with bedside nursing staff as the target audience. Education was distributed to unit leadership and staff. Audits immediately followed and were completed by NIR manager and stroke institute quality nurse to measure documentation compliance of deflation volumes and TR band removal.

Results:

The audits demonstrated a 28.4% increase in compliance of TR band removal documentation and an 18.6% increase in compliance in TR band deflation protocol documentation. This project's impact has improved post-procedural care of patients through better documentation for TR-approach procedures. The standardization of post-procedural nursing care created a template for nursing leaders to use as education for newly hired staff on high turnover units. Standard processes can be integrated into practice amongst staff of all experience levels with appropriate education. Our team implemented the NIR documentation band within our electronic documentation system, placing all required details associated with post TR-approach procedures in one location. Additionally, within this band we specifically added the two elements that lacked compliance. The two primary elements that were added to the NIR documentation band included deflation of air and removal of the TR band. Other NIR suites transitioning to the TR-approach can use our process as a model for their own needs.

Conclusions:

The lessons that we have learned from this process have created a model that has resulted in a seamless protocol for post TR procedural recovery and ultimately improving patient safety and outcomes. Lastly, we seek to share the principals gained from this process with other hospitals looking to evolve their NIR practice within their healthcare system in order to replicate our experience.

Keywords: New Innovation, New Technique, Care

Financial Disclosures: The authors had no disclosures.

Grant Support: None.

Poster

Geographical and Temporal Trends in the First Year of the S-LAMS EMS Triage Protocol

Naoum Fares Marayati, BA¹, Jacob Morey, MBA¹, Stavros Matsoukas, MD¹, Xiangnan Zhang, PhD¹, Brian D Kim, MD¹, Johanna Fifi, MD¹

¹*Icahn School of Medicine at Mount Sinai, New York, New York, United States of America*

Introduction:

Endovascular therapy (EVT) is the standard of care for large vessel occlusion (LVO) acute ischemic stroke (AIS). It is time-sensitive intervention that has challenged stroke systems of care. Previously, LVO AIS patients were triaged to the closest stroke center regardless of their classification. For patients triaged to a primary stroke center (PSC), a subsequent transfer to a thrombectomy capable stroke center (TSC) was required for EVT. In recent years, there has been a shift to triaging directly to TSCs if the TSC is within a specific radius beyond the PSC. In April 2019, our city implemented such a protocol based on a modified Los Angeles Motor Scale (includes speech; S-LAMS) of ³4, last known normal <5 hours, and transport time to a TSC of <30 minutes. Geographical and temporal trends in the S-LAMS protocol have yet to be analyzed.

Methods:

A prospective database was assessed for patients who were triaged with S-LAMS and presented to a TSC in a large urban multi-center health system between April 2019 to March 2020. Our hospital system consists of 4/22 TSCs participating in the city's S-LAMS protocol. A total of 140 of 145 patients were included; 5 were excluded for missing EMS data. Pick up locations and transport times were extracted. Google Maps application programming interface (API) was used to calculate the closest PSC and TSC for each patient using both distance and time (based on daily averages) data.

Results:

The S-LAMS protocol led to 140 patients being brought directly to a TSC. AIS with LVO was diagnosed in 69 patients, AIS without LVO in 14 patients, intracerebral hemorrhage in 25 patients, and 32 patients were stroke mimics. 24% (33/140) underwent EVT, 2% underwent angiography without EVT, and 83% did not undergo an intervention. The mean travel distance was 1.97 ± 1.4 miles and time was 7.36 ± 5.66 minutes. The S-LAMS protocol had a confirmed PSC bypass in 47.9% (67/140) of cases and the mean additional distance and estimated time was 1.55 ± 1.48 miles and 7.9 ± 2.6 minutes. Of the triaged patients, the TSC was the closest by distance in 88.6% (124/140) of cases but was only closest by estimated travel time in 46.4% (65/140) of cases. If the closest TSC was selected based on time, instead of distance, an estimated 1.5 minutes could have been saved.

Conclusions:

The S-LAMS protocol in our city has shown that bypass of PSCs for TSCs occurred in about half of cases with an additional mean distance of 1.1 miles. In terms of time, this protocol results in triage to the closest TSC in less than half of cases. Therefore, updates in this protocol could include basing decisions on time, rather than distance, although the difference may not be clinically significant.

Keywords: Stroke, Scale, Acute Stroke, Acute Ischemic Stroke Intervention, Care

Financial Disclosures: The authors had no disclosures.

Grant Support: None.

Poster

Eligibility for endovascular treatment in the 6 to 24-hour time window: Retrospective study from India

Deepti Vibha, Additional Professor¹, Shubham Misra, PhD Student¹, Shashvat M Desai, Research Scholar², Kameshwar Prasad, Professor¹, Achal K Srivastava, Professor¹, Ashutosh P Jadhav, Professor²

¹All India Institute of Medical Sciences, New Delhi, India; ²University of Pittsburgh Medical Center, Pittsburgh, Pennsylvania, United States of America

Introduction:

While the DAWN (6-24 hours) and the DEFUSE-3 trials (6-16 hours) have expanded the time window for endovascular thrombectomy (EVT) up to 24 hours, treatment eligibility in developing countries is poorly understood. We aim to identify the prevalence of EVT eligible patients in the 6-24-hour time window at a large academic center in India.

Methods:

A retrospective review of acute ischemic stroke (AIS) admissions was performed between July 2017 and September 2019. Eligibility for EVT was explored based on modified DAWN and/or DEFUSE-3 trial criteria [clinical trial-specific selection criteria including the presence of large vessel occlusion, National Institutes of Health Stroke Scale (NIHSS), baseline modified Rankin Scale score, and the Alberta Stroke Program Early Computerised Tomography Score (ASPECTS) ≥ 6 instead of clinical-core or perfusion mismatch.

Results:

Out of 221 patients with AIS admitted within the study period, 38.5% (85/221) presented within the 6-24-hour time window, and 85.1% (188/221) had an NIHSS ≥ 6 . Of all AIS patients, 3.6% (8/221) and 3.2% (7/221) patients met modified DAWN and DEFUSE-3 trial criteria, including presence of anterior circulation large vessel occlusion (ACLVO) and ASPECTS ≥ 6 . In the 6-24-hour window (85), 9.4% (8/85) and 8.2% (7/85) of patients met modified DAWN and DEFUSE-3 criteria, respectively.

Conclusions:

Of all patients with AIS presenting to a large academic center in the 6-24-hour window, 9.4% and 8.2% of patients qualified for modified DAWN and DEFUSE-3 clinical trial criteria, respectively. These data predict a large potential for late window EVT in India.

Keywords: Acute Ischemic Stroke Intervention, Endovascular Therapy

Financial Disclosures: The authors had no disclosures.

Grant Support: None.

Poster

Long-Term Outcomes of Arteriovenous Fistula Treated with Coiling: Subset Analysis of the SMART Registry

Robert M Starke, MD MSc¹, Min S Park, MD², Clemens M Schirmer, MD PhD FAANS FAHA³, Richard J Bellon, MD⁴, Alejandro M Spiotta, MD⁵

¹University of Miami, Miami, Florida, United States of America; ²University of Virginia, Charlottesville, Virginia, United States of America; ³Geisinger Medical Center, Danville, Pennsylvania, United States of America; ⁴Swedish Medical Center, Denver, Colorado, United States of America; ⁵Medical University of South Carolina, Charleston, South Carolina, United States of America

Introduction:

For the treatment of arteriovenous fistula (AVF), endovascular embolization techniques are generally the primary therapeutic modality. The objective of this study was to assess the long-term clinical outcomes of AVF treated with coiling.

Methods:

Data on patients with AVF were extracted from a prospective multicenter registry (SMART) that enrolled patients with intracranial aneurysm or other neurovascular abnormality who underwent coiling with SMART coils. The primary effectiveness outcome was retreatment through follow-up, and the primary safety outcome was procedural device-related serious adverse events (SAEs) within 24 hours. The secondary effectiveness outcome was complete occlusion immediate post procedure. Additional outcomes were device-related SAEs and mortality within 24 hours of procedure and better or stable lesion occlusion, all-cause mortality, and modified Rankin Scale score (mRS) at 1-year follow-up.

Results:

Of the 995 adults enrolled in the SMART registry, 41 had AVF. Average patient age was 55.5 years (SD 16.9) and 51.2% of patients were female. The most common lesion locations were the cavernous ICA/sinus (46.3%), sigmoid transverse sinus (34.1%), and ECA (12.2%). Coiling alone was used in (61.0%) cases; adjunctive treatments included liquid embolic (24.4%), stent-assisted coiling (9.8%), and balloon-assisted coiling (4.9%).

No procedural device-related SAEs occurred within 24 hours. Complete occlusion immediate post procedure was observed in 87.8% (36/41) of all patients, 96.0% (24/25) of patients who underwent coiling alone, 80.0% (8/10) of patients who underwent coiling plus liquid embolic, and 66.7% (4/6) of patients who underwent stent-assisted coiling or balloon-assisted coiling. Within 24 hours of the procedure, no device-related SAEs and no deaths occurred. At 1-year follow-up, better or stable occlusion was observed in 93.3% (28/30) of all patients, 95.0% (19/20) of patients who underwent coiling alone, 85.7% (6/7) of patients who underwent coiling plus liquid embolic, and 100% (3/3) of patients who underwent stent-assisted coiling or balloon-assisted coiling. Retreatment through follow-up was performed in 3.4% (1/29) of patients. At 1-year follow-up, the all-cause mortality rate was 2.4% (1/41), and an mRS of 0-2 was observed in 90.0% (20/22) of patients.

Conclusions:

Coiling of arteriovenous fistulas was safe and effective at 1 year.

	Arteriovenous fistula (N = 41)
Baseline data	
Age, years (mean (SD))	55.5 (16.9)
Female	51.2%
mRS 0-2 at admission	87.5% (21/24)
Lesion location	
Cavernous ICA/sinus	46.3%
Sigmoid transverse sinus	34.1%
ECA	12.2%
Posterior circulation	4.9%
Peripheral	2.4%
Procedural data	
Adjunctive technologies used	
None (unassisted coiling)	61.0%
Liquid embolic	24.4%
Stent-assisted coiling	9.8%
Balloon-assisted coiling	4.9%
Primary endpoints	
Retreatment through follow-up	3.4% (1/29)
Procedural device-related SAEs within 24 hours	0.0%
Secondary endpoint	
Complete occlusion immediate post procedure	
All patients	87.8%
Coiling alone	96.0%
Coiling plus liquid embolic	80.0%
Stent-assisted coiling or balloon-assisted coiling	66.7%
Additional outcomes	
Device-related SAEs within 24 hours of procedure	0.0%
Mortality within 24 hours of procedure	0.0%
Better or stable lesion occlusion at 1 year	
All patients	93.3% (28/30)
Coiling alone	95.0% (19/20)
Coiling plus liquid embolic	85.7% (6/7)
Stent-assisted coiling or balloon-assisted coiling	100% (3/3)
Mortality at 1 year, all-cause	2.4%
mRS 0-2 at 1-year follow-up	90.9% (20/22)

Keywords: Cerebral Arteriovenous Malformations, Clinical Trial, Coiling, Endovascular, Penumbra

Financial Disclosures: Research support: NREF, Joe Niekro Foundation, Brain Aneurysm Foundation, Bee Foundation, and NIH and through the Miami CTSI, from the NCATS and the NIMHHD. Consulting and Teaching: Penumbra, Abbott, Medtronic, InNeuroCo, Cerenovus.

Grant Support: None.

Poster

Embolization of Peripheral High Flow arteriovenous Malformations with Squid

Saima Ahmad, Neuroradiologist¹

¹Lahore General Hospital, Lahore, Pakistan

Introduction:

Head and neck arteriovenous malformation and fistulae treatment without reflux and with nidal penetration are challenging. Squid, is an ethylene-vinyl alcohol copolymer (EVOH)-based liquid embolic agent developed for neuroradiologic interventions with limited application in peripheral AVMs. We describe a study including adult and pediatric patients using Squid (18 & 12) alone and with other embolic agents for embolization. We aim to demonstrate the safety and efficacy of this agent.

Methods:

Twenty patients (7 men, 13 women) with peripheral high flow arteriovenous malformations who were treated primarily with arterial embolization using squid between Jan 2017 to Dec 2019 were retrospectively included. AVMs were located in the head and neck (16), extremities (2), uterus (1), pelvis (1). In 15 patients embolization was done using squid only. Only one patient underwent embolization by direct puncture, the others by the transarterial route. Embolization was performed in single or two sessions, with or without surgery. A total of 27 sessions were performed with a delay between 6 to 36 months.

Squid is ethyl vinyl alcohol (EVOH) based liquid embolic agent, squid was used for embolization either alone or with other embolic agents. Two types of Squid were used: Squid-18 and Squid-12, characterized by high and low viscosity, respectively. Squid was mainly used in combination with other embolic agents (PVA particles, and bleomycin) or alone to increase the embolizing power. Squid was always administered using DMSO-compatible microcatheters. The Squid was more slowly injected (60–90s) to minimize DMSO toxicity and to ensure its tolerability also in the case of TE of small vessels.

Results:

Technical success was achieved in all cases. Complete devascularization was obtained in 13 patients. Surgical excision was performed in 4 patients. One patient had pain without improvement. One patient develops a garlicky taste. There was no mortality. Major complications, cases of microcatheter entrapment and DMSO-related poor pain control were not recorded. Other patients were free of symptoms on follow up.

Conclusions:

Squid was successfully used with a low complication rate in all peripheral arteriovenous malformations showing a valid embolic action either combined with other embolic agents or alone. The availability of different formulations (Squid-18 and Squid-12) variable for viscosity makes Squid preferable to other embolic agents. Embolization of AVMs with squid is the treatment of choice with long term stable results.

Age/G	Lesion Site	Feeders	Conc of Squid	Other E Agents	Technical Results
21/F	R Facial	L internal maxillary artery	18	PVA particles (350-500u)	Partial /60% E
25/F	L Temple	L internal maxillary artery & Lingual facial trunk	18, 12	PVA Particles (250-350u)	Partial /80%E
11/F	R Facial	R internal maxillary artery	18	No	Complete
45/F	Ala of nose	L internal maxillary artery & Lingual facial trunk, L Ophthalmic artery	18	No	Partial
20/M	L Temple	L internal maxillary artery	18	No	Complete
30/F	Uterine	L Uterine artery	18	No	Complete
29/M	Scrotal region	L internal iliac artery-multiple branches	18	PVA Particles (250-350u), NBCA	Partial -50% E
30/F	R Foot	R Anterior tibial artery & posterior tibial artery	18	No	Complete
37/F	L arm	L Radial artery	18	No	Complete
19/F	L Auricular	L Posterior Auricular artery	18,12	No	Complete
14/F	R Auricular, scalp & neck	L Posterior Auricular artery, Occipital artery	18	PVA Particles (250-350u)	Complete
12/M	R Mandibular	R Lingual -facial trunk	18	No	Complete
11/M	R Mandibular	R Lingual -facial trunk	18	No	Partial 80% /ICA feeders not embolized
23/M	Nape and left side neck	Bilateral Occipital arteries & bilateral superficial temporary arteries	18	No	Complete
35/F	R Auricular	Right Posterior Auricular Artery	18,12	No	Complete
28/F	Nasal root and bridge	L internal maxillary artery, L Ophthalmic artery	18	PVA Particles (250-350u), NBCA	Partial 80% improved
16/F	L Auricular & scalp	B/L Occipital arteries & superficial	18,12	No	Complete

Keywords: Avm Embolization, Diagnostic Neuroradiology, Angiogram, Vascular Imaging, Endovascular

Financial Disclosures: The authors had no disclosures.

Grant Support: None.

Poster

Mixing Ethanol And Contrast Agent For A Superselective Transarterial Embolization Of Intracranial Dural Arteriovenous Fistula

Aaron Ravelo, Neurology¹, Rahul Chandra, Neurology¹, Andrew Ku, Endovascular Neurosurgery¹

¹*Allegheny Health Network, Pittsburgh, Pennsylvania, United States of America*

Introduction:

Intracranial dural arteriovenous fistula (DAVF) are rare abnormal communications between meningeal arteries and dural venous sinuses or cortical veins. Transverse and sigmoid sinus is the most common of these lesions. There is limited information in the literature about the interactions of ethanol with various non-ionic contrast agents. Ethanol is used as selective embolization of craniofacial arteriovenous malformations and DAVFs, which can cause endothelial cells protein denaturation leading to vessel wall thrombosis.

Methods:

Review of the medical literature describing the application in clinical practice of using an innovative method mixing 50% ethanol (98%) and 50% of isovue-300 contrast in patients with DAVFs.

Results:

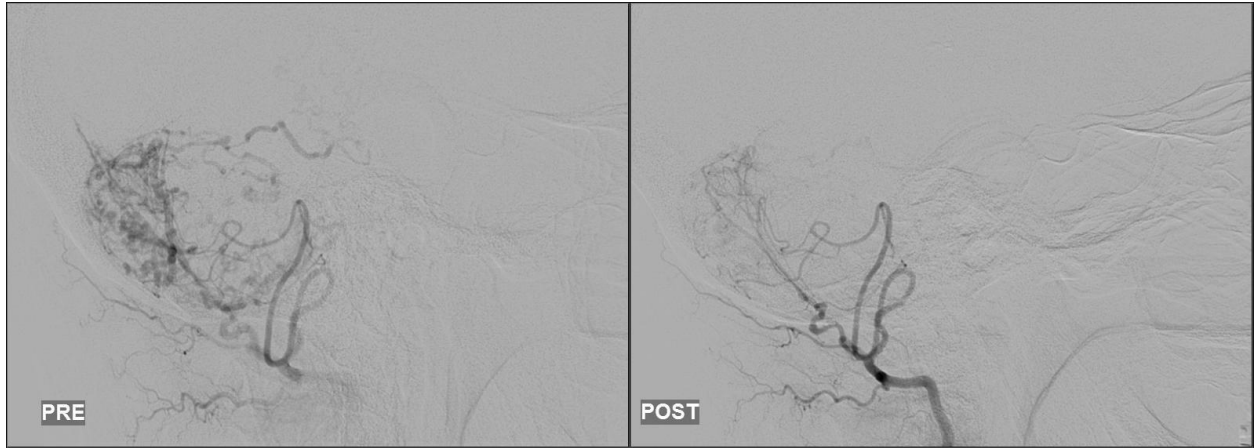
58-year-old man with no significant past medical history presented with progressive intermittent dizziness for 2 weeks with worsening severe headaches and nausea. Initial CT head showed superior left cerebellum vasogenic edema, CT angiogram head and neck showed numerous arteries enhancing vessels in the left posterior fossa and prominent cortical veins in the left temporal lobe. MRI brain revealed a left cerebellar dural AV fistula with partial effacement of 4th ventricle. Digital subtraction angiography (DSA), identified a complex DAVF fed mainly by three arteries; 1. Majority were branches of posterior meningeal artery arising off left vertebral artery. 2. Bilateral branches from occipital arteries. 3. Minimal supply from distal petrous branches of left middle meningeal artery (MMA) draining to cerebellar veins and straight sinus.

DAVF was classified as aggressive type III by Borden and symptomatic aggressive type IV by Cognard classification. Patient underwent three embolizations with 50% ethanol (98%) and 50% isovue-300 contrast.

The first selective embolization was distal to branches of posterior meningeal artery with complete resolutions of symptoms. Follow up DSA showed residual low risk DAVF. After 1 month, the second and third superselective embolization was performed distal to the left petrosal branch of MMA without complications. He was discharged home without any neurological deficit. Patient is scheduled for follow up with Brain MRI in 4 weeks.

Conclusions:

Currently there are no clear guidelines on the use of combined ethanol and contrast solution for embolization of DAVF with multiple complex arterial feeders and presence of cortical venous drainage. Our case highlights that the use of ethanol and isovue-300 contrast provides adequate resolution of DAVF while minimizing the adverse side effects seen with larger doses of ethanol.



Keywords: Embolization, New Technique, Endovascular

Financial Disclosures: The authors had no disclosures.

Grant Support: None.

Poster

Long-Term Outcomes of Endovascular Treatment of Dural Arteriovenous Fistulas: A Single Center Experience

Alan Mendez-Ruiz, MD¹, Mudassir Farooqui, MD, MPH¹, Cynthia B Zevallos, MD¹, Darko Quispe-Orozco, MD¹, Kaustubh Limaye, MD¹, Edgar Samaniego, MD¹, Santiago Ortega-Gutierrez, MD, MSc¹, Waldo R Guerrero, MD²

¹University of Iowa Hospitals and Clinics, Iowa City, Iowa, United States of America; ²University of South Florida, Tampa, Florida, United States of America

Introduction:

Dural arteriovenous fistulas (DAVF) are acquired pathological arteriovenous communications between meningeal arteries and dural venous sinuses or cortical veins. With the development of endovascular techniques and embolic agents, endovascular therapy (EVT) has become the preferred choice of many centers for the treatment of DAVFs. The aim of this project is to study the long-term safety and efficacy outcomes of EVT treatment of DAVF.

Methods:

We conducted a single center retrospective cohort study of patients with DAVFs treated endovascularly between 2005 and 2017. Patient demographics and DAVF characteristics were collected, as well as technical characteristics including endovascular approach, embolic agent used, number of treatments, occlusion rates, and complications. Complete DAVF occlusion was defined as the absence of feeding artery shunting into sinus or cortical veins. Clinical and angiographic characteristics were collected at last available follow-up.

Results:

Forty-seven patients with a mean age of 56.6 years. Sixty percent were female. Increased venous drainage symptoms were the most common presentation (70%) and 22% had ruptured DAVFs. Transverse-sigmoid sinus (32%) was the most common DAVF location followed by cavernous sinus (30%). Thirty-five patients (75%) had middle meningeal arterial feeders and 30 (64%) had cortical venous drainage. Thirty-one patients (66%) had pre-procedure MRI of which 7 (14%) showed hyperintense flair signals co-localizing with the DAVF. The mean number of embolization procedures per patient was 1.5. Trans-arterial access was the most frequent approach (67%). Onyx was the most common embolic material used (49%) followed by coils (21%). Complete occlusion rate was achieved in 34 patients (72%). Eight procedural complications (17%) were observed: 6 cutaneous radiation injuries, 2 ischemic strokes and 1 intracranial hemorrhage. Angiographic follow-up was available in 42 patients (89%). Mean angiographic follow-up time was 862 days. MRA was the most common imaging technique (36%). Five (12%) DAVF recurrences and 1 (2%) de-novo fistula were observed. Clinical follow-up was available for all patients with a mean follow-up time of 1395 days. Twenty-nine patients (62%) had mRS of 0, 16 mRS of 1, 1 mRS of 2, and 1 mRS of 4. No DAVF-related new symptoms or hemorrhagic/ischemic complications were observed. No deaths were reported.

Conclusions:

EVT is safe and effective for the treatment of DAVF. High occlusion rates were achieved with no complications or mortality. Follow-up for several years after last embolization is recommended due to the AVFs recurrence rates.

Keywords: Cerebral Arteriovenous Malformations, Embolization, Onyx, Cerebrovascular Disease, Endovascular Therapy

Financial Disclosures: The authors had no disclosures.

Grant Support: None.

Poster

Clinical characteristics of traumatic brain injury patients undergoing endovascular rescue for post-traumatic vasospasm

Kasra Khatibi, MD¹, Lucido Luciano Ponce Mejia, MD¹, Hamidreza Saber, MD¹, Naoki Kaneko, MD PhD¹, Reza Jahan, MD¹, Satoshi Tateshima, MD PhD¹, May Nour, MD PhD¹, Geoffrey p Colby, MD PhD¹, Gary Duckwiler, MD¹, Viktor Szeder, MD PhD¹

¹UCLA, Los Angeles, California, United States of America

Introduction:

Cerebral vasospasm is a serious sequela of traumatic brain injury (TBI) which leads to further neurologic injury subsequent to the initial trauma. The natural history, associated risk factors, and the optimal treatment strategy is not well understood. We aim to evaluate the clinical and radiographic characteristics of patients with TBI who underwent endovascular rescue therapy for post-traumatic vasospasm (PTV).

Methods:

This is a descriptive case series of all patients with TBI who underwent endovascular rescue therapy for PTV between October 2017 to November 2019. We studied the clinical characteristics - age, sex, Glasgow coma scale (GCS), need for craniotomy or craniectomy, radiographic characteristics on the CT scan on the day of presentation, presence of subarachnoid hemorrhage (SAH), location of SAH, presence of contusion, presence of SDH, and presence of pseudoaneurysm of the patients who underwent rescue therapy. The timing of occurrence of vasospasm, severity of spasm on angiography, type of rescue therapy and dose of medication used were also studied. We evaluated association of these clinical characteristics with cumulative severity of vasospasm observed on angiography. Descriptive statistics were used for analysis.

Results:

We identified 22 patients with PTV with 69 rescue angiograms performed (mean: 3.2; range: 1-9 angiograms per patient) during this period. Average age upon presentation was 40-years old, 81% of the patients were male sex and average GCS was 6.8. Sixty-seven percent of the patients underwent craniotomy or craniectomy. All patients had SAH, though only 60% had cisternal SAH. Parenchymal contusion was noted on 90% as well as SDH in 90%. The PTV were noted between 3 to 19 days after trauma. All patients undergoing rescue therapy received verapamil infusion (5-35mg). There was no correlation ($r^2 > 0.5$) between any of the clinical or radiographic variables studied and cumulative or average severity noted on the angiograms for each patient.

Conclusions:

Post-traumatic vasospasm can be detected as early as post trauma day 3 to 19 in patients with TBI and SAH. Absence of cisternal SAH does not rule out occurrence of the vasospasm during the course of treatment.

Keywords: Vasospasm, Vasodilator

Financial Disclosures: The authors had no disclosures.

Grant Support: None.

Poster

Variables Associated with Repeat Endovascular Interventions for Refractory Vasospasm in Aneurysmal Subarachnoid Hemorrhage Patients

William Mualem, BS¹, Ehsan Dowlati, MD², Daniel R Felbaum, MD³, Ai-Hsi Liu, MD³, Jeffrey C Mai, MD, PhD³, Rocco A Armonda, MD³

¹Georgetown University School of Medicine, Washington, District of Columbia, United States of America;

²Medstar Georgetown University Hospital, Washington, District of Columbia, United States of America;

³MedStar Washington Hospital Center, Washington, District of Columbia, United States of America

Introduction:

Arterial vasospasm is a common complication following aneurysmal subarachnoid hemorrhage (SAH) and is a major cause of morbidity and mortality in this subgroup of patients. About half of these patients show severe spasm that leads to delayed cerebral ischemia (DCI). Endovascular intervention is performed in medically refractory cases. Although typically performed once, some patients require multiple endovascular interventions over the course of their hospitalization. The aim of our study is to evaluate variables associated with repeat endovascular treatments for vasospasm as well as to identify differences in outcomes following one versus multiple treatments.

Methods:

We performed a single center retrospective review of all adult patients who were treated for aneurysmal SAH between 2017 and May 2020. In our analysis, we included all patients who underwent treatment (either intra-arterial vasodilatory agents or mechanical intervention with balloon angioplasty) for radiographically diagnosed vasospasm. Patients were divided into those undergoing single treatment and those requiring multiple endovascular treatments for vasospasm. Baseline, treatment, and outcome variables were collected for these patients and compared between the groups.

Results:

A total of 58 out of 200 SAH patients underwent endovascular intervention for vasospasm during their hospital stay. 37/58 (63.8%) underwent single treatment and 21/58 (36.2%) underwent two or more treatments. There were no differences in demographics or admission variables. There was a significant difference in aneurysm location, with posterior circulation aneurysms significantly associated with need for multiple treatments (OR 14.5; 95% CI 2.3-286.9; $p=0.017$). Those undergoing multiple treatment were also more likely to require vasopressors ($p=0.0371$), have an intracranial pressure (ICP) crisis ($p=0.0162$), undergo angioplasty ($p=0.0195$), and display clinical symptoms of vasospasm ($p=0.0455$). When comparing outcome variables, there were significant differences in ICU length of stay (18.8 vs 23.0 days; $p=0.0371$) and risk of DCI in patients undergoing multiple treatments (OR 3.38; 95% CI 1.07-12.1; $p=0.0456$). There were no differences in hospital length of stay, disposition, mortality, and modified Rankin Score (mRS) at discharge or 3-month follow-up (Table 1).

Conclusions:

Multiple endovascular interventions for vasospasm in aneurysmal SAH patients is feasible and effective. This group of patients is likely to have posterior circulation aneurysms as the cause of their SAH. Additionally, other factors associated with multiple treatments included use of vasopressors, ICP crisis, clinical symptoms of vasospasm, and mechanical intervention with angioplasty. Functional outcomes based on mRS are similar between the groups, although there is increased length of ICU stay and increased risk of DCI in those requiring repeat treatments.

Table 1. Demographic, admission, treatment, and outcome variables of patients undergoing one or multiple endovascular treatments for vasospasm.

		One Treatment (n=37) (%)	>1 Treatment (n=21) (%)	p-value
Age		54.5±10.5	53.0±15.6	0.1811
Male		18 (48.6)	8 (38.1)	0.6711
Race/Ethnicity				0.2990
	White/Non-Hispanic	7 (18.9)	7 (33.3)	0.3383
	African American	24 (64.9)	9 (42.9)	0.1672
	Hispanic	5 (13.5)	4 (19.0)	0.7096
	Asian	1 (2.7)	0 (0.0)	0.9999
	Other	0 (0.0)	1 (4.8)	0.9999
Body Mass Index		29.0±7.3	25.0±5.9	0.0533
Comorbidities				0.3506
	Obesity	14 (37.8)	4 (19.0)	0.1442
	Hypertension	22 (59.5)	12 (57.1)	0.7074
	Diabetes Mellitus	11 (29.7)	2 (9.5)	0.0921
	Chronic Kidney Disease	0 (0.0)	0 (0.0)	0.9999
	Congestive Heart Failure	0 (0.0)	0 (0.0)	0.9999
	Coronary Artery Disease	1 (2.7)	1 (4.8)	0.6834
	Hx of CVA	1 (2.7)	0 (0.0)	0.9999
	Hx of ICH	1 (2.7)	3 (14.3)	0.1322
	Statin use	7 (18.9)	3 (14.3)	0.6544
	Anti-platelet use	4 (10.8)	4 (19.0)	0.3875
	Smoker	8 (21.6)	7 (33.3)	0.3307
Hunt Hess Score (median)		3	3	0.5985
Fisher Grade (median)		4	3	0.9907
Intraventricular Hemorrhage		22 (59.5)	11 (52.4)	0.3944
Admission Heart Rate		82.8	77.1	0.3059
Admission Systolic BP		155.6	158	0.8035
Admission Diastolic BP		81.9	85.8	0.4927
Admission INR		1.03	1.04	0.7144
Admission Hemoglobin		13.9	12.9	0.0733
Admission Platelet Count		245.4	279.2	0.0658
Admission Creatinine		0.83	0.76	0.2830
Admission Glucose		169.3	158.3	0.5192
Admission WBC		14.06	14.8	0.6481
Admission Neutrophil %		79.0	76.4	0.4153
Admission Lymphocyte %		14.7	16.2	0.5849
Admission Neutro:Lymph		8.5	6.5	0.1747
Re-rupture		1 (2.7)	3 (14.3)	0.1322
External Ventricular Drain		28 (75.7)	19 (90.5)	0.1820
Intubation		22 (59.5)	17 (81.0)	0.1010
Decompression		4 (10.8)	3 (14.3)	0.6971
ICP Crisis		5 (13.5)	9 (42.9)	0.0162
Vasopressor use		23 (62.2)	19 (90.5)	0.0371
Aneurysm Clipping		6 (16.2)	1 (4.8)	0.2258
Posterior Circulation		0 (0.0)	6 (28.6)	0.0087
Aneurysm Location				0.0469
	Anterior Comm. A.	11 (29.7)	7 (33.3)	0.7766

	Posterior Comm. A	6 (16.2)	1 (4.8)	0.4034
	Middle Cerebral A.	3 (8.1)	2 (9.5)	0.9999
	ICA Bifurcation	4 (10.8)	2 (9.5)	0.9999
	Other Anterior	4 (10.8)	1 (4.8)	0.6439
	Basilar A.	0 (0.0)	2 (9.5)	0.1270
	Other Posterior	0 (0.0)	4 (19.0)	0.0141
	Angio-negative	9 (24.3)	2 (9.5)	0.2961
Clinical Symptoms		24 (64.9)	19 (90.5)	0.0455
Angioplasty		8 (21.6)	11 (52.4)	0.0195
Days until Treatment		6.2±3.0	5.6±3.2	0.5042
ICU LOS (days)		18.8	23.0	0.0371
Hospital LOS (days)		27.2	33.7	0.2751
DCI		18 (48.6)	16 (76.2)	0.0456
Days until DCI		17.1	20.4	0.3901
Tracheostomy/Gastrostomy		11 (29.7)	3 (14.3)	0.3750
VP Shunt		9 (24.3)	7 (33.3)	0.4729
Disposition				0.2773
	Home	13 (35.1)	3 (14.3)	0.1282
	Acute Rehab	11 (29.7)	8 (38.1)	0.5685
	SNF	9 (24.3)	5 (23.8)	0.9999
	Hospice/Death	4 (10.8)	5 (23.8)	0.1456
mRS at discharge				0.1221
	1	8 (21.6)	1 (4.8)	0.1354
	2	10 (27.0)	4 (19.0)	0.5439
	3	7 (18.9)	6 (28.6)	0.5151
	4	6 (16.2)	1 (4.8)	0.4034
	5	2 (5.4)	4 (19.0)	0.1759
	6	4 (10.8)	5 (23.8)	0.2616
mRS at 3mo				0.2951
	0	5 (15.6)	0 (0.0)	0.1479
	1	10 (31.3)	5 (25.0)	0.9999
	2	5 (15.6)	6 (30.0)	0.1814
	3	4 (12.5)	1 (5.0)	0.6573
	4	3 (9.4)	3 (15.0)	0.6439
	5	1 (3.1)	0 (0.0)	0.9999
	6	4 (12.5)	5 (25.0)	0.2616
mRS >3 at Discharge		12 (32.4)	10 (47.6)	0.2546
mRS >3 at 3mo		8 (25.0)	8 (40.0)	0.2577

CVA: cerebrovascular accident; ICH: intracranial hemorrhage; ICP: intracranial pressure; A: artery; ICA: internal carotid artery; ICU: intensive care unit; LOS: length of stay; DCI: delayed cerebral ischemia; VP: ventriculoperitoneal; SNF: skilled nursing facility; mRS: modified Rankin Score

Keywords: Vasospasm, Vasospasm Intervention, Intra-Arterial Therapy, Angioplasty, SAH

Financial Disclosures: The authors had no disclosures.

Grant Support: None.

Poster

Complete recanalization of Right MCA-M1 occlusion with IV tPA and Argatroban infusion

Odai Abdalla, MD¹, Rashid Ahmed, DM¹, Gene Latorre, DM¹, Lena Deb, CRA II¹

¹*SUNY Upstate Medical University, Syracuse, New York, United States of America*

Introduction:

The Multi-arm Optimization of Stroke Thrombolysis (MOST) is a Single Blinded, Randomized Controlled Adaptive, Multi-arm, Adjunctive-thrombolysis Efficacy Trial in Ischemic Strokes. The study aims at comparing the efficacy and safety of benefits of IV tPA alone, IV tPA with Argatroban and IV tPA with Eptifibatide.

Methods:

We present a case of right MCA -M1 occlusion enrolled under the MOST trial in the Argatroban arm that had significant improvement after unsuccessful mechanical thrombectomy due to tortuous anatomy.

Results:

An 86-year-old male with past medical history of new onset atrial flutter (not on anticoagulation), HTN, and HLD. Patient presented with a left facial droop, dysarthria, and left sided weakness, with NIHSS of 16 on arrival. His last known normal was 30 minutes before arrival to the emergency room. CT head was unremarkable. CT angiogram head and neck revealed a right MCA-M1 occlusion. He met the criteria for IV thrombolysis, and received IV tPA. The patient was enrolled in MOST trial, and received Argatroban bolus, and started on Argatroban infusion for 12 hours. The patient was taken to the IR suite for mechanical thrombectomy. Mechanical endovascular recanalization was attempted, but was unsuccessful -TICI0, due to tortuous anatomy of the arch of the aorta, and right ICA. Despite this, the patient's neurological exam improved after he completed the Argatroban 12 hours infusion, and his NIHSS improved from 16 to 1. Repeated CT angiogram head and neck revealed complete recanalization of right MCA-M1.

Conclusions:

The combination of Argatroban and IV tPA has shown promise, and may produce more complete recanalization than tPA alone. The MOST trial will enable us to compare the safety and efficacy of Argatroban when compared to eptifibatide and IV tPA alone.

Keywords: Acute Stroke

Financial Disclosures: The authors had no disclosures.

Grant Support: None.

Poster

Bilateral Subclavian Steal Syndrome: A Case Presentation

Neil C Suryadevara, MD, MPH¹, Carlos Y Lopez, MD¹, Hesham Masoud, MD¹

¹SUNY Upstate Medical University, Syracuse, New York, United States of America

Introduction:

We detail the presentation and diagnostic workup of a gentleman who was ultimately diagnosed with bilateral subclavian steal syndrome, which is a rare entity¹.

Methods:

This is a case report, which describes the presentation and workup that led to the diagnosis of bilateral subclavian steal syndrome.

Results:

Our patient is a 62 year-old man with multiple vascular risk factors (further detailed below), on apixaban and clopidogrel who presented to the hospital with mesenteric ischemia. Neurology was consulted for his complaint of episodic lightheadedness occurring for months, increasing in frequency as of late. He described a “falling” or “sinking down” sensation both at rest and with the postural change. Three days prior he reported transient left forearm and hand numbness. During episodes in hospital, he was found to be orthostatic and there was report of transient anisocoria. At the time of evaluation by neurology, his exam was non-focal.

His vascular risk factors included hypertension, hyperlipidemia, coronary artery disease, atrial fibrillation, peripheral vascular disease, mesenteric ischemia requiring stenting. He had a history of failed right to left subclavian bypass and left carotid-subclavian bypass. He had a 20 pack year smoking history and quit smoking three years ago.

CT angiography of the head and neck disclosed significant extracranial atherosclerotic disease including bilateral proximal subclavian occlusions (figures 1-2) and stenosis of the bilateral internal carotid arteries and bilateral fetal posterior cerebral arteries. Carotid dopplers demonstrated retrograde flow in bilateral vertebral arteries at rest (figures 3-4). MRI of his brain was not obtained due to an incompatible pacemaker.

Vascular surgery evaluated the patient and given his co-morbidities and failed bypasses, he was not a candidate for surgical bypass. He was maintained on optimal medical therapy, and continued follow up.

Conclusions:

Bilateral subclavian steal syndrome is a rare entity¹ and was diagnosed in this patient with complaint of episodic vague falling sensation, left arm numbness, and concomitant orthostatic hypotension. His symptoms have occurred at rest and while lying flat. Given his multifocal atherosclerotic disease and cerebrovascular variants, his presentation is suspected to be reflective of vertebrobasilar insufficiency in the setting of demonstrated evidence of bilateral subclavian steal syndrome.

Figures for “Bilateral Subclavian Steal Syndrome: A Case Presentation”

Figure 1 – Right subclavian artery near/occlusion

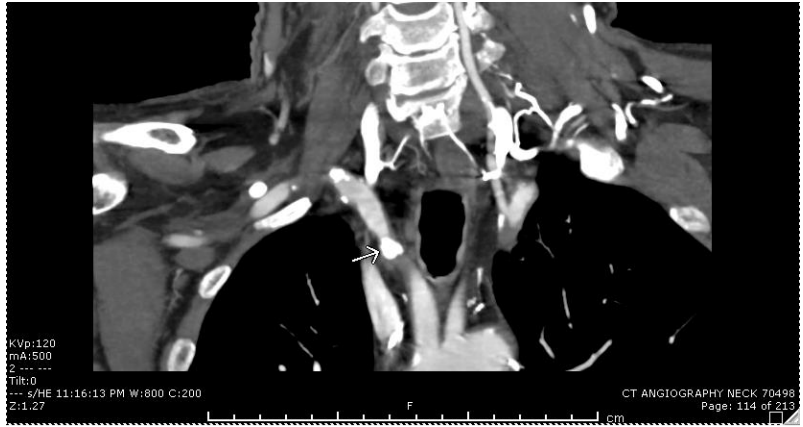

Figure 2 – Left subclavian artery occlusion

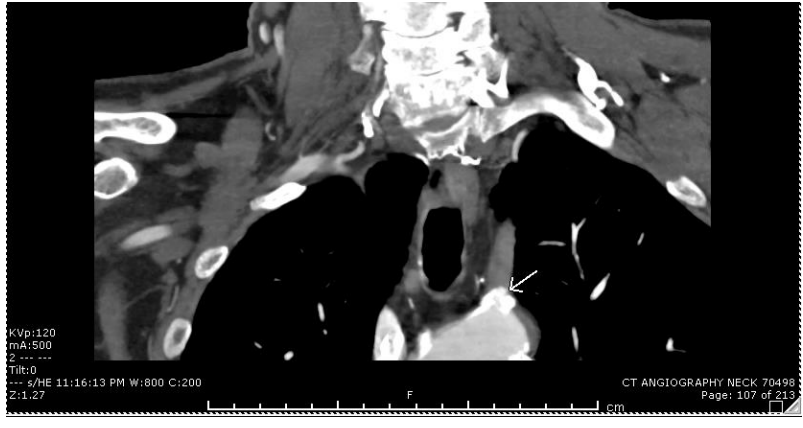


Figure 3 – Right vertebral artery carotid duplex ultrasound demonstrating retrograde flow

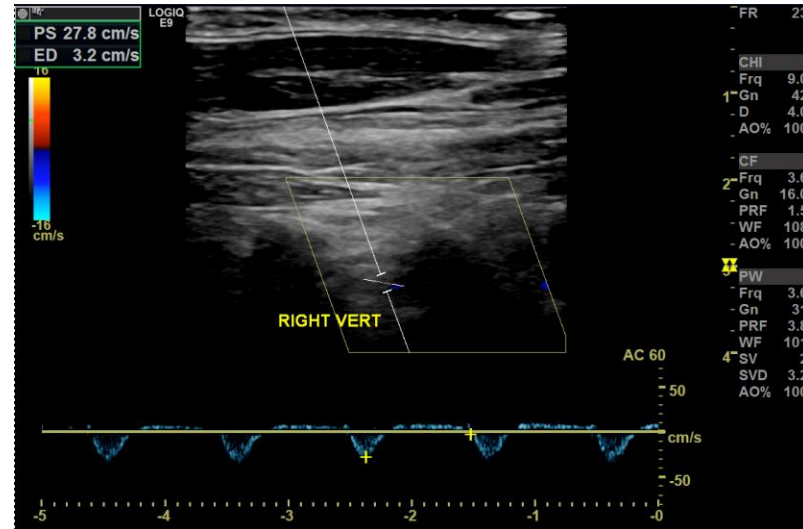
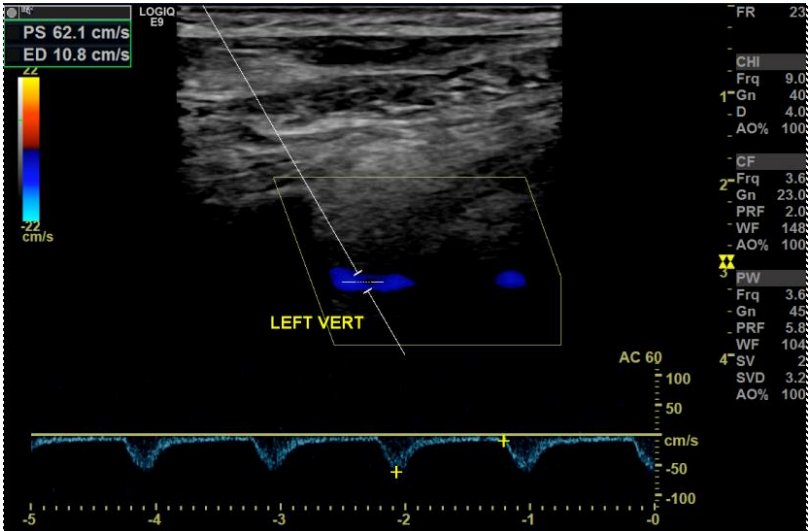


Figure 4 – Left vertebral artery carotid duplex ultrasound demonstrating retrograde flow



Keywords: Subclvaian

Financial Disclosures: The authors had no disclosures.

Grant Support: None.

Poster

Utilization Of Computed Tomography Perfusion Head Imaging For The Determination Of Brain Death.

Hashaam Arshad, MD¹, Iftekhhar Ahmed, MD²

¹*University of Missouri Kansas City, Kansas City, Missouri, United States of America;* ²*Research Medical Center, Kansas City, Missouri, United States of America*

Introduction:

American Academy of Neurology has published an opinion-based guideline for determination of Brain Death (BD) which gives step by step approach with importance given to neurological assessment with further support provided by ancillary testing modalities including electroencephalogram (EEG), cerebral angiography, nuclear scan and transcranial doppler. Computed Tomography Perfusion (CTP) Head is currently not included in ancillary testing. Nowadays CTP Head is becoming commonly available due to its increased use in ischemic stroke management. We present a case in which CTP Head was utilized to support determination of BD.

Methods:

47-year-old female with past medical history of hypertension and cocaine abuse was admitted for encephalopathy and hypertensive emergency. CT Head showed diffuse SAH and hydrocephalus. On the day of admission, she was intubated and underwent ventriculostomy for hydrocephalus. Afterwards she remained comatose although normal physiologic parameters (temperature, systolic blood pressure, electrolytes) were maintained. Neurological assessment showed absent corneal, oculosympathetic, oculocephalic, and oculovestibular responses on cold caloric testing. Apnea test revealed no spontaneous breaths and her PCO₂ rose from 35 to 71 mm of Hg in 10 minutes. EEG showed electrocerebral silence and Somatosensory Evoked Responses (SEPs) revealed absent cortical responses. CTP Head was performed which showed marked decrease in the perfusion all over the brain, prolonged mean transit time values between 10 to 15 seconds and absence of time to peak bilaterally which indicated absent cerebral blood flow. She was subsequently withdrawn from the medical care.

Results:

See Methods above.

Conclusions:

In our case BD was determined following neurological assessment with supporting evidence provided by ancillary testing with EEG and SEPs. CTP Head results were consistent with those of ancillary tests. In conclusion, CTP Head can provide valuable information and consideration can be given to include CTP Head as part of ancillary testing modalities to support determination of BD. This will be useful for clinicians as CTP Head is becoming easily available in hospitals all over United States and can be easily performed on patients requiring ventilator.

Keywords: Angiographic Ct Perfusion, Ct Perfusion, Imaging, Ethics

Financial Disclosures: The authors had no disclosures.

Grant Support: None.

Poster

Disproportionately Extensive Microhemorrhages In A Case Of COVID-19 Encephalopathy

Taylor K Peabody, Dr.¹, Nastajjia Kremetz, Dr.¹, Negar Asdaghi, Dr.¹

¹*University of Miami/Jackson Memorial Hospital, Miami, Florida, United States of America*

Introduction:

Prior studies have observed the presence of microhemorrhages on susceptibility-weighted imaging (SWI) in the setting of COVID-19 as a late finding of the disease. Its presence is associated with poor prognosis, however, it is unclear whether the extent of these lesions directly correlates with clinical presentation. We present a patient without extensive respiratory or cardiac history who was treated for COVID-19 encephalopathy, found to have widespread microhemorrhages.

Methods:

A 61 year old man with history of hypertension and type II diabetes presented with fever, dyspnea, and body aches after testing positive for COVID-19 ten days prior. Following admission, he had a rapid respiratory decline, was treated with remdesivir and dexamethasone, and was intubated for hypoxic respiratory failure with concern for cytokine storm. His hospital course was complicated by septic shock due to MRSA bacteremia (resolved after two days treatment), atrial flutter, and acute kidney injury requiring dialysis. Four weeks later, a non-contrast CT brain was completed for persistent altered mental status after discontinuation of sedation. Exam at this time involved low levels of alertness with only intermittent eye opening and minimal movement of extremities in response to noxious stimuli. CT findings showed multiple hyperdensities within the bilateral cerebral hemispheres and right basal ganglia, initially concerning for septic emboli, although transthoracic echocardiogram did not show enlarged atria or evidence of embolization source such as vegetation or thrombus. SWI sequence on MRI brain without contrast revealed innumerable foci across bilateral cerebral hemispheres, corpus callosum (including splenium), and subcortical white matter with confluence of lesions in several areas (*Figure 1*). Of note, he had received seven days treatment of therapeutic heparin for a small subsegmental pulmonary embolism prior to these findings. This patient was ultimately treated with supportive care with placement of a tracheostomy and PEG tube. He was re-started on sedation with dexmedetomidine for persistent vent dyssynchrony.

Results:

Exam on discharge was performed on sedation and was unchanged from prior. Patient was transferred to a long-term acute-care facility with a modified Rankin score of 5.

Conclusions:

This case illustrates an unusual pattern of extensive and widespread microhemorrhages in the setting of COVID-19. The mechanism of this finding and clinical significance on prognosis remains unclear.

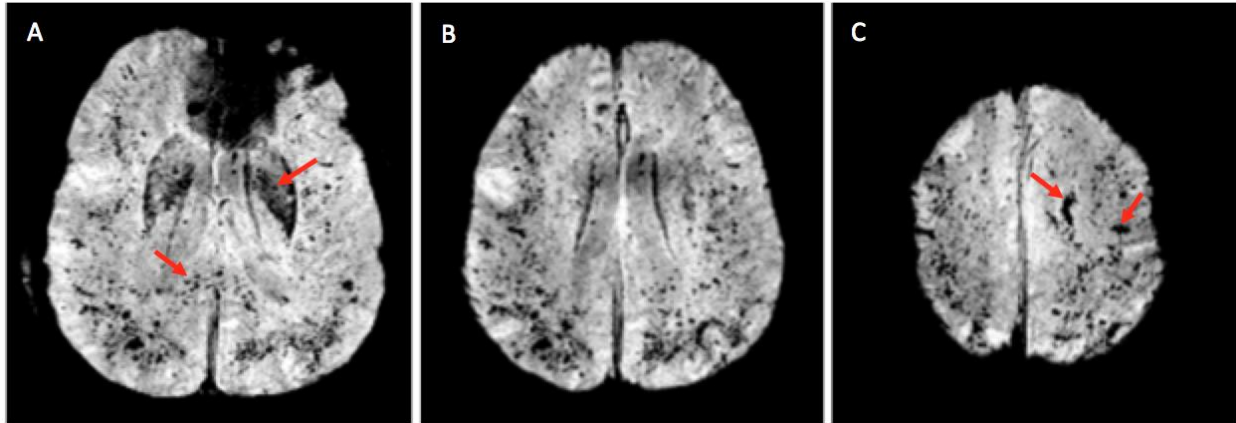


Figure 1. Axial susceptibility-weighted imaging (SWI) of the brain demonstrating extensive microhemorrhages in the (A) corpus callosum/splenium, basal ganglia, and (B) bilateral hemispheres. Confluence of lesions was observed throughout (C).

Keywords: Imaging, Hemorrhage, Cerebrovascular Disease

Financial Disclosures: The authors had no disclosures.

Grant Support: None.

Poster

Acute Quadriplegic Migraine Presenting As Spinal Cord Infarction.

Hashaam Arshad, MD¹, Iftekhhar Ahmed, MD²

¹*University of Missouri Kansas City, Kansas City, Missouri, United States of America;* ²*Research Medical Center, Kansas City, Missouri, United States of America*

Introduction:

Our objective is to describe a very atypical presentation of acute migraine. Acute quadriplegia in migraine has never been described before.

Methods:

We present case of a 47 year old Caucasian female with past medical history of complex migraines who presented to the Emergency Room with complains of sudden onset of quadriplegia. This was initially thought to be secondary to an acute spinal cord infarction. Her mental status and cranial nerves exam were normal. Her motor exam revealed quadriplegia, she was hyper reflexive in all four limbs and had bilateral up going Babinski's sign. Her sensory exam revealed abnormal sensations in C5 distribution. Her basic blood work up including electrolytes, complete blood count and liver function tests were normal. She underwent magnetic resonance imaging of brain, cervical spinal cord, thoracic spinal cord, lumbar spinal cord and spinal angiography which showed no abnormalities. Lumbar puncture was performed and cerebrospinal fluid examination was also within normal limits. Blood work up for auto immune diseases including vasculitis, vasculopathies and paraneoplastic etiology was insignificant. She also had a normal cardiac work up and aortogram. Over the next 24 to 48 hours, the patient showed gradual improvement and on discharge she went home ambulatory with a normal neurological examination. She was started on Topiramate for migraine prophylaxis on discharge. She followed up in clinic three months later and had remained asymptomatic.

Results:

See Methods above.

Conclusions:

Migraine headaches can have variable clinical presentations. We concluded that this was an unusual case of complex migraine with clinical presentation similar to an acute spinal cord infarction. Emergency Room physicians and Vascular Neurologists should take into consideration atypical presentations similar to our case when evaluating patients in the Emergency Room. Correct diagnosis is of utmost importance for accurate and timely treatment.

Keywords: Imaging, MRI, Diagnostic Neuroradiology

Financial Disclosures: The authors had no disclosures.

Grant Support: None.

Poster

Cerebral vasculopathy and large vessel occlusion in the setting of COVID-19: a case report

Nathan DeTurk, MD, MBA¹, Leah Shabo, BS¹, Necrisha Roach, MD¹, Jeffrey Hakim, MD¹, Stephen Capek, MD¹, Ryan Kellogg, MD¹, Andrew Southerland, MD, MSc¹

¹*University of Virginia, Charlottesville, Virginia, United States of America*

Introduction:

There has been an increasing prevalence of both coagulopathy and vasculopathy complicating SARS Co-V2 infection, however neurovascular complications remain poorly understood. There have been a few reports of acute ischemic stroke (AIS) secondary to large vessel occlusion (LVO) complicated by cerebral vasculitis. Here we present a case of an LVO syndrome in the setting of COVID-19 and diffuse cerebral vasculopathy.

Methods:

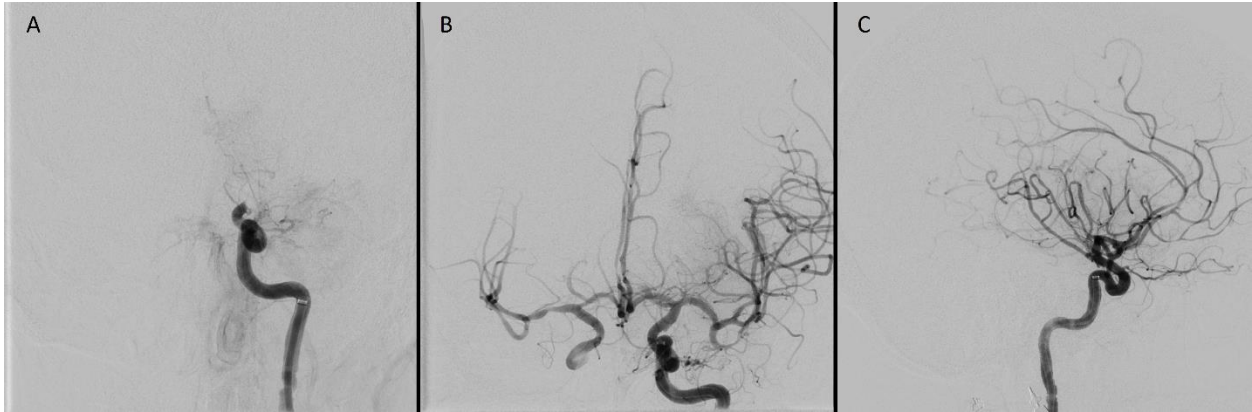
79 yo right handed woman presented with global aphasia, left gaze preference, and right hemiplegia. Notably, she was not on any antiplatelet or anticoagulant at the time of presentation. The patient tested positive for SARS-CoV-2 eight days prior to presentation, with fatigue being her only complaint. Upon evaluation, her initial NIH Stroke Scale score was 22 with a blood pressure of 202/90 mmHg. Initial CT head and CTA head and neck showed a LVO of the intracranial left internal carotid artery (ICA) with extension to the M1 and proximal M2 segment of the left middle cerebral artery (MCA). The patient received alteplase followed by thrombectomy with TIC1 3 reperfusion. Cerebral angiogram revealed diffuse multifocal tapered narrowing throughout the intracerebral vasculature consistent with cerebral vasculopathy (Figure 1). Following her angiogram, she had a transient episode of atrial fibrillation with rapid ventricular rate, suggesting cardioembolism as the likely stroke mechanism. Workup for her vasculopathy including systemic inflammatory markers was otherwise negative. Post-thrombectomy brain MRI demonstrated scattered acute infarcts involving the left thalamus, basal ganglia, and frontotemporal lobes. By hospital day #2, her neurological deficits completely resolved with an NIHSS 0. She was discharged home 48 hours after admission with outpatient therapies and a plan to initiate apixaban for ongoing secondary stroke prevention.

Results:

A: Left ICA terminus occlusion with no filling of the left ACA or MCA. B: After suction thrombectomy, filling of the bilateral ACA and MCA, representing TIC1 3 reperfusion. Narrowing of the right M1, inferior left M2, and distal MCA branches C: Diffuse vascular narrowings throughout the bilateral ACA.

Conclusions:

While the arrhythmogenic risk associated with COVID-19 is still unclear, numerous case reports have documented new onset cardiac arrhythmias such as atrial fibrillation. Additionally, expression of the angiotensin converting enzyme-2 receptor in cerebral endothelial cells indicates a possible mechanism for cerebral vasculopathy and coagulopathy due to SARS CoV-2 infection. Further reports and research is needed to elucidate the various cerebrovascular associations of COVID-19 including cardioembolism, LVO, and cerebral vasculopathy.



Keywords: Acute Ischemic Stroke Intervention, Cerebral Blood Flow, Intra Caranial Stenosis, Angiogram

Financial Disclosures: The authors had no disclosures.

Grant Support: None.

Poster

Hyperosmolar Hyperglycaemic State Precipitating Reversible Cerebral Vasoconstriction Syndrome

Barry T Kweh, MBBS (Honours)¹, Terence Tan, MBBS (Honours)¹, Andrew Morokoff, FRACS¹

¹Royal Melbourne Hospital, Melbourne, Australia

Introduction:

The co-existence of severe headache and reversible angiographically-proven segmental narrowing of cerebral arteries constitutes the criteria for the unifying diagnosis of reversible cerebral vasoconstriction syndrome (RCVS). Although the exact underlying pathophysiological mechanism remains unclear, well-documented triggers include vasoactive medications, alcohol and the postpartum period. This unique case of RCVS precipitated by a hyperosmolar hyperglycaemic state provides an important pathophysiological perspective into a poorly understood vascular and neurological condition.

Methods:

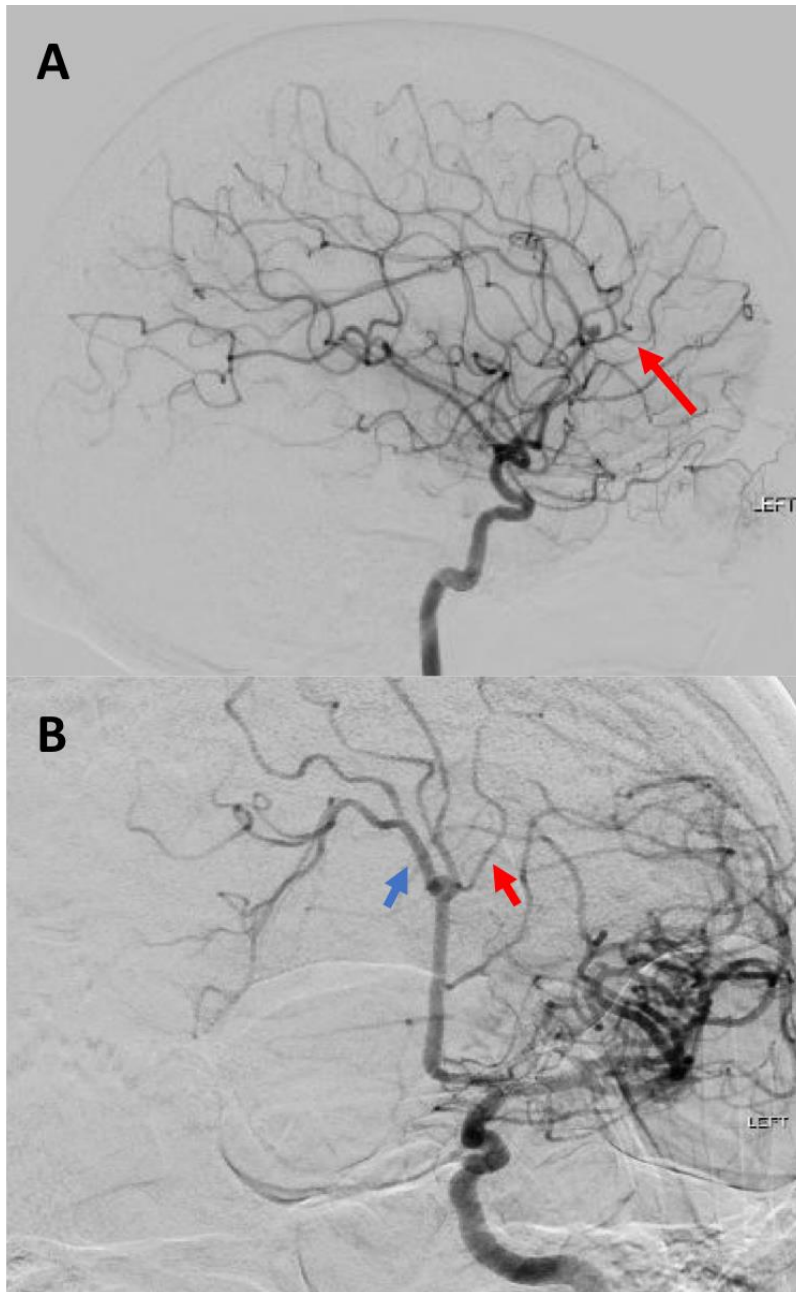
A 54 year old female smoker presented with altered conscious state four days following the commencement of induction chemotherapy for non-Hodgkin's lymphoma of the parotid gland. The chemotherapy regime consisted of 1200mg cyclophosphamide, 20mg dexamethasone, 1000mg obintuzumab, 80mg doxorubicin and 2mg vincristine. A hyperglycaemic hyperosmolar state (HHS) was diagnosed when her serology revealed a serum glucose level of 60 mmol/L, serum osmolarity of 323 mOsm/kg and a pH of 7.37, likely precipitated by high dose dexamethasone. Her past medical history was significant for hypertension alone. On examination, she was disoriented with a Glasgow Coma Scale of 14 without focal neurological deficit.

Results:

Computed Tomography of the brain was performed to investigate her reduced conscious state, and demonstrated subarachnoid haemorrhage within the left Sylvian fissure and right inferior temporal sulcus. CT angiography did not demonstrate any cerebral aneurysm. A history of thunderclap headache only emerged following improvement of her conscious state. Cerebral digital subtraction angiography (DSA) showed angiographic vasospasm of the left anterior cerebral artery (Figure). She was adequately fluid resuscitated and commenced on an intravenous insulin infusion and nimodipine. Delayed Magnetic Resonance Imaging (MRI) of the brain revealed several small acute ischaemic infarcts of the right caudate head, right corona radiata and extreme left frontal lobe, remote to the areas of angiographic vasospasm. Upon follow-up at 6 weeks post-ictus, she had no residual neurological deficit and repeat magnetic resonance angiography demonstrated complete reversal of the previously observed cerebral vasoconstriction.

Conclusions:

Dysregulation of cerebral vascular tone in RCVS is theorised to be due to three main pathophysiological mechanisms: excessive sympathetic nervous system activity, endothelial dysfunction and oxidative stress. A hyperosmolar hyperglycaemic state exacerbates all three.



Keywords: Angiogram, Cerebral Physiology, Stroke, Subarachnoid Hemorrhage, Vasospasm

Financial Disclosures: The authors had no disclosures.

Grant Support: None.

Poster

Ischaemic Peripheral Neuropathy Secondary to Long-Segment Popliteal Artery Occlusion

Barry T Kweh, MBBS (Honours)¹, Fahmi M Jalil, MBBS¹, Edrich Rodrigues, FRACP¹, David Goh, FRACS¹, Tanya Yuen, FRACS¹

¹Royal Melbourne Hospital, Melbourne, Australia

Introduction:

Ischaemic peripheral neuropathy is an often neglected phenomenon that has historically been perceived as rare given the rich arterial collateral supply afforded to peripheral nerves by the vasa nervorum. We report an unusual case of foot drop secondary to long-segment popliteal artery occlusion. Not only does this novel example highlight the importance of thorough clinical assessment, but it also advocates for timely and accurate investigation. Without expedient vessel imaging and revascularisation of the occluded artery in this instance, our reversible vascular cause of neurological compromise would likely have resulted in permanent devastating sequelae.

Methods:

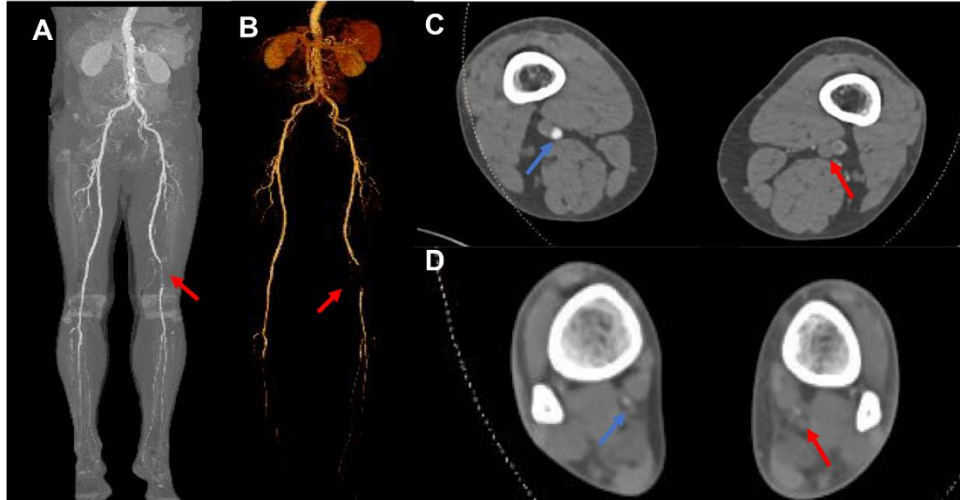
A 60 year-old male smoker presented with a three month history of spontaneous left-sided foot drop on a background of lower limb claudication, rest pain and erectile dysfunction. His past medical history was significant for poorly controlled non-insulin-dependent diabetes mellitus, hypertension and a transient ischaemic attack. On examination he had Medical Research Council (MRC) scale 3/5 dorsiflexion and eversion left foot weakness. The remainder of his neurological examination was normal. His left lower limb was positive for Buerger's test with a reactive hyperaemia accompanied by absent posterior tibial and dorsalis pedis pulses.

Results:

Magnetic Resonance Imaging (MRI) of the lumbar spine revealed mild canal stenosis at L4/5 without significant neural compression. Nerve conduction and electromyography studies demonstrated a left sciatic neuropathy with greater effect on the common peroneal nerve than the tibial nerve localised between the branches of the adductor magnus and common peroneal nerve. Computed tomography angiography (CTA) of the lower limbs demonstrated a 7 cm occlusion of the proximal left popliteal artery (Figure). There was resultant scant flow within the proximal left anterior tibial artery, with occlusion of the distal left anterior tibial and dorsalis pedis arteries. An MRI of the left sciatic, tibial and common peroneal nerves excluded a structural or compressive cause, and highlighted denervation changes in the anterior compartment. He underwent placement of a left popliteal stent with successful reperfusion and subsequent partial recovery of his motor function.

Conclusions:

Ischaemic common peroneal nerve neuropathy secondary to long-segment popliteal artery occlusion is a rare but reversible cause of foot drop. Clinicians should remain vigilant to vascular compromise as a cause of neurological deficit.



Keywords: Angiographic Ct, Collateral, Revascularization, Stenting, Vascular Imaging

Financial Disclosures: The authors had no disclosures.

Grant Support: None.

Poster

Posterior reversible encephalopathy syndrome (PRES) associated with COVID-19

Sofia Lallana, Mrs.¹, Austin Chen, Mr.², Manuel Requena, Mr.¹, Marta Rubiera, Mrs.¹, Anna Sanchez, Mrs.¹, James E Siegler, Mr.³, Marián Muchada, Mrs.¹

¹*Vall d'Hebron University Hospital, Barcelona, Spain;* ²*Cooper Medical School of Rowan University, Camden, New Jersey, United States of America;* ³*Cooper Neurologic Institute, Cooper University Hospital, Camden, New Jersey, United States of America*

Introduction:

The novel human coronavirus disease 2019 (COVID-19) has been associated with a variety of vascular and thrombotic complications as a result of endothelial dysfunction. Such dysfunction in the nervous system has been implicated in patients with posterior reversible encephalopathy syndrome (PRES).

Methods:

We report a case series of 8 patients with COVID-19 and PRES diagnosed at 2 academic medical centers, between March and July of 2020, during the COVID-19 pandemic. All patients had a positive SARS-CoV-2 reverse-transcription polymerase chain reaction (RT-PCR) test on a nasopharyngeal specimen at the moment of developing PRES, as well as COVID-19 symptomatology. Patients met clinical and radiological criteria for PRES. The clinical, laboratory and radiographic data, treatment, and short-term outcomes were retrospectively analyzed.

Results:

Four cases (50%) were women, with a mean age at presentation of 57,9±12 years (36-70 years). Cases 1 to 4, had no medical history, developing PRES 23 days after the COVID-19 diagnosis. Cases 5 to 8, had associated comorbidities, developing PRES 39,5 days after the COVID-19 diagnosis. 5 patients were not hypertensive at presentation (SBP<127 mmHg). All the patients suffered from severe pneumonia, requiring intensive care unit admission and intubation in 7 cases (87,5%), receiving treatment with antiretroviral agents and immunosuppressive therapy (Tocilizumab was administered in 4 cases, 50% of the patients). Initial neurologic symptoms included seizures in 7 patients (87,5%) evolving to refractory status epilepticus in 2 patients (25%), with impaired consciousness in 5 patients (62,5%), focal neurological signs in 3 patients (37,5%) and visual disturbances in 1 patient (12,5%). PRES was confirmed radiographically using brain magnetic resonance imaging in all the patients, with asymmetric T2 prolongation or diffusion changes in 4 cases (50%), extensive fronto-parieto-occipital involvement in 2 cases (25%), vascular irregularities in 1 case (12,5%) and intraparenchymal hemorrhagic transformation in 2 cases (25%). The median length of stay at the hospital was 45,8 days (9-87), with 3 patients (37,5%) being discharged asymptomatic from hospital and 2 patients (50%) remaining with focal neurologic signs at discharge. 2 patients (25%) expired, one patient due to status epilepticus and another patient because of respiratory failure. 1 patient (12,5%) was transferred to another hospital after stabilization, prognosis remains guarded.

Conclusions:

PRES appears to be a rare but serious complication of COVID-19, with associated seizures and clinical morbidity. The inflammatory and endothelial response to the novel human coronavirus, and the use of

immunomodulators that act on vascular endothelial growth factor (VEGF) like Tocilizumab could trigger PRES in patients with no previous comorbidities, and also enhance it in patients with comorbidities associated with PRES developing.

Keywords: Inflammation, Imaging, Cerebral Physiology, Neuromonitoring

Financial Disclosures: The authors had no disclosures.

Grant Support: None.

Poster

A Rare Presentation and Outcome of Vein of Galen Malformation

Andrew J Lee, Resident, PGY3¹, Albert Favate, MD¹, Eduard Valdes, MD

¹*NYU Langone, New York, New York, United States of America*

Introduction:

Vein of Galen malformations (VGM) arise from arteriovenous shunts of primitive choroidal vessels that form during the 6th to 11th week of development. These dilate the vein of Markowski, a precursor to the vein of Galen. VGMs represent 1% of intracranial malformations and 30% of pediatric vascular malformations. Their incidence and natural history are poorly understood in adults due to early identification, poor prognosis of untreated VGMs, and early interventions. Lajunas classified VGMs as choroidal or mural. Choroidal VGMs in particular are often identified on antenatal ultrasound or perinatally due to high output cardiac failure. Patients are rarely asymptomatic until adulthood. A review of all published cases of VGM between 1988 to 2008 only identified 16 patients who presented with VGM in adulthood, with only 1 previously asymptomatic choroidal VGM. Typically, once VGMs are identified AV shunts are embolized when medically appropriate. The following is an adult who presented with worsening migraines in her late 20's who was found to have a choroidal VGM that has been stable despite no intervention.

Methods:

n/a

Results:

Patient presented as a 28 year old female with 5 days of continuous worsening of her migraines. There was no medical history, including heart failure, hydrocephalus, or developmental delay. Her headaches were associated with severe nausea and emesis. Due to an incidentally noted VGM (3.8x2.5x2.5cm) on workup 10 years ago, she was transferred to our institution for management. Her exam was only notable for a new bilateral intention tremor and flat optic discs. NCHCT showed a stably dilated VGM with a newly identified thrombus. MRI/MRA/MRV confirmed the thrombus, but did not show ischemic changes or AV malformations. The patient's headaches were stabilized and her oral contraceptive was held. Patient was started on therapeutic lovenox and discharged with close Neurointerventional follow up. Patient returned several days later due to worsening headaches. Her lovenox was held and she was taken urgently for diagnostic cerebral angiogram. The angiogram revealed a remnant of the limbic arcade and an enlarged torcula suggestive of choroidal VGM, but no other AV shunts. Extensive venous collaterals into the straight sinus were present, suggestive of chronic enlargement. Acute occlusion was suggested by an occluded vein of Galen and dilation of the pericallosal and posterior and lateral choroidal arteries. After extensive discussion, the patient's worsening headaches were thought to be a consequence of her migraines and acute thrombus. As a result she was discharged with headache management and no embolization of her remnant limbic arcade. Patient followed with Stroke service, had 2 subsequent uncomplicated c-sections, and serial imaging only showed minor progression of thrombus.

Conclusions:

Choroidal VGMs are rare in adulthood with only 2 reported in literature—1 embolized, 1 untreated. While VGMs are typically embolized, our patient did not receive embolization as her headache was not thought to be due to her VGM, and she only had a remnant of the limbic arcade. The reason for not having an adverse outcome is unknown. The paucity of AV shunts and good venous collaterals may be key in her benign course.

Keywords: Unruptured, Angiogram, Cerebral Arteriovenous Malformations, Cerebral Sinus And Venous Thrombosis, Head And Neck Malformation Therapy

Financial Disclosures: The authors had no disclosures.

Grant Support: None.

Poster

Challenges in the diagnosis of RCVS: A Headache of a Case.

Maria Martucci, MD¹, Claudia Vallin, DO¹, Alexandra Soriano, MD¹, Michal Obrzut, MD¹

¹*Cleveland Clinic Florida, Weston, Florida, United States of America*

Introduction:

Reversible Cerebral Vasoconstriction Syndrome (RCVS) is a spectrum of conditions poorly characterized in the literature. In recent years, awareness of this condition has increased within the medical community. Despite this, RCVS remains unknown to many physicians leading to delayed diagnosis or administration of medications that can exacerbate vasospasm, causing significant morbidity and mortality. The objectives of this case report are to increase awareness of RCVS, and to emphasize the importance of early diagnosis and treatment.

Methods:

Report a case of a 37-year-old female with a past medical history of migraines and depression who presented to the Emergency Department (ED) with a new ischemic stroke and subarachnoid hemorrhage (SAH) in the setting of two weeks of recurrent thunderclap headaches.

Results:

37-year-old right-handed female with past medical history of migraines and depression on sumatriptan and citalopram who presented to the ED with a two-week history of disabling headaches, described as episodic and 10/10 in intensity. Other symptoms included: nausea, vomiting, neck pain, photophobia and phonophobia. Three days prior, she developed right lower extremity numbness and weakness. She sought medical attention on six different prior occasions: Three times in two different EDs, an urgent care facility, and she had been evaluated by her primary care physician (PCP) and her psychiatrist. Extensive imaging had been performed at an outside ED including a CT of the brain, CTA head and neck, and MRI/MRA of the brain. All imaging studies were reported normal. The patient's PCP recommended increasing the sumatriptan and following with a neurologist. Her psychiatrist recommended increasing the citalopram because her mood seemed to have worsened due to persistent headaches. Upon evaluation in our ED, she appeared tired, kept her eyes closed due to photophobia, and vomited at least twice. She had multiple episodes of short-lasting intense thunderclap headaches with associated tachycardia (rate in the 140's). On neurological examination, her right lower extremity demonstrated absence to all sensory modalities and 0/5 motor strength. CT of the brain was suspicious for SAH, which was confirmed with a lumbar puncture. MRI of the brain the following day showed a small acute infarct in the left corona radiata. 4-vessel angiography showed focal narrowing throughout the anterior and posterior circulation consistent with vasculopathy. She was diagnosed with RCVS and treated with Verapamil. Her headaches resolved. She was as referred for physical therapy for right lower extremity weakness. On follow up, she had regained full neurological function

Conclusions:

This case illustrates the importance of early diagnosis and high clinical suspicion for RCVS in order to avoid complications and to prevent administration of medications known to exacerbate

vasoconstriction. Additionally, it demonstrates the need to educate ED and general practitioners on considering RCVS as part of their differential diagnosis.

Keywords: Subarachnoid Hemorrhage, Angiogram, Vasospasm, Cns Vasculitis, Stroke

Financial Disclosures: The authors had no disclosures.

Grant Support: None.

Poster

Peduncular Hallucinosi s after a Thalamic Stroke

Mohammad Ali Shahab, M.B.B.S., Resident¹, Rashid Ahmed, MD, Resident¹, Mina H Michael, MD, Resident¹, Navreet Kaur, M.B.B.S., Resident¹, Sutanaya Pal, MD, Resident¹, Hesham Masoud, M.B.B.CH., Attending¹

¹*SUNY Upstate University Hospital, Syracuse, New York, United States of America*

Introduction:

Peduncular hallucinosi s is a rare form of hallucinations consisting of vivid and non-threatening colorful visual hallucinations. It was first described by French neurologist Jean Lhermitte in 1922. They sometimes include distorted images of animals and people. Peduncular hallucinosi s has been described after vascular and infective lesions of the mesencephalon and thalamus.

Methods:

We present a case of peduncular hallucinosi s after a right thalamic infarction

Results:

This is the case of a 75 year old Caucasian gentleman with a past medical history of hypertension and hyperlipidemia who presented as a transfer from an outside hospital with transient left facial palsy and upper and lower extremity weakness. His symptoms resolved on arrival. CTA head and neck revealed focal filling defect in the basilar artery and a right PCA occlusion at its origin. MRI brain without contrast revealed a right thalamic infarct.

The patient had vivid hallucinations including his wife sleeping on his hospital bed, seeing his favorite book on the table while he had left it at home, seeing his dogs, and a TV show on his room television while it was off. He was easily redirectable, and the hallucinations resolved over 2 days without pharmacological intervention.

Conclusions:

In cases of thalamic, midbrain, or peduncular infarctions, stroke neurologists should be cognizant of the possibility of peduncular hallucinosi s and inquire about hallucinations. New onset hallucinations in a patient with no prior psychiatric history presenting with concerns for stroke should prompt neurologists to strongly consider peduncular hallucinosi s.

Keywords: Acute Stroke, Ischemic Stroke

Financial Disclosures: The authors had no disclosures.

Grant Support: None.

Poster

Papillary Fibroelastoma: A Cause of Cardioembolic Stroke

Smriti Bhatia, Resident¹, Stan Naydin, Neurologist Attending², Sonela Skenderi, Cardiologist Attending¹

¹Nazareth Hospital, Philadelphia, Pennsylvania, United States of America; ²Global Neurosciences Institute, Upland, Pennsylvania, United States of America

Introduction:

Primary tumors of the heart are rare. Based upon the data of 22 large autopsy series, the frequency of primary cardiac tumors is approximately 0.02%--corresponding to 200 tumors in 1 million autopsies [1]. Papillary fibroelastoma is the second most common primary tumor of the heart and most commonly involves the cardiac valves. Mostly they are incidental findings by routine trans-esophageal echocardiography or on autopsy, very rarely causing any symptoms. Multiple papillary fibroelastomas are extremely rare [2]. We report a case with multiple papillary fibroelastomas which caused multiple strokes. Upon surgery, multiple masses were found on both sides of the aortic valve.

Methods:

A 53 year old Hispanic male with past medical history of diverticulitis, dyslipidemia, non-insulin-dependent diabetes mellitus was admitted with left-sided facial and upper extremity numbness for 3 days. He mentioned similar symptoms 1 month prior with left-sided weakness for 30 minutes with spontaneous resolution. CT scan of the brain revealed subtle 10 mm focus of hypodensity at the right frontal convexity. MRI of the brain revealed mild periventricular hypodensity representing small ischemic change with tiny subcortical lacunar infarcts and areas of increased T2 and flair signal in the cortex of the right fronto-parietal convexity which showed restricted diffusion- indicative of several previous ischemic events in multiple vascular distributions, concerning for central etiology of stroke

Results:

Trans-Esophageal Echocardiography revealed multiple aortic masses, largest being 1 cm with differential of vegetation or myxoma. While inpatient, he had 2 additional episodes of Transient Ischemic Attacks. The patient needed to be heparinized until surgical resection by cardiothoracic surgery. Intraoperatively, he was found to have a 7 x 7 mm soft friable mass on the right coronary leaflet and another approximately 1 mm similar-appearing masses found on the undersurface of the right leaflet, the surface of the non-coronary leaflet, and the underside of the non-coronary leaflet, total of 6 masses. On pathology report 4/6 aortic valve masses were diagnosed as papillary fibroelastoma, 1 was diagnosed as valve tissue with fibromyxoid change, and 1 insufficient for diagnosis. The frequency of embolism is equivalent even if papillary fibroelastoma attached to either side of the AV [3].

Conclusions:

Surgical treatment is usually indicated especially for aortic fibroelastoma because of the high associated risk of cerebrovascular and chest diseases [4]. The recent evolution of echocardiography will promote the chance of establishing a preoperative diagnosis of this lesion. However, it is not possible to differentiate fibroelastoma from other lesions, including malignancies, by echocardiography alone. Surgery is recommended for patients who have had embolic events or complications directly related to tumor mobility and those with highly mobile or large (≥ 1 cm) tumors. Recurrence of cardiac papillary

fibroelastoma following surgical resection has not been reported [5]. In our case, there were no reported symptoms after 10 months of surgical intervention. This case also emphasizes the importance of multi-disciplinary approach for the diagnosis and management of papillary fibroelastoma . Given the known risk of embolic events associated with solitary PFE, we can infer a higher risk systemic embolization in patients with multiple lesions.

Keywords: Diagnostic Neuroradiology, Ischemic Stroke, Embolization, Cerebrovascular Disease, TIA

Financial Disclosures: The authors had no disclosures.

Grant Support: None.

Poster

Coronavirus Disease 2019 (COVID-19) Related Acute Ischemic Stroke: A Case Report

Umar Farooque, Resident Physician¹, Umar Farooque, Resident Physician¹, Sohaib Shabih, Medical Officer², Sundas Karimi, Resident Physician³, Ashok K Lohano, Assistant Professor⁴, Saurabh Kataria, Research Assistant⁵

¹Dow Medical College, Dow University of Health Sciences, Karachi, Pakistan; ²Patel Hospital, Karachi, Pakistan; ³Combined Military Hospital, Karachi, Pakistan; ⁴Peoples University of Medical and Health Sciences for Women, Nawabshah, Pakistan; ⁵University of Missouri Health Care, Columbia, Missouri, United States of America

Introduction:

Coronavirus disease 2019 (COVID-19) is an active worldwide pandemic with diverse presentations and complications. Most patients present with constitutional and respiratory symptoms. Acute ischemic stroke remains a medical emergency even during the COVID-19 pandemic.

Methods:

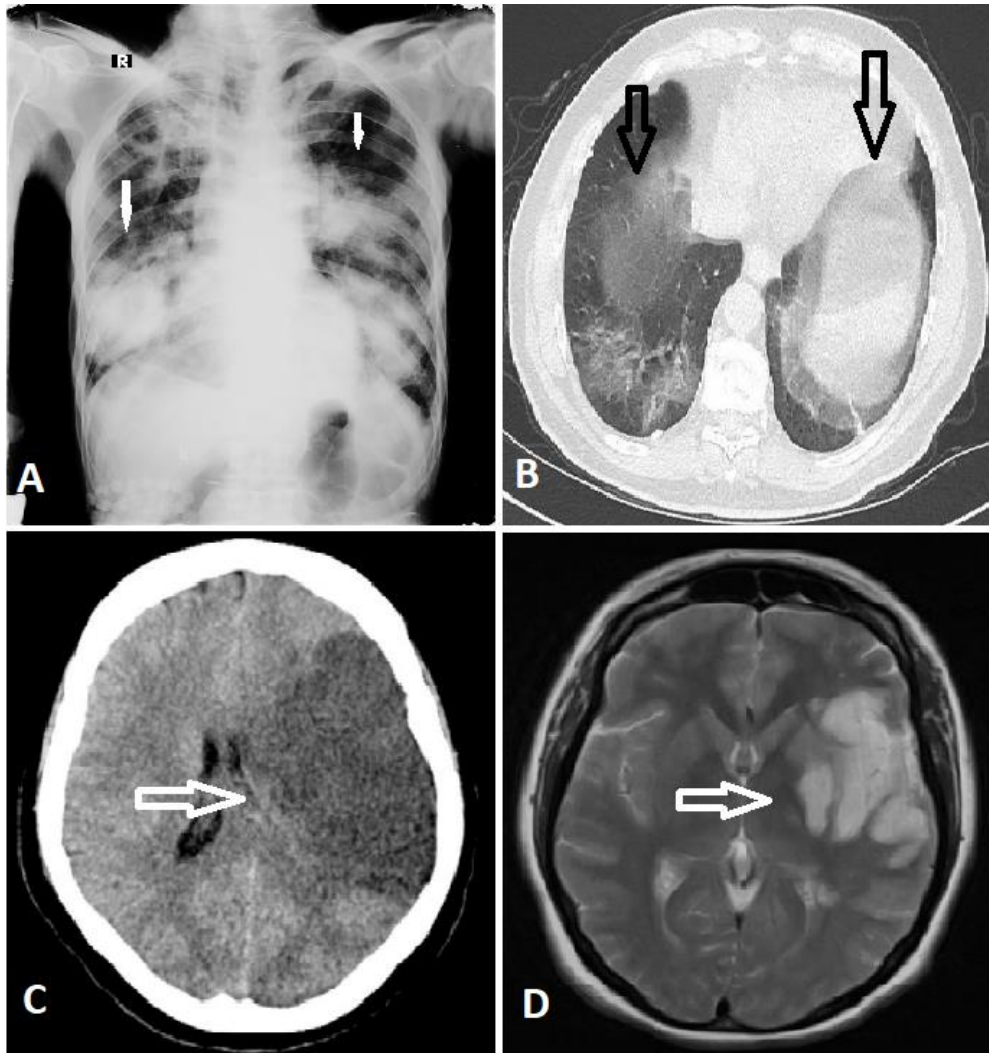
Here we present a case of a patient with COVID-19 who presented with acute ischemic stroke in the absence of common risk factors for cerebrovascular accidents.

Results:

A 70-year-old male patient, with no prior comorbidities, presented to the emergency department (ED) with fever, cough, and shortness of breath for four days, and altered level of consciousness and right-sided weakness with the sensory loss for one day. On examination, the patient had a score of 8/15 on the Glasgow coma scale (GCS). There was a right-sided sensory loss and weakness in both upper and lower limbs with a positive Babinski's sign. The pulmonary examination was remarkable for bilateral crepitation. On blood workup, there was leukocytosis and raised c-reactive protein (CRP). Thyroid-stimulating hormone (TSH), vitamin B12, and hypercoagulability workup were normal. Transthoracic echocardiography was also normal. COVID-19 polymerase chain reaction (PCR) detected the virus. Chest x-ray showed infiltrations in the left middle and both lower zones of the lungs in the peripheral distribution. Computed tomography (CT) scan of the chest showed peripheral and mid to basal predominant multilobar ground-glass opacities. Computed tomography (CT) scan of the head showed a large hypodense area, with a loss of gray and white matter differentiation, in the left middle cerebral artery territory. Magnetic resonance imaging (MRI) of the head showed abnormal signal intensity area in the left parietal region. It appeared isointense on T1 image and hyperintense on T2 image. It also showed diffusion restriction on the diffusion-weighted 1 (DW1) image with corresponding low signals on the apparent diffusion coefficient (ADC) map. These findings were consistent with left middle cerebral artery territory infarct due to COVID-19. The patient was intubated in the ED. He was deemed unfit for thrombolysis and started on aspirin, anti-coagulation, and other supportive measures.

Conclusions:

Patients with COVID-19 should be evaluated early for neurological signs. Timely workup and interventions should be performed in any patient suspected of having a stroke to reduce morbidity and mortality.



Keywords: Ischemic Stroke, Acute Stroke, Stroke, MCA, Cerebrovascular Disease

Financial Disclosures: The authors had no disclosures.

Grant Support: None.

Poster

New lessons in COVID-19 and Stroke: Cases in South Florida

Gabriela Perez, Author¹, Hyder Tamton, Resident Author², Mina Rizk, Resident Author², Jacqueline Gonzalez, ARNP¹, Roberto Sanchez, Attending¹, Ariol Labrada, Attending¹, Nils Mueller-Kronast, Attending³, Ali Malek, Attending³, Wilson Cueva, Attending³, Jose Valerio, Attending³, Anthony Alvarado-Ortiz, Fellow³, Sonal Mehta, Attending³, Ritesh Kaushal, Attending³

¹Palmetto General Hospital, Hialeah, Florida, United States of America; ²Larkin Community Hospital, South Miami, Florida, United States of America; ³Advanced Neuroscience Network, Hialeah, Florida, United States of America

Introduction:

These are the first cases describing cryptogenic strokes in patients with recent diagnosis of COVID-19 in South Florida. An association between COVID-19 and stroke is postulated.

Methods:

This is a case series of five patients with COVID-19 diagnosis who developed acute stroke secondary to large vessel occlusion (LVO) at varying times in their infectious clinical course. One patient was female. Two patients were Hispanic, two patients were African American, and one patient was Caucasian. Age range was 59 to 74 years old. The patients were treated with medical management, thrombolysis, and/or mechanical thrombectomy at comprehensive stroke centers in South Florida. Ethics approval and informed consent was not obtained as this is an observational report that does not disclose any patient identifiers.

Results:

Two patients had significant improvement in their neurologic symptoms, one patient remains in critical care, and 2 expired. Patients with distal LVO had lower levels of inflammatory markers.

Conclusions:

Our data shows an association of LVO in COVID-19 patients with elevated inflammatory markers, more specifically, elevated CRP and d-dimer levels. Higher levels of inflammation and larger clot burdens were apparent in patients with more proximal, as opposed to distal, LVO. Further studies with greater sample size are needed to determine significance of LVO in COVID-19 patients and for how long a patient is at risk for LVO based on levels of inflammation.

Table i. Characteristics of five stroke patients with COVID-19

	Patient 1	Patient 1 (2nd admission)	Patient 2	Patient 3	Patient 4	Patient 5
Age	59	59	72	68	71	74

Biological sex	F	F	M	M	M	M
Race/ Ethnicity	White/ Hispanic	White/ Hispanic	White/ Hispanic	White/ Caucasian	African American	African American
Risk Factors for Stroke	HLD	HLD	CAD, ICH, DM, tobacco use	HTN, HLD, previous stroke	HTN, DM	HTN, HLD, DM, AFib, previous stroke
NIHSS Initial	21	0	15	30	12	26
MRS Initial	4	0	5	5	4	5
NIHSS on discharge	0	0	10	18	4	25
MRS on discharge	0	0	5	5	0	5
In hospital medications	ASA, HD Statin	ASA, HD Statin, FD A/C	DAPT, HD Statin, FD A/C	ASA, HD Statin	tPA	HD Statin, FD A/C
Discharge medications	ASA, HD Statin	ASA, HD Statin, FD A/C	NA	NA	ASA, HD Statin	NA
Disposition	DC home	DC home	ICU	deceased	DC home	deceased
Vascular territory	MCA	PCA	PICA	MCA and bilateral ACA	MCA	MCA and ACA
Mechanism of Stroke	Proximal LVO	Distal LVO	Cryptogeni c	Proximal LVO	Distal LVO	Cardioembo lic
Acute stroke treatment	MT	Medical Managemen t	Medical Managemen t	MT	Systemic tPA	MT
Days from initial COVID sx to stroke	17	24	1	NA	14	14

WBC ($\times 10^9/L$) ¹	8.2	5.4	21.2	6.7	7.6	4.4
Platelet count ($\times 10^9/L$) ²	416	326	292	223	256	141
Ferritin ($\mu g/L$) ³	290	116	611	104.3	NA	395
D-dimer (nmol/L) ⁴	NA	12.59	11.24	21.36	>49.28	>49
Sedimentation Rate (mm/h) ⁵	60	50	101	NA	50	NA
CRP (mg/L) ⁶	151	90	>2700	105.6	60.5	23.4
Troponin level ($\mu g/dL$) ⁷	Not detected	Not detected	elevated	elevated	Not detected	NA
Lactate Dehydrogenase (LDH) ($\mu kat/L$) ⁸	NA	NA	423	5.08	3.84	341

*Laboratory findings are on admission of the patient to the hospital and values have been converted to standardized units (SI).

†The National Institute of Health Stroke Scale (NIHSS) ranges from 0 to 42 with higher numbers correlating with greater severity of neurologic deficits and impairments.

‡The Modified Rankin Scale (MRS) ranges from 0-6 with higher numbers correlating with greater numbers correlating to greater degrees of disability.

§Reference Ranges: ¹ Patient 1-5 (5.5 to 11 $\times 10^9/L$). ² Patient 1-2 (130-450 $\times 10^9/L$), Patient 3-5 (150-400 $\times 10^9/L$). ³ Patient 1-2 (11-264 $\mu g/L$), Patient 3-5 (17.9-464 $\mu g/L$). ⁴ Patient 1-2 (0-1.26 ng/mL), Patient 3-5 (0-2.74 nmol/L). ⁵ Patient 1-5 (0-20 mm/h). ⁶ Patient 1-2 (0-10 mg/L), Patient 3-5 (<0.5 mg/L). ⁷ Patient 1-2 (0.012-0.034 $\mu g/dL$), Patient 3-5 (<0.01 $\mu g/dL$). ⁸ Patient 1-2 (2-4.1 $\mu kat/L$), Patient 3-5 (2.25-3.75 $\mu kat/L$).

| | Coronavirus testing was performed with polymerase chain reaction (PCR) protocol at the respective laboratory of each center.

Keywords: Stroke, Mechanical Thrombectomy, Ischemic Stroke, Thrombolytics, Acute Ischemic Stroke Intervention

Financial Disclosures: The authors had no disclosures.

Grant Support: None.

Poster

Safety Of Off-label Oral Glyburide In Malignant Hemispheric Infarctions: A Single-center Quality Improvement Study

Mark E Heslin, B.S.¹, Jesse M Thon, M.D.², Lauren Thau, B.S.¹, Ameena Rana, B.S.¹, Ryna Then, M.D.², Tudor G Jovin, M.D.², James E Siegler, M.D.²

¹Cooper Medical School of Rowan University, Camden, New Jersey, United States of America; ²Cooper University Hospital, Camden, New Jersey, United States of America

Introduction:

Following the results of the GAMES-RP trial¹, which showed intravenous glyburide can safely reduce cerebral edema following stroke, our center implemented a quality improvement (QI) initiative using off-label glyburide (2.5mg PO BID x 3 days) to prevent malignant cerebral edema in patients at risk.

Methods:

Consecutive adults > 18 years of age with large hemispheric infarction at our center (9/20/2019-6/20/2020) were treated with off-label glyburide per an institutional protocol. In this interim analysis, we report the safety (use of D50 rescue, discontinuation of drug due to hypoglycemia <50mg/dL) and efficacy outcomes (midline shift, 90-day mRS) of patients with anterior circulation infarcts, as compared to the control arm of the GAMES-RP trial using a two-sample test of proportions.

Results:

Seventeen patients with anterior hemispheric stroke received glyburide (mean age of 71 years [SD 14], median NIHSS 19 [IQR 16-24], mean initial infarct volume on head CT of 122cc [SD 68]). Demographic, clinical, and radiographic findings were well-matched to GAMES-RP controls (Table), except for the presence of internal carotid artery occlusion being twice as common (63% vs 36%, p=0.07). One patient developed hypoglycemia (6%) with the need to discontinue glyburide. Treated patients had numerically less midline shift when compared to historic controls (median 4 vs. 8.5mm). Comfort measures were pursued in 9 patients (47%), permitting long-term follow-up of 8 patients for whom the median 90-day mRS was 5 (IQR 4-6, n=6).

Conclusions:

In this interim analysis of a single-center QI initiative, glyburide was safe. Treated patients had severe deficits and large infarcts, more than half of whom opted for comfort measures, with poor long-term functional outcomes among remaining patients. Notably, the midline shift decreased by more than 50% compared to well-matched historic controls. Off-label use of glyburide will continue to be used at our center in light of these safety profile findings.

	GAMES-RP control (n=36)	Glyburide (n=17)	p-value
Age, mean y (SD)	63 (9)	71 (14)	-
Female, no. (%)	10 (28)	8 (47)	0.17
Pre-morbid mRS, median (IQR)	-	0 (0-2)	-
Past medical history, no. (%)			
Prior stroke	4 (11)	1 (6)	0.56
Diabetes	7 (19)	4 (24)	0.67
Hypertension	24 (67)	12 (71)	0.77
Dyslipidemia	20 (56)	11 (65)	0.53
Coronary artery disease	4 (11)	2 (12)	0.91
Atrial fibrillation	14 (39)	7 (41)	0.89
Stroke etiology, no. (%)			
Cardioembolism	18 (50)	7 (41)	0.54
Large artery disease	9 (25)	5 (29)	0.76
Small vessel disease	0 (0)	0 (0)	-
Other	4 (11)	3 (18)	0.48
Unknown	5 (14)	2 (12)	0.84
Baseline lesion volume, mean cm ³ (SD)	162 (49)	122 (68)	-
Baseline ASPECTS, median (IQR)	-	7 (4-9)	-
Internal carotid artery occlusion, no. (%)	13 (36)	10 (63)	0.07
NIHSS, median (IQR)	21 (17-23)	19 (16-24)	-
Safety Outcomes			
Glucose <55 mg/dL, no. (%)	0 (0)	1 (6)	0.14
D50 ampule rescue, no. (%)	-	1 (6)	-
Drug discontinuation due to safety concern, no. (%)	-	1 (6)	-
Efficacy Outcomes			
Maximum midline shift, median mm (IQR)	8.5 (5.0-14.2)	4 (3-13)	-
Decompressive craniectomy, no. (%)	8 (22)	3 (27)	0.69
DHC not performed due to clinical futility, no. (%)	-	3/14 (21)	-
DHC not needed due to improvement, no. (%)	-	2/14 (86)	-
DHC not done due to comfort care measures, no. (%)	-	9/14 (64)	-
mRS at 90 days, median (IQR)	-	6 (6-6) [n=15]	-
mRS at 90 days if comfort measures not pursued, median (IQR)	5 (4-6)	5 (4-6) [n=6]	-
mRS 0-4 at 90 days, no. (%)	-	3/15 (20)	-
mRS 0-4 at 90 days if comfort measures not pursued, no. (%)	17 (47)	3/6 (50)	0.89
Mortality at 90 days, no. (%)	-	12/15 (80)	-
Mortality at 90 days if comfort measures not pursued, no. (%)	13 (36)	3/6 (50)	0.51

Keywords: Ischemic Stroke

Financial Disclosures: The authors had no disclosures.

Grant Support: None.

Poster

Normal Brain with an 'abnormal' MRI

Nurose Karim, MD¹, Ajaz Sheikh, MD²

¹*University of Texas Southwestern Medical Center, Dallas, Texas, United States of America;* ²*University of Toledo Medical Center, TOLEDO, Ohio, United States of America*

Introduction:

Not all unusual images are pathological. The purpose of this case is to present a very unusual brain image with no clinical correlation.

Methods:

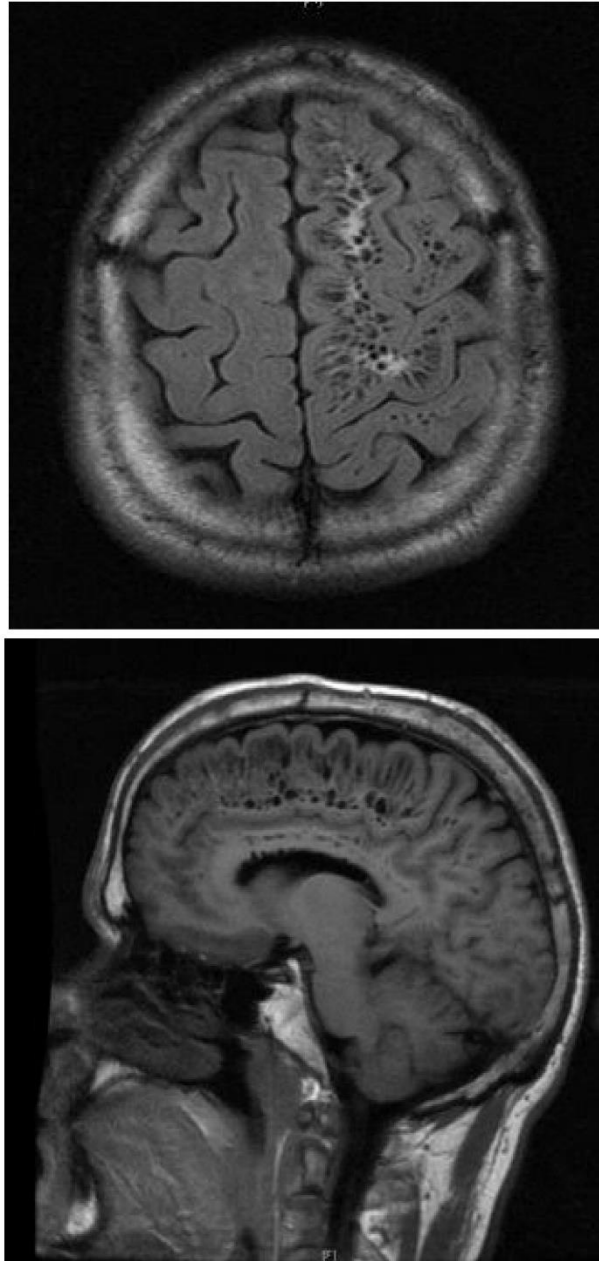
40 Year-old man with no past medical history presented after an episode of syncope with fall and limb shaking. Routine electroencephalogram was within the normal limit. MRI brain with and without contrast showed multiple cystic cavities, with scant, patchy gliosis, located almost exclusively in the left hemispheric white matter and basal ganglia. CT-angiogram of head and neck did not show any vascular pathology. Imaging suspicion was raised for neurocysticercosis, mucopolysaccharidosis, spongiform encephalopathy and extensive cystic tumor, for which he underwent an extensive workup, all of which were unremarkable. Careful review of the history revealed similar findings on imaging done two years prior, for some unrelated reason. The imaging findings were consistent with extensive Virchow-Robin spaces (VRS), which is a benign finding. He was discharged home, with annual follow ups, and has been stable since.

Results:

Dilated Virchow–Robin spaces (dVRS) are incidental imaging findings with a prevalence rate of 1.6–3% in healthy individuals. Several congenital, vascular, infectious and neoplastic processes could be easily confused with dilated perivascular spaces. The etiology is still a matter of debate; fibrosis and obstruction of lymphatic drainage pathways, myelin loss, ex-vacuo dilatation secondary to brain atrophy, or alterations of arterial wall permeability are some of the proposed pathogenic mechanisms. The fact these spaces occupied a significant portion of a hemisphere without causing any obvious symptoms in our patient, makes this a very challenging scenario. VRS are defined on the basis of their shape: irregular or ectatic perivascular spaces are considered "dilated", irregular and linear perivascular spaces are considered non-dilated. They can occur in the following locations: Type 1 VRS in the basal ganglia, Type 2 VRS in the supratentorial white matter space and Type 3 VRS in the midbrain. The pathological relevance of VRS is questionable.

Conclusions:

VRS are considered a benign finding on brain imaging. Extensive VRS may present a clinical and imaging challenge, especially in patients presenting with neurological symptoms, that may be unrelated to them. Clinicians should keep this important imaging finding in mind to avoid unnecessary expensive workup.



Keywords: Vascular Imaging, Basic Sciences, Epidemiology

Financial Disclosures: The authors had no disclosures.

Grant Support: None.

Poster

Assessing the Utility of Vasomotor Reactivity Studies in Identifying Symptomatic Vasculopathy in Moya Moya

Sishir Mannava, MD¹, Whitney Mayberry, MD, CPA¹, Sebastian Koch, MD¹, Amer M Malik, M.D., M.B.A., FAHA, FSVIN¹

¹University of Miami Miller School of Medicine, Miami, Florida, United States of America

Introduction:

Vasomotor reactivity studies (VMRS) are a non-invasive ultrasound-based method of assessing cerebral autoregulation after a vasodilatory stimulus. In this present study, we aim to add to the limited literature on the use of VMRS in Moya Moya disease as well as to compare carbon dioxide (CO₂) challenge to breath holding index (BHI) to identify which method better correlated with symptomatic vasculopathy and affected cerebral hemisphere.

Methods:

We retrospectively analyzed patients with concern for cerebral vasculopathy from idiopathic Moya Moya disease or Moya Moya syndrome (sometimes referred to as “secondary” Moya Moya) specifically analyzing those patients who initially had baseline vasomotor reactivity studies (VMRS) conducted with either BHI or CO₂ challenge, or both. Baseline demographic data was collected and VMRS were analyzed to assess the correlation between CO₂ challenge or BHI results and ability to identify areas of symptomatic vasculopathy and affected cerebral hemisphere.

Results:

From a total of 61 Moya Moya patients, 44 patients had either CO₂ or BHI VMR. Regarding patient demographics, mean age was 44± 16 years, 30 (73%) were women, 18 (43%) had hypertension, 8 (20%) had DM, and 13 (31%) had dyslipidemia. The mean VMR in the asymptomatic hemisphere was 58 ±22% and in the symptomatic hemisphere was 34 ±22% (p<0.0001). The mean BHI in the asymptomatic hemisphere was 0.78 ± 0.51 and in the symptomatic hemisphere was 0.35 ±0.51. A total of 57 hemispheres were available for CO₂ challenge and 46 hemispheres were available for BHI to assess the correlation between the symptomatic hemisphere and VMRS. An event tree analysis (ETA) was calculated to correlate VMR and BHI with the symptomatic hemisphere. For VMR the ETA was 0.41 and for BHI it was 0.39 suggesting moderate and similar correlation for both measures to assess the symptomatic hemisphere.

Conclusions:

Vasomotor reactivity studies are a reasonable, non-invasive method for identifying symptomatic or affected cerebral hemisphere in Moya Moya patients, with similar correlation between CO₂ challenge vs BHI studies.

Keywords: Vascular Imaging, Ischemic And Hemorrhagic Stroke, Cerebral Blood Flow, Ultrasound, Transcranial Doppler

Financial Disclosures: The authors had no disclosures.

Grant Support: None.

Poster

Bow Hunter's Syndrome: Case Report and Review of Literature

Katherine W Zerebiec, MD¹, Scott B Raymond, MD, PhD¹, Brandon D Liebelt, MD¹

¹*University of Vermont Medical Center, Burlington, Vermont, United States of America*

Introduction:

Bow hunter's syndrome, or rotational vertebrobasilar insufficiency, presents with attacks of vertigo, nystagmus and syncope provoked by lateral head movements. Symptoms arise from dynamic compression of the high cervical vertebral artery when turning toward the contralateral side, frequently at the level of C1-C2.¹ The most common etiologies of the mechanical compression at C1-C2 are fibrous bands, osteophytes and degenerative changes. Other less common causes include occipital bone anomalies, hypertrophy of the atlantooccipital membrane and dystonic paravertebral muscles. In this case report, a 43 year old man with a past medical history of CAD, NSTEMI, HTN and T2DM presented to his otolaryngologist with vertiginous symptoms, left sided tinnitus and nausea provoked by looking to the left.

Methods:

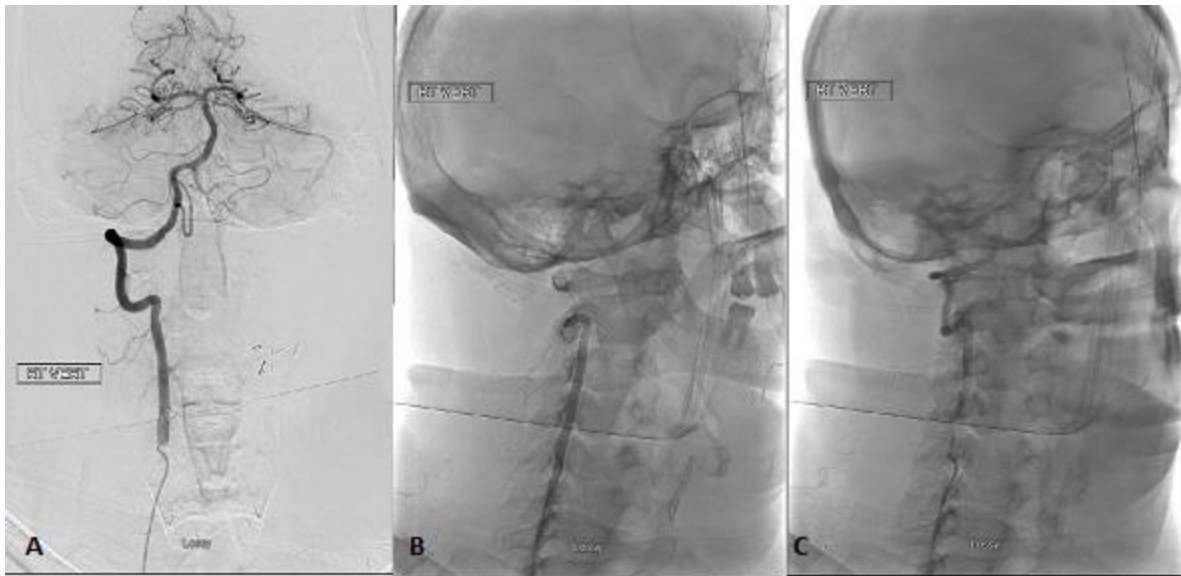
Review of the electronic medical record and imaging revealed a diagnosis of Bow Hunter's Syndrome.

Results:

Audiogram revealed mild to moderate high frequency sensorineural hearing loss slightly worse on the left than the right and initial MRI head without contrast was unrevealing. CT angiogram of the head and neck was obtained with the head turned to the left. In this position, the dominant right vertebral artery did not opacify beyond the mid V2 segment. The diminutive left vertebral artery did not fill beyond the dural penetration. The basilar artery filled retrograde to the mid segment via the Circle of Willis. A CT angiogram from two years prior revealed no filling defects in the carotid or vertebral arteries with neutral head positioning. Dynamic cerebral angiography was next performed which revealed occlusion of the dominant right vertebral artery at the proximal segment of C2 when the head was turned to the left. The patient was immediately symptomatic and had to turn back to the neutral position to avoid vomiting. The left vertebral artery in the neutral position did not fill beyond the V3 segment.

Conclusions:

Bow Hunter's Syndrome is a rare disorder that can be debilitating. Dynamic angiography is the gold standard for diagnosis and allows for the evaluation of anatomy. Management is controversial and many prefer a conservative approach. However, because patients in some series present with ischemic strokes³, patients are often offered definitive treatment. Although endovascular stenting has been reported⁴, the majority of patients are treated by surgery. This patient is scheduled for surgical decompression. Decompression alone is highly effective and affords preservation of normal neck rotation. However, a small subset of patients may require cervical fusion if symptoms persist or postoperative instability develops.⁵



Images from dynamic CT cerebral angiography of the left vertebral artery

A: Head in neutral position. B: Head turned to 80 degree left C: Patient returning head to neutral position due to provoking symptoms.

Keywords: Angiogram, Basilar, Diagnostic Neuroradiology, Vertebral, Angiogram

Financial Disclosures: The authors had no disclosures.

Grant Support: None.

Poster

Mycoplasma Pneumoniae causing Intra-Parenchymal Hemorrhage-an unreported side effect

Nurose Karim, MD¹

¹*University of Texas Southwestern Medical Center, Dallas, Texas, United States of America*

Introduction:

Mycoplasma Pneumoniae (MP) is responsible for upto 40% of community-acquired pneumonia. Central nervous system (CNS) involvement occurs in about 1-10% patients and includes: encephalitis, myelitis, meningitis, Guillain-Barre syndrome, cranial and peripheral neuropathies, striatal and thalamic necrosis among others. Intraparenchymal hemorrhage (IPH) has not been a reported side effect from this organism. We hereby, present the first reported side effect.

Methods:

77 year old female who was recently admitted to the hospital with MP requiring intubation for 3 weeks. On day 9 post extubation, the patient had sudden onset right sided weakness. CT brain showed an acute left basal ganglia (BG) IPH measuring 16.7x 22.7 mm and punctate Right BG bleed. She was not hypertensive at any point throughout her hospital course and her labs including coagulopathy panel, platelet function, Prothrombin Time, International Normalized Ratio were within the normal limits. She had a recent rash in her lower extremities that responded well with steroids. Due to the concerns of vasculitis, she underwent diagnostic cerebral angiography showing diffuse moderate to severe degree intracranial vasculopathic changes concerning inflammatory vasculitis. Pertinent positive labs include: Sedimentation rate 65, C reactive protein 7.3, Von Willebrand Antigen 729, Beta 2 microglobulin 3.0, immunoelectrophoresis showed low IgA and IgM levels with elevated free lambda chain. Other workup including Antineutrophilic cytoplasmic antibodies (MPO, PR3 and ANCA), Anticardiolipin antibody, Myeloperoxidase antibody were negative. Rheumatology and infectious disease were on board. Her hospital course was complicated by generalized seizures requiring Levetiracetam and Lacosamide. Recommendation for brain biopsy for diagnostic purposes were made but unfortunately due to guarded prognosis the family withdrew the care.

Results:

N/A

Conclusions:

MP is a well known pathogen that can cause extra pulmonary manifestations either by local invasion and inflammation, releasing inflammatory cytokines or indirectly via immune-mediated mechanism. It can also cause vascular occlusion causing vasculitis and when it invades cerebral blood vessels, it can cause "mycoplasmal cerebral vasculopathy". Mele et al did a literature review from 1980-2018 and found 28 cases of ischemic stroke associated with recent MP infection (within 4 weeks). Middle cerebral artery was the most common vessel affected. No cases of IPH were found. To our knowledge, this is the first reported side effect of MP. The pathogenesis of it could be direct vascular invasion causing inflammation of the vessel making it fragile and vulnerable to rupture or an immune mediated response.

Keywords: Cerebrovascular Disease, Intracerebral Hemorrhage, Pathophysiology, Cns Vasculitis, Inflammation

Financial Disclosures: The authors had no disclosures.

Grant Support: None.

Poster

Utility of TEE in etiologic classification and management of ischemic stroke

Mark E Heslin, B.S.¹, Evan Caruso, M.D.², Ankit Rana, B.S.¹, Lauren Thau, B.S.¹, Ameena Rana, B.S.¹, Siyuan Yu, B.S.¹, Parth Patel, B.S.¹, James E Siegler, M.D.², Jesse M Thon, M.D.²

¹Cooper Medical School of Rowan University, Camden, New Jersey, United States of America; ²Cooper University Hospital, Camden, New Jersey, United States of America

Introduction:

In approximately 25% of patients with ischemic stroke, the etiology remains cryptogenic¹. The diagnostic evaluation of these patients is a challenge in clinical practice. Transesophageal echocardiogram (TEE) has been shown to have superior diagnostic accuracy in identifying potential cardioembolic sources of ischemic stroke². However, there has been inconsistent data on the management implications of these new cardiac findings. In the present study, we sought to confirm the increased diagnostic yield of TEE in this population, describe relevant echocardiographic findings, and to determine whether TEE was associated with changes in clinical management.

Methods:

Consecutively admitted patients from a single comprehensive stroke center (01/01/2015-09/01/2019) 18-60 years of age with acute stroke due to mechanisms other than large or small vessel disease, or atrial fibrillation, were eligible for inclusion. Cardiac sources of embolism (CSE) and management changes were determined among patients who underwent TEE, after TTE did not identify a CSE, in order to estimate clinical utility of this test.

Results:

Of the 1561 stroke patients admitted during this period, 303 were included (19%); 38% were women, the median age at stroke onset was 53 years (IQR 47-57) and patients were followed for a median of 570 days after stroke (IQR 209-1100). TEE was ordered in 93 patients (31%) and performed in 75 patients (81% of ordered; Table). Any cardiac source of embolism was identified in 23 patients (31% who underwent TEE), the most common of which was patent foramen ovale (n=20). Fourteen patients who underwent TEE underwent a management change (19% of imaged) at a median of 21 days after admission (IQR 5-247).

Conclusions:

In this single-center study of stroke patients with cryptogenic or non-atrial fibrillation sources of cardiac embolism, TEE identified a CSE for one-third of patients and led to significant management changes in 1 of 5 imaged patients. As most CSEs were PFOs, the likelihood of management change is likely an underestimate given the publication of successful PFO closure trials that took place in the middle of this observational period.

Table.

	TEE not ordered (n=210)	TEE ordered, not done (n=18)	TEE done (n=75)	p- value
Age, median (IQR)	54 (48-58)	53 (44-57)	51 (43-56)	0.02
Female sex, no. (%)	75 (36%)	7 (39%)	34 (45%)	0.34
Medical history, no. (%)				
Hypertension	163 (78%)	13 (72%)	50 (67%)	0.17
Diabetes mellitus	90 (43%)	6 (33%)	25 (33%)	0.30
Dyslipidemia	91 (43%)	6 (33%)	34 (45%)	0.68
Heart failure	16 (8%)	1 (6%)	2 (3%)	0.27
Tobacco use	69 (33%)	8 (44%)	26 (35%)	0.60
Prior stroke	61 (29%)	2 (11%)	11 (15%)	0.02
Peripheral artery disease	2 (1%)	0 (0%)	0 (0%)	1.0
Renal insufficiency	19 (9%)	2 (11%)	2 (3%)	0.11
Baseline NIHSS, median (IQR)	4 (2-9)	5 (2-12)	3 (1-6)	0.09
Large vessel occlusion, no. (%)	34 (16%)	2 (11%)	7 (9%)	0.34
Relevant TEE findings, no. (%)				
<i>Any cardiac source of embolism</i>	-	-	23 (31%)	-
PFO	-	-	20 (27%)	-
Atrial septal aneurysm (>10mm excursion)	-	-	4 (5%)	-
PFO + ASA	-	-	4 (5%)	-
Excess atrial motion (5-10mm excursion)	-	-	1 (1%)	-
>4mm aortic arch atheroma	-	-	2 (3%)	-
Valvular lesion	-	-	1 (1%)	-
Fibroelastoma	-	-	1 (1%)	-
Left atrial appendage thrombus	-	-	0 (0%)	-
Left ventricular thrombus	-	-	0 (0%)	-
Management change, no. (%)				
None	-	-	61 (81%)	-
Anticoagulation	-	-	8 (11%)	-

PFO closure	-	-	4 (5%)	-
Dual antiplatelet therapy	-	-	2 (3%)	-

*Note: Approximately half of patients were included in this observational cohort prior to the publication of successful PFO closure trials (2017).

Keywords: Ischemic Stroke

Financial Disclosures: The authors had no disclosures.

Grant Support: None.

Poster

Impact of Systemic inflammatory response syndrome on acute ischemic stroke patients treated with mechanical thrombectomy

Mostafa Jafari, MD¹, Hamidreza Saber, MD², Calros De La Garza, MD¹, Alex Seller, MD¹, Shawn Moore, MD¹, Hayden Hall, MD¹, Aaron Desai, MD¹, Rahul Damani, MD¹

¹Baylor College of Medicine, Houston, Texas, United States of America; ²UCLA, Los Angeles, California, United States of America

Introduction:

Systemic inflammatory response syndrome (SIRS) has been associated with poor outcomes after acute ischemic stroke (AIS). The primary goal of this study was to determine whether SIRS status on admission correlated with outcomes in AIS treated with mechanical thrombectomy (MT).

Methods:

Consecutive patients were retrospectively reviewed for SIRS on admission. SIRS was defined as the presence of ≥ 2 of the following: temperature $< 36^{\circ}\text{C}$ or $> 38^{\circ}\text{C}$, heart rate > 90 , respiratory rate > 20 , and white blood cell count $< 4000/\text{mm}$ or $> 12\,000/\text{mm}$, or $> 10\%$ bands.

Results:

Of 189 patients, 53 (28%) had evidence of SIRS. Patients with SIRS were less likely to be female (n=26, 30.23%; P=0.540) and more likely to be black (n=32, 60.38%; P=0.294). Patients with SIRS had higher rates of death (odds ratio [OR], 5.22; 95% confidence interval [CI], 1.7-15.2; P=0.001), lower rates of favorable functional outcomes at discharge (OR, 0.75; 95% CI, 0.01-0.43; P=0.00) and 3-month follow up (P=0.000) after adjustment for age, sex, baseline NIHSS, recanalization status and prior co-morbidities.

Conclusions:

In our sample population, SIRS was associated with lower rates of short-term favorable functional outcomes and higher rates of mortality in AIS patients treated with MT.

Keywords: Acute Stroke, Endovascular Therapy, Inflammation

Financial Disclosures: The authors had no disclosures.

Grant Support: None.

Poster

Obstructive Sleep Apnea and Thrombolysis Therapy in Acute Ischemic Stroke Patients

Krista M Knisely, Presenter¹, Carolyn B Sanders, author¹, Camron K Edrissi, author¹, Nicolas S Poupore, author¹, Chase A Rathfoot, author¹, Thomas Nathaniel, Principle Investigator¹

¹*University of South Carolina School of Medicine Greenville, Greenville, South Carolina, United States of America*

Introduction:

The eligibility criteria for thrombolytic therapy may differ between acute ischemic stroke (AIS) patients with and without incidence of obstructive sleep apnea (OSA). The aim of this study is to determine what effect OSA has in the exclusion criteria for recombinant tissue plasminogen activator (rtPA) administration in the AIS population with OSA.

Methods:

Retrospective data from a stroke registry were analyzed, and univariate linear regression models were used to determine differences between AIS populations with and without incidence of OSA. Logistic regression models were used to develop odds ratios (OR) for significant clinical risk factors for exclusion from thrombolysis in OSA AIS patients. The validity of the model was tested using a Hosmer-Lemeshow test and the Receiver Operating Curve (ROC) was used to test the sensitivity of our model.

Results:

A total of 170 patients presented with AIS and incidence of OSA; 45 received rtPA while 170 were excluded from rtPA therapy. Adjusted analysis showed that in the AIS population with OSA, receiving rtPA was associated with a history of dyslipidemia (OR = 3.192, 95% C.I. = 1.148 – 8.88, p-value = 0.026), direct admission into a Comprehensive Stroke Center (OR = 3.248, C.I = 1.06 – 9.95, p-value = 0.039), and ambulatory improvement (OR = 3.556. 95% C.I. = 1.428 – 8.86, p-value = 0.006). There were no significant clinical or demographic factors associated with rtPA therapy exclusion in the AIS population with OSA.

Conclusions:

In AIS patients with incidence of OSA, direct admission into a Comprehensive Stroke Center may improve the likelihood of receiving rtPA therapy. Furthermore, treatment with rtPA therapy may lead to improved ambulation within this population.

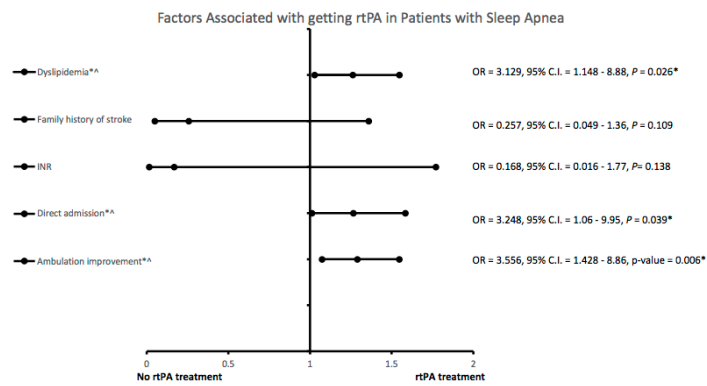


Figure 1: Forest Plot representation of Clinical factors associated with rtPA treatment for ischemic stroke patients with obstructive sleep apnea. Confidence Interval band below 1 denotes factors that are associated without rtPA treatment while Confidence Interval band above 1 denotes factors that are associated with rtPA treatment. Confidence Interval bands that cross 1 cannot be associated with either getting rtPA treatment or not. *Indicates statistical significance ($P < 0.05$) with a 95% confidence interval. **Indicates that data were modified by taking the 5th square root.

Keywords: Acute Ischemic Stroke Intervention, TPA

Financial Disclosures: The authors had no disclosures.

Grant Support: None.

Poster

DECLINE IN MILD STROKE PRESENTATIONS AND INTRAVENOUS THROMBOLYSIS DURING THE COVID-19 PANDEMIC

Santiago Ortega-Gutierrez, MD, MSc¹, Santiago Ortega-Gutierrez, MD, MSc¹, Mudassir Farooqui, MD, MPH¹, Alicia Zha, MD², Alexandra Czap, MD³, Jacob Sebaugh, MD³, Shashvat Desai, MD⁴, Ashutosh Jadhav, MD⁴, Nirav Vora, MD⁵, Vivek Rai, MD⁵, Tudor G Jovin, MD⁶, Jesse M Thon, MD⁶, Mark Heslin, MD⁶, Lauren Thau, BS⁶, Cynthia Zevallos, MD¹, Darko Quispe-orozco, MD¹, Dinesh V Jillela, MD⁷, Fadi Nahab, MD⁷, Mahmoud Mohammaden, MD, MSc⁸, Raul G Nogueira, MD⁷, Diogo C Haussen, MD⁷, Thanh N Nguyen, MD⁹, Jose R Romero, MD⁹, Hugo J Aparicio, MD⁹, Mohamed Osman, MD¹⁰, Israr U Haq, MD¹⁰, David Liebeskind, MD¹¹, Ameer E Hassan, DO¹², Osama Zaidat, MD¹⁰, James E Siegler, MD⁶

¹University of Iowa Hospitals and Clinics, Iowa City, Iowa, United States of America; ²University of Texas Health Science Center, Houston, Texas, United States of America; ³University of Texas health Sciences Center, Houston, Texas, United States of America; ⁴University of Pittsburgh Medical Center, Pittsburgh, Pennsylvania, United States of America; ⁵Ohio Health Neuroscience Center, Columbus, Ohio, United States of America; ⁶Cooper University Hospital, Camden, New Jersey, United States of America; ⁷Emory University School of Medicine, Atlanta, Georgia, United States of America; ⁸Grady Memorial hospital, Atlanta, Georgia, United States of America; ⁹Boston Medical Center, Boston, Massachusetts, United States of America; ¹⁰Mercy Health St. Vincent Hospital, Toledo, Ohio, United States of America; ¹¹University of California Los Angeles, Los Angeles, California, United States of America; ¹²Valley Baptist Medical Center, Harlingen, Texas, United States of America

Introduction:

To evaluate overall ischemic stroke volumes and rates, specific subtypes, and clinical presentation during the COVID-19 pandemic in a multicenter observational study from eight states across US.

Methods:

We compared all ischemic strokes admitted between January 2019 and May 2020, grouped as; March-May 2020 (COVID-19 period) and March-May 2019 (seasonal pre-COVID-19 period). Primary outcome was stroke severity at admission measured by NIHSS stratified as mild (0-7), moderate (8-14), and severe (>14). Secondary outcomes were volume of large vessel occlusions (LVOs), stroke etiology, IV-tPA rates, and discharge disposition.

Results:

Of the 7,969 patients diagnosed with acute ischemic stroke during the study period, 933 (12%) presented in the COVID-19 period while 1319 (17%) presented in the seasonal pre-COVID-19 period. Significant decline was observed in the mean weekly volumes of newly diagnosed ischemic strokes (98 ± 3 vs 50 ± 20 , $p=0.003$), LVOs (16.5 ± 3.8 vs 8.3 ± 5.9 , $p=0.008$), and IV-tPA (10.9 ± 3.4 vs 5.3 ± 2.9 , $p=0.0047$), whereas the mean weekly proportion of LVOs ($18\% \pm 5$ vs $16\% \pm 7$, $p=0.24$) and IV-tPA ($10.4\% \pm 4.5$ vs $9.9\% \pm 2.4$, $p=0.66$) remained the same, when compared to the seasonal pre-COVID-19 period. Additionally, an increased proportion of patients presented with a severe disease (NIHSS>14) during the COVID-19 period (29.7% vs 24.5% , $p<0.025$). The odds of being discharged to home were 26% greater in the COVID-19 period when compared to seasonal pre-COVID-19 period (OR:1.26, 95% CI:1.07-1.49, $p=0.016$).

Conclusions:

During COVID-19 period there was a decrease volume in newly diagnosed ischemic stroke cases and IV-tPA administration. Patients admitted to the hospital had severe neurological clinical presentation and were more likely to discharge home.

Keywords: Stroke, TPA, NIHSS

Financial Disclosures: The authors had no disclosures.

Grant Support: None.

Poster

Cerebrovascular Events, Treatment, and Outcomes in Patients with COVID-19: The SVIN COVID-19 Multinational Registry

James E Siegler, MD¹, Pere Cardona, MD², Juan F Arenillas, MD, PhD³, Blanca Talavera, MD³, Ana N Guillen, MD², Alba Chavarria-Miranda, MD³, Mercedes de Lera, MD³, Priyank Khandelwal, MD⁴, Ivo Bach, MD⁵, Pratit Patel, MD⁴, Amit Singla, MD⁴, Manuel Requena, MD⁶, Marc Ribo, MD⁶, Dinesh V Jillella, MD⁷, Srikant Rangaraju, MD, MSc⁷, Raul Nogueira, MD⁸, Diogo C Hausen, MD⁸, Alejandro R Vazquez, MD⁹, Xabier Urrea, MD, PhD⁹, Ángel Chamorro, MD⁹, Luis S Román, Jesse M Thon, MD¹, Ryna Then, Emma Sanborn, Natalia Pérez de la Ossa, MD, PhD¹⁰, Mònica Millàn, MD, PhD¹⁰, Isaac N Ruiz, Ossama Y Mansour, MD, MSc, PhD¹¹, Mohammed Megahed, Christina Tiu, MD, PhD¹², Elena O Terecoasa, PhD¹², Răzvan A Radu, Thanh N Nguyen, MD¹³, Gioacchino Curiale, MD¹³, Artem Kaliaeov, Alexandra L Czap, MD¹⁴, Jacob Sebaugh, Alicia M Zha, MD¹⁴, David Liebeskind, MD¹⁵, Santiago Ortega-Gutierrez, MD, MSc¹⁶, Mudassir Farooqui, MD, MPH¹⁶, Ameer Hassan, DO¹⁷, Laurie Preston, Mary S Patterson, Saif Bushnaq, Osama Zaidat, MD, MBBs, MSc¹⁸, Tudo G Jovin, MD¹, on behalf of the SVIN COVID-19 Multinational Registry & Task Force

¹Cooper Neurologic Institute, Cooper University Hospital, Camden, New Jersey, United States of America;

²Hospital Universitari Bellvitge, Barcelona, Spain; ³Hospital Clínico Universitario, Valladolid, Spain;

⁴Robert Wood Johnson University Hospital, New Brunswick, New Jersey, United States of America; ⁵New Jersey Medical School, New Brunswick, New Jersey, United States of America; ⁶Vall d'Hebron Research Institute, Barcelona, Spain;

⁷Emory University Hospital, Atlanta, Georgia, United States of America;

⁸Marcus Stroke & Neuroscience Center, Grady Memorial Hospital, Atlanta, Georgia, United States of America;

⁹Hospital Clinic, Barcelona, Spain; ¹⁰Hospital Universitari Germans Trias i Pujol, Barcelona, Spain;

¹¹Alexandria University, Alexandria, Egypt; ¹²University Emergency Hospital Bucharest, Bucharest, Romania; ¹³Boston Medical Center, Boston, Massachusetts, United States of America; ¹⁴University of Texas Health Science Center, Houston, Texas, United States of America;

¹⁵Ronald Reagan University of California at Los Angeles, Los Angeles, California, United States of America; ¹⁶Department of Neurology, University of Iowa Hospitals and Clinics, Iowa City, Iowa, United States of America; ¹⁷University of Texas Rio Grande Valley, Valley Baptist Medical Center, Harlingen, Texas, United States of America;

¹⁸Neuroscience Institute, Bon Secours Mercy Health St. Vincent Hospital, Toledo, Ohio, United States of America

Introduction:

The novel human coronavirus disease 2019 (COVID-19) has been associated with a variety of neurologic complications. The inflammatory state, endothelial dysfunction, prothrombotic state, and disrupted coagulation cascade are implicated in the cerebrovascular events associated with this infection.

Methods:

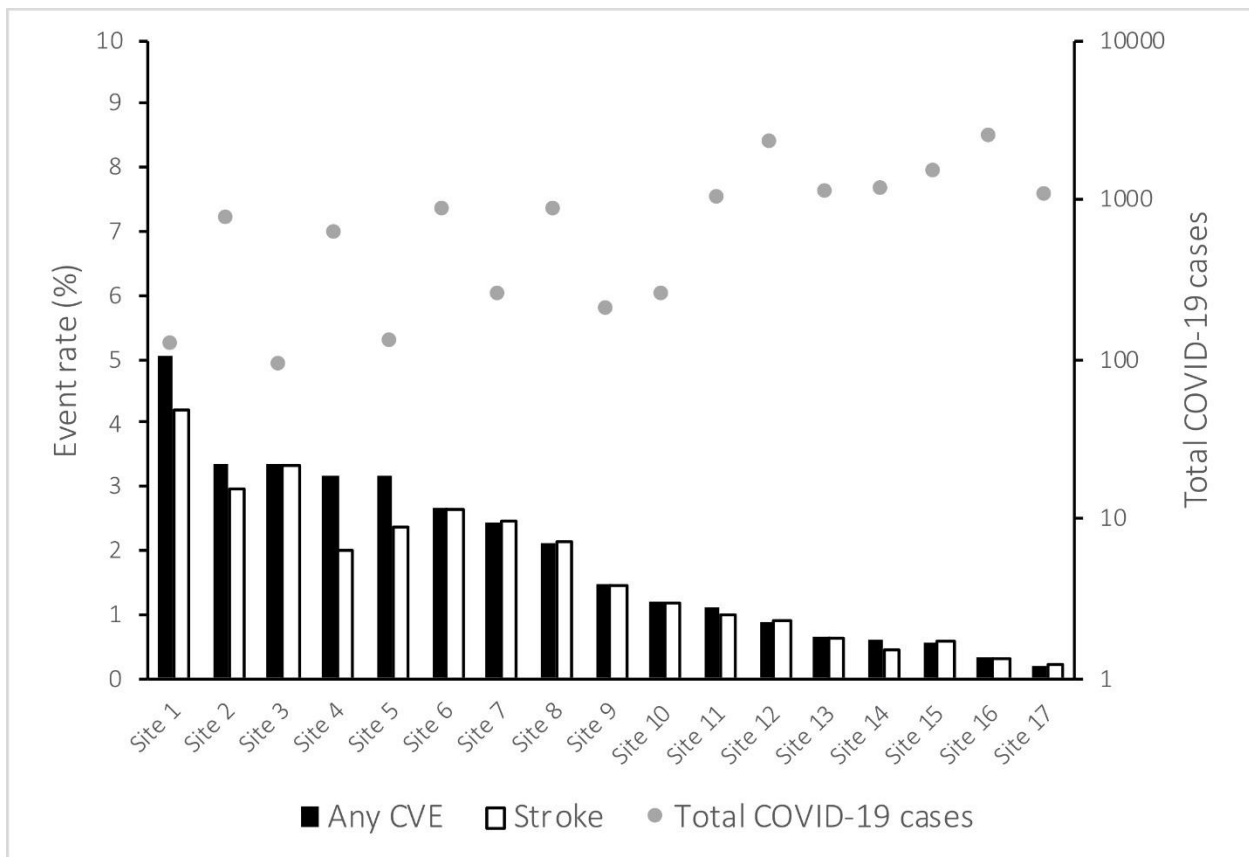
To better understand the global impact of COVID-19 and associated cerebrovascular disease, the SVIN multinational registry was established in order to monitor event rates and outcomes of hospitalized patients diagnosed with COVID-19. Seventeen sites have reported comprehensive data regarding consecutively evaluated COVID-19 patients (March - August 2020) with individual patient-level data regarding associated cerebrovascular events (CVE).

Results:

Of the 14,483 patients with COVID-19, 172 were diagnosed with an acute CVE (1.13% of COVID-19 cohort). Between sites, CVE rates ranged from 0.19 to 5.04%; Figure), with the most common CVE being acute ischemic stroke (n=156, 1.08%). The most common mechanism of stroke was cryptogenic (42.6%), with 80.2% of infarcts being cortical and 49.5% of patients harboring an intracranial occlusion. Half of intracerebral hemorrhages were attributed to coagulopathy (50.0%). More than one-third of patients with acute stroke and COVID-19 died during hospitalization (36.8%), while 58.3% of patients with ICH and COVID-19 died. Thrombectomy in cases of large vessel occlusion was associated with a non-significant decrease in mortality (adjusted OR 0.41, 95%CI 0.09-1.85, p=0.25), while cryptogenic stroke remain strongly predictive of mortality (aOR 8.16, 95%CI 2.33-28.65, p=0.001).

Conclusions:

CVE associated with COVID-19 is an uncommon complication but carries significant morbidity and mortality. The high rate of cryptogenic embolic strokes with a high mortality rate is consistent with smaller cohorts and is suggestive of a novel stroke mechanism. Altogether, these findings should galvanize our efforts to closely monitor for such complications and manage aggressively when a CVE is suspected.



Keywords: Epidemiology, Intracerebral Hemorrhage, Acute Ischemic Stroke Intervention

Financial Disclosures: The authors had no disclosures.

Grant Support: None.

Poster

Missed treatment opportunities and earlier stroke detection among hospitalized patients with acute infarction

Lauren Thau, BS¹, Parth Patel, BS¹, Prasanth Romiyo, BS¹, Mark Heslin, BS¹, Ainsley Smith, RN¹, Austin Chen, BS¹, Dena Little, DO¹, Jesse M Thon, MD¹, James E Siegler, MD¹

¹Cooper University Hospital, Camden, New Jersey, United States of America

Introduction:

In preparation for a quality improvement study, we queried our prospective stroke registry for patients who might benefit from prophylactic monitoring in order to estimate the time advantage to monitoring.

Methods:

A prospective, single center registry of adult patients (9/20/19-6/30/20) was queried for in-hospital acute anterior circulation strokes. Indications for hospitalization as well as delays from last known well (LKW) to symptom recognition, imaging, and treatment were explored.

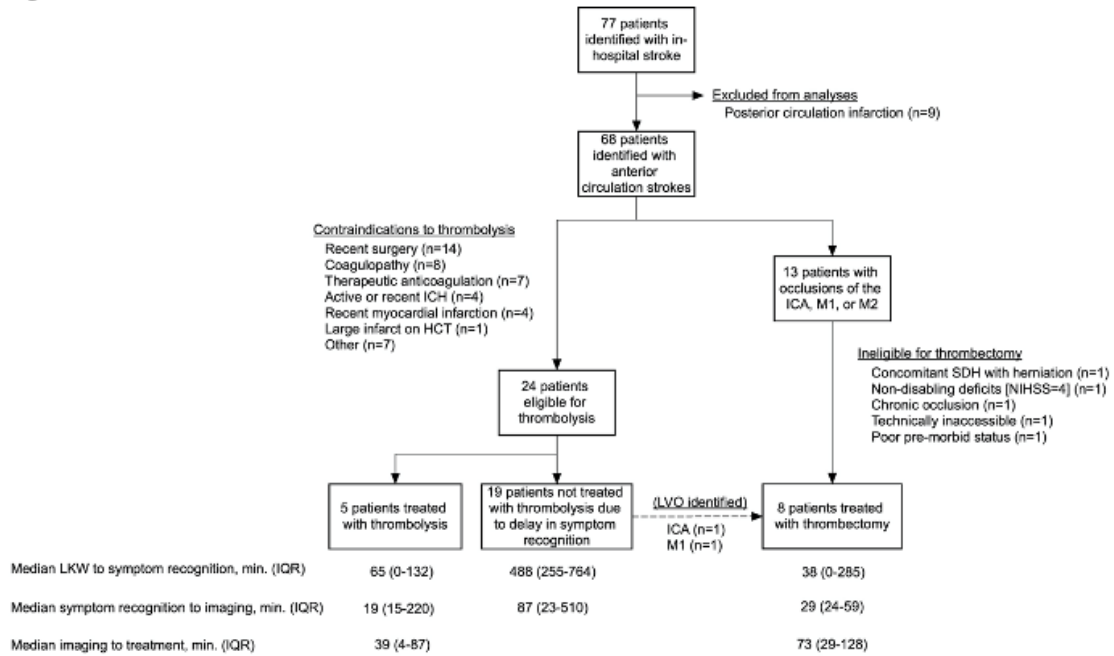
Results:

Of 540 consecutively evaluated adults with acute stroke, 68 (12.6%) developed an anterior circulation infarction while hospitalized, 32 (47.1%) of whom were female with a median age of 66 years (IQR 60-77) and median NIHSS of 14 (IQR 4-22). Four patients (5.9%) received intravenous thrombolysis although another 20 (29.4%) would have been eligible for thrombolysis if not for a delay in symptom recognition. An internal carotid, M1, or M2 occlusion was observed in 13 patients (19.1%), 8 of whom were treated at a median of 198 minutes after LKW (IQR 102-670; Figure). In patients treated endovascularly or with thrombolytics, the delay from LKW to symptom recognition accounted for 55.5% of the delay in care.

Conclusions:

One-third of patients in this single-center cohort would have been eligible for thrombolysis were it not for delays in symptom recognition. The delay to groin puncture exceeded 3 hours for over half of patients with proximal anterior occlusions. Earlier detection using prophylactic monitoring devices has the potential to reduce this major impedance to stroke care and ultimately improve outcomes.

Figure. Patient flowchart.



Keywords: Medical Management, Ischemic Stroke

Financial Disclosures: The authors had no disclosures.

Grant Support: None.

Poster

Composite Neurological Outcomes In Patients With COVID-19 Infection From a Multicenter Health System.

Hashaam Arshad, MD¹, Ain Ejaz, MD¹, Taylor Brinton, MD¹, Ibrahim Alakhras, MD¹, Gregory Howell, MD¹

¹*University of Missouri Kansas City, Kansas City, Missouri, United States of America*

Introduction:

The novel Sars-CoV-2 virus was declared a Pandemic by WHO on March 11, 2020. Majority of the data published at this time brings into light the profound respiratory distress and cardiovascular outcomes however much is left to be discovered as far as neurological outcomes are concerned as suggested by anecdotal evidence and limited data.

Methods:

We conducted a retrospective observational study from January 1, 2020 to April 30, 2020 on data collected from a multicenter health system based in Kansas City Metro area in United States. Composite neurological outcomes from the data included seizures (new onset), delirium (requiring medications), hemorrhagic and ischemic strokes (new onset, diagnosed > 48-72 hours after hospitalization).

Results:

Of the 346 people who tested positive for COVID-19, 89 (25.7%) were admitted to the hospital with 27 (30%) of the admitted patients requiring ICU level of care at some point. Delirium was seen in 19 patients (21%) of the total admitted out of which 14 patients (51%) were in the ICU. We observed a total of 2 cases of stroke, one ischemic and one hemorrhagic (2.2% of admitted patients). Seizures were not observed in this cohort of patients.

Conclusions:

Contrary to anecdotal data, we did not observe significant number of patients experiencing seizures or strokes in this cohort of patients. COVID-19 patients admitted to the hospital were documented to have significant levels of delirium. It is unclear as to why delirium was highly prevalent, could this be due to underlying ARDS or attributable to the critical condition or can it be a primary neurological outcome of COVID-19 is yet to be established. It would however benefit clinicians to closely monitor for worsening mentation or neurologic examination in COVID-19 patients.

Keywords: Ischemic Stroke, Epidemiology

Financial Disclosures: The authors had no disclosures.

Grant Support: None.

Poster

Clot Burden and Collateral score in hyperacute stroke

MOHAMMAD HAMED, MD¹, Mohammad Hamed, MD¹, Elizabeth Peters, BS¹, Yadav Randheer, NP¹, Daniel Boulter, MD¹, Sushil Lakhani, MD¹, Deepak Gulati, MD¹

¹*The Ohio State University Wexner Medical Center, Columbus, United States of America*

Introduction:

With the recent advancement, there are still large number of stroke patients who end up with poor outcome despite getting thrombectomy. Clot extent, location, and collateral integrity are found to be important determinants of outcome in acute stroke. The CBS is a scoring system (0-10) to define the extent of thrombus on CTA. The collateral grading system is scored on a scale of 0-3 on CTA. The purpose of this study is to compare the relationship of clot extent and collaterals with clinical and radiological outcome.

Methods:

One hundred and twenty eight stroke patients with large vessel occlusion who underwent endovascular thrombectomy in our institution were reviewed retrospectively. CBS and CS were calculated on CTA by a neuroradiologist and a vascular neurologist and reached a consensus who were blinded about clinical information. Patients were dichotomized using collateral scores as good (≥ 2) vs bad collaterals (0-1). Univariate and multivariate analysis is performed.

Results:

A total of 128 patients included in the study. Poor collateral is found to be associated with prior history of Afib (47% vs 32%) whereas smoking is found to be associated with good collaterals (38% vs 29%). Low CBS (higher clot burden) is associated more with poor collaterals (70% vs 46%). Poor collateral is associated with higher inhouse mortality (23% vs 9%) and increase number of patients with mRS of 5-6 at 3 months (42% vs 21%). Revascularization rate TICl 2b-3 is not found to be significantly associated with the degree of collaterals (93% with good collaterals whereas 78% in poor collaterals).

Conclusions:

CBS and CS are useful additional markers predicting clinical and radiologic outcomes and could be potentially used clinically as an adjunct to other imaging and clinical features to stratify patient risk better.

	Collateral Score 0-1 (N= 70)	Collateral Score \geq 2 (N=58)	
BASELINE CHARACTERISTICS			
Age (Median) (Range)	72.5	69.5	
Female	38 (54.3%)	31 (53.4%)	
Prior Anticoagulation Use	16 (22.9%)	12 (20.7%)	
Prior ASA use	24 (34.3%)	22 (38%)	
Prior known Afib	33 (47.1%)	19 (32.8%)	p<0.05
DM	17 (24.3%)	15 (25.9%)	
HTN	52 (74.3%)	39 (67.2%)	
Smoking	20 (28.6%)	22 (38%)	p<0.05
BG on admission (Median)	125	125.5	
NIHSS on admission (Median)	18	15	
SBP on admission (Median)	145.5	140.5	
DBP on admission (Median)	78	79	
Onset to Groin (Median) mins	268	441	
CLINICAL AND RADIOLOGICAL OUTCOME			
Ivtpa (n/N)(%)	55 (70%)	38%	
NIHSS at 24 hours (median)	16	12	
NIHSS on discharge (median)	10	8	
mRS 0-1 at 3 months	5 (7%)	9 (16%)	
Mortality (n/N)(%)	16 (22.9%)	5 (9%)	p<0.05
Revascularization TICI - 2b-3	55 (78%)	54 (93%)	
Clot Burden Score (0-6)	49 (70%)	27 (46.5%)	p<0.05
Clot Burden Score (7-10)	21 (30%)	31 (53.5%)	
ASPECT 0-5 (n/N)(%)	9 (13%)	2 (3.5%)	
ASPECT 6-10 (n/N)(%)	61 (87%)	56 (96.5%)	
mRS 5-6 at 3 months	29 (42%)	12 (21%)	p<0.05

Keywords: Acute Stroke, Collateral, Thrombosis, Cerebral Blood Flow, Mechanical Thrombectomy

Financial Disclosures: The authors had no disclosures.

Grant Support: None.

Poster

Outcomes of Large Vessel Occlusion Symptomatic Carotid Webs: A Case Control Study

David Landzberg, MD¹, Raul Nogueira, MD², Sitara Koneru, MD², Alhamza Al-Bayati, MD², Nirav Bhatt, MD², Bernardo Liberato, MD², Michael Frankel, MD², Diogo C Haussen, MD²

¹Emory Neurology, Atlanta, Georgia, United States of America; ²Emory University Hospital / Marcus Stroke and Neuroscience Center, Atlanta, Georgia, United States of America

Introduction:

Carotid webs (CaWs) are focal vessel wall abnormalities found at the posterior aspect of the carotid bulb that arise from atypical fibromuscular dysplasia. While attributing an acute ischemic stroke (AIS) to a CaW remains controversial, CaWs are frequently found in young cryptogenic AIS patients. Little is known about the clinical outcomes in patients with symptomatic CaW and therefore our main goal was to investigate these outcomes through a case control study.

Methods:

We prospectively identified all symptomatic CaW patients with a large vessel occlusion (LVO) between the ages of 18 and 65 at our single comprehensive stroke center from July 2014 to December 2018. Symptomatic CaW was defined as the presence of a posterior linear endoluminal protrusion at the level of the carotid bulb, ipsilateral to the area of acute ischemic infarct with otherwise negative stroke work-up (embolic stroke of undetermined source). Patients with more than one stroke mechanism (including a CaW) were excluded in this group. We used our local institute's GetWithTheGuidelines database to create our control group and identified 25 AIS patients per year between the ages of 18 to 65 from 2014 to 2018 to take into consideration the changing AIS treatment standards over time. A LVO was defined as an internal carotid artery (intracranial segment), middle cerebral artery (M1 or M2) or anterior cerebral artery (A1) occlusion on baseline vessel imaging. Demographic, cerebrovascular risk factors, stroke characteristics and clinical outcomes were then collected and compared between groups.

Results:

Twenty-four symptomatic CaW patients with an LVO were identified and compared to a control group of 125 AIS patients with an LVO. Symptomatic CaW patients were more likely to be female (75% vs. 39%, $p=0.001$) and African American (88% vs. 62%, $p=0.02$), and have lower rates of dyslipidemia (8% vs. 30% $p=0.02$), active tobacco abuse (8% vs. 33% $p=0.01$), and active alcohol or drug abuse (4% vs. 22%, $p=0.04$) compared to the control patients. Symptomatic CaW patients had a similar average age (50.6 ± 9.1 vs. 50.9 ± 10.8 years, $p=0.59$), National Institutes of Health Stroke Scale (NIHSS) (13.5 ± 5.8 vs. 15.2 ± 6.5 , $p=0.19$), size of core infarct through CT perfusion (17.9 ± 21.7 vs. 25.1 ± 36.2 , $p=0.33$) and rates of intravenous thrombolysis (46% vs. 41% $p=0.65$) and thrombectomy (83% vs. 73%, $p=0.28$). Despite these similarities, symptomatic CaW patients were more likely to have good functional outcome (defined by a modified rankin scale of 0 to 2 at discharge - 67% vs. 33% $p=0.002$), more likely to have good functional outcome at 90 days post discharge (83% vs. 47%, $p<0.001$) and lower 90 day mortality rate (0% vs 16%, $p=0.03$).

Conclusions:

Despite having similar age of onset, stroke severity, and treatment rates with intravenous thrombolysis and thrombectomy, symptomatic CaW patients with an LVO had better clinical outcomes compared to the control group of LVO AIS patients. This further supports that symptomatic CaW may represent a distinct subgroup of AIS with a unique stroke mechanism.

Keywords: Acute Stroke, Carotid, Cerebrovascular Disease, Ischemic Stroke, Vascular Imaging

Financial Disclosures: The authors had no disclosures.

Grant Support: None.

Poster

Carotid Web an Increasingly Acknowledged Etiology of Stroke and TIA on Vascular Imaging

Ehizele M Osehobo, MD, MSc¹, Diogo C Haussen, MD¹, Raul G Nogueira, MD¹, Sitara Koneru Achanti, MD¹, Alhamza Al-Bayati, MD¹, Bernardo Liberato, MD¹, Fadi Nahab, MD¹, Michael Frankel, MD¹, Catarina T Festas Camara, MD¹, Charlie C Park, MD MAS¹, Jason W Allen, MD PhD¹

¹Emory University School of Medicine, Atlanta, Georgia, United States of America

Introduction:

Carotid Web (CaW) is an increasingly recognized cause of stroke. However, CaW remains frequently overlooked or misdiagnosed on vascular imaging. We aim to evaluate the rates of misdiagnosis and to evaluate the trends in CaW diagnosis in recent years.

Methods:

Part I-Misdiagnosis: Based on consensus read of Computerized Tomography Angiography(CTA), we identified a cohort of patients treated at a comprehensive stroke center(CSC) from 2014-2020 with symptomatic CaW. We reviewed carotid artery diagnostic official reports from the CSC and any referring hospitals for mention of CaW (or associated terms:“web”,“shelf”,“web-like”).

Part II-Trends in Diagnosis: We performed a retrospective analysis on the CSC electronic medical record database for patients who had CaW (or associated terms) mentioned in their official CTA report from 2011-2020. Adjustments were made based on the yearly volume of 1) stroke/TIA diagnosis and 2) overall CTAs performed.

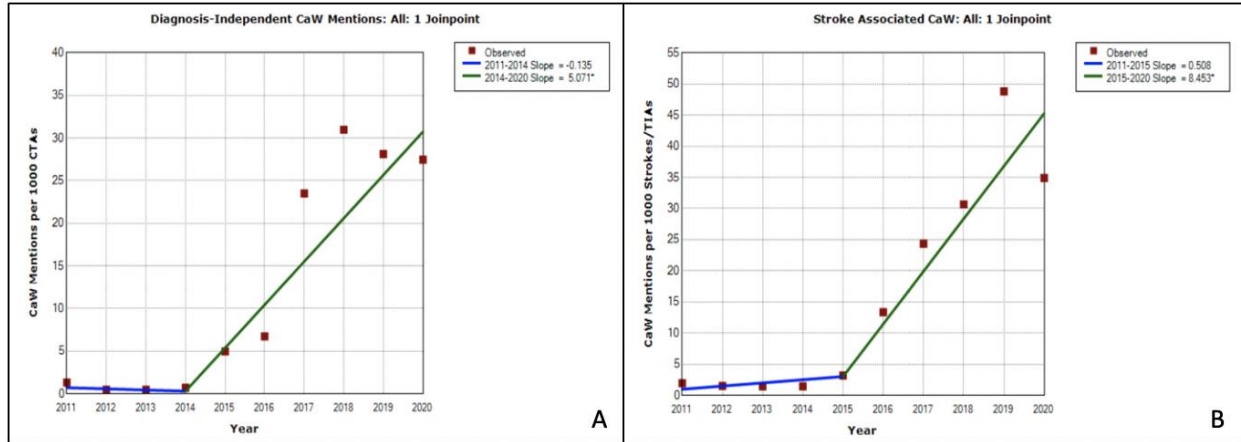
Results:

Part I: Fifty-six patients with symptomatic CaW were identified in the CSC cohort. Sixteen [28%] patients had bilateral CaW, accounting for a total of 72 CaW. Of these, CTA was used for diagnosis in 14 patients/16 CaW at a referring facility, and 35 patients/62 CaW underwent CTA at the CSC. Only 1/16(6%) CaW was accurately reported in the referring facility official CTA report compared to 43(69%; $p<0.01$) at the CSC.

Part II: In the CSC electronic medical record database, 238 patients from 2011-2020 accounted for 269 CTA reports with mention of CaW. The vast majority of these reports ($n=209;77%$), were associated with an ICD-9/ICD-10 diagnosis code correlated to stroke/TIA. As it relates to the annual rate of CaW mentions per 1,000 patients diagnosed with stroke/TIA, the year 2015 was the most significant point of change, named the “joinpoint” (**Figure**). The period of 2015-2020 was found to have a slope coefficient (β) of 8.453, a significant change in trend from the $\beta=0.508$ found in the prior period of 2011-2015 ($p=0.01$). Analysis of all CaW mentions from 2011-2020, irrespective of associated diagnosis but normalized per 1,000 CTAs performed in the CSC, estimated 2014 as the joinpoint (**Figure**). Regression modeling estimated a $\beta=5.071$ from 2014-2020, significantly different from the $\beta= -0.135$ from 2011-2014 ($p<0.02$).

Conclusions:

CaW remains a commonly overlooked diagnosis in facilities with lower levels of cerebrovascular certification. Recognition of carotid web on CTA at the level of a comprehensive stroke center has significantly increased over time, independent of overall patient volume trends.



Legend: Joinpoint regression modeling showed 2014 as the point of change for the annual number of CaW mentions in all patients, independent of diagnosis, normalized per 1000 CTAs performed at the CSC (A), and 2015 as the point of change for the annual number of CaW mentions in patients with a stroke or TIA-associated diagnosis code, normalized per 1000 strokes/TIAs diagnosed at the CSC (B)

Keywords: Angiographic Ct, Vascular Imaging, Carotid, Cerebrovascular Disease, Diagnostic Neuroradiology

Financial Disclosures: The authors had no disclosures.

Grant Support: None.

Poster

Cerebrovascular Disease Represents a Significant Comorbidity in COVID-19 Mortality: A Meta-Analysis

Kevin Clare, B.E.¹, Fawaz Al-Mufti, MD², Tolga Sursal, MD², Rolla Nuoman, MD², Krishna Amuluru, MD², Carrie R Muh, MD², Jared M Pisapia, MD², Edwin Gulko, MD², Philip Overby, MD², Dipak Chandy, MD², Chad Cole, MD², Justin Santarelli, MD², Mill Etienne, MD², Ramandeep Sahni, MD², Steven Marks, MD², Christeena Kurian, MD², Gurmeen Kaur, MD², Katarina Dakay, DO², Simon Hanft, MD², Stephan A Mayer, MD², Chirag Gandhi, MD²

¹New York Medical College, Valhalla, New York, United States of America; ²Westchester Medical Center at New York Medical College, Valhalla, New York, United States of America

Introduction:

SARs-COV-2 (COVID-19) patients display an inflammatory and hypercoagulable response that may predispose them to stroke. However, there remains disagreement in the literature on the association between cerebrovascular disease as a comorbidity in COVID-19 mortality.

Methods:

To address this inconsistency, we conducted a meta-analysis of cerebrovascular disease in COVID-19. A comprehensive systematic literature search of PubMed was performed and in total, we identified eight cohort studies, five case series, and two case reports which met the inclusion criteria.

Results:

In a meta-analysis comparing recovered and deceased patients with severe COVID-19, non-survivors were found to be 12.6 times (n=326, OR 12.65, 95% CI 6.9-23.3, p=0.01) more likely to have a history of cerebrovascular disease. Point estimates of mortality and incidence of acute cerebrovascular disease in COVID-19 patients were obtained through meta-analyses of proportions. Our results estimate a 2.6% (n=576, 95% CI 1.2%-5.4%, p=0.01) incidence of the development of acute cerebrovascular disease among consecutively admitted patients with COVID-19, and a 6.5% (n=217, 95% CI 4.4%-9.6%, p<0.001) incidence of acute cerebrovascular disease among consecutively admitted patients with severe COVID-19 disease. A final cohort meta-analysis estimates 35.5% (n=62, 95% CI 28.4%-43.4%) in-hospital mortality for COVID-19 patients with concomitant acute cerebrovascular disease.

Conclusions:

The outcomes of our investigation confirm that acute or chronic cerebrovascular disease is associated with increased rates of COVID-19 mortality. Moreover, our estimates suggest that patients with chronic cerebrovascular disease hospitalized with severe Covid-19 may have a dramatically increased risk of in-hospital mortality. Future studies should seek to determine efficacious treatment strategies of COVID-19 patients who present with stroke as well as understand the cause of death in this patient population.

No upload

Keywords: Cerebrovascular Disease

Financial Disclosures: The authors had no disclosures.

Grant Support: None.

Poster

Small-vessel vasculopathy harboured within intracranial large-artery atherosclerosis

Thomas W Leung, Dr¹, Cindy Leng, Dr¹, Yannie Soo, Dr¹, Bonaventure Ip, Dr¹, Vincent Mok, Dr¹, Simon Yu, Dr¹

¹*The Prince of Wales Hospital, The Chinese University of Hong Kong, Hong Kong, Hong Kong*

Introduction:

Intracranial atherosclerotic disease (ICAD) is globally a major ischemic stroke subtype. Understanding the stroke mechanism of lacunar syndrome in ICAD and her susceptibility to perforator stroke during stenting may inform treatment strategy.

Methods:

Patients with acute ischemic stroke attributed to high-grade (60-99%) middle cerebral artery (MCA) or basilar artery (BA) stenosis underwent 3-dimensional rotational angiography (3DRA) to delineate the patency of subordinate branches emanating immediately from the stenotic segments. For MCA stenoses, we scrutinized lenticulostriate artery, anterior temporal artery, and occasionally, an early M2 branch from a horizontal M1 segment. For BA lesions, we examined superior cerebellar artery and anterior inferior cerebellar artery. We diagnosed branch atheromatous disease (BAD) if an ostial atheroma occluded >50% the orifice of a subordinate branch/perforator. BAD could be 'adjoining BAD' if the junctional atheroma was contiguous and morphologically inseparable from the parent plaque; or 'isolated BAD' if the orifical atheroma was discrete from the parent plaques. In contrast, we diagnosed intrinsic vasculopathy if the small-vessel steno-occlusion was distinctively distal to a normal orifice.

Results:

Among the 146 patients harbouring MCA (n=132) or BA plaques (n=14), The median luminal stenosis was 75%. 101 patients (69%) had steno-occlusions further in the penetrating arteries/subordinate branches from these stenotic segments. By anatomic location, these small-vessel steno-occlusions (n=107) were primarily orifical (due to adjoining BAD (n=88) or isolated ostial atheroma (n=6)). Distal intrinsic vasculopathy was less common (n=13).

Conclusions:

Concurrent small-vessel vasculopathy was common in ICAD and accounted for frequent manifestations of lacunar syndrome. The predominance of orifical obstructive atheroma underscored the risk of perforator jailing during stenting in this subgroup.

Keywords: Intra Caranial Stenosis

Financial Disclosures: The authors had no disclosures.

Grant Support: General Research Fund, Research Grants Council of Hong Kong (Reference numbers 470411, 14138416, 14106019)

Poster

Improving Identification Of Large Vessel Occlusion Strokes In The Emergency Department Of A Teaching Hospital.

Hashaam Arshad, MD¹, Ellen Troudt, MD¹, William Murphy, MD¹, James Shay, MD¹, Melissa Becker, RN¹, Binod Wagle, MD¹

¹University of Missouri Kansas City, Kansas City, Missouri, United States of America

Introduction:

Identification of Large Vessel Occlusion (LVO) Strokes in the Emergency Department (ED) of Non-primary Stroke Centers is important for triaging patients to Comprehensive Stroke Centers for them to get Tissue plasminogen activator (tPA) and Endovascular Mechanical Thrombectomy which have become standard of care. If LVO is suspected, immediate imaging of the vessels of the head and neck using Computed Tomography Angiogram (CTA) should be done. The aim of our study was to increase the number of CTAs ordered by ED for quicker identification of LVO Strokes leading to transfer to facilities where patients can get appropriate care.

Methods:

The intervention for this study was a didactic session held on 10/24/2019 for ED residents and staff on identification of LVO Strokes, intervention windows for tPA versus Mechanical Thrombectomy, and the role of CTAs. Pre-intervention data from 4/23/2019 till 10/23/2019 and Post-intervention data from 10/25/2019 till 4/25/2020 was collected from chart review of Code Stroke patients. Data included: time when Stroke CT Head and CTA Head and Neck were ordered. If time between orders was greater than 10 minutes, it was presumed that neurology service was consulted, who requested the imaging. The percentage of CTA studies ordered by ED versus Neurology pre- and post-intervention were calculated. Statistical analysis was done with chi-square test.

Results:

In Pre-intervention cohort (n=29): 44.8% (13/29) CTAs were ordered by ED while 55.2% (16/29) were ordered by Neurology. In the Post-intervention cohort (n=22): 77.3% (17/22) CTAs were ordered by ED while 22.7% (5/22) were ordered by Neurology. CTAs ordered by ED were observed to increase from 44.8% to 77.3%, a statistically significant increase, $\chi^2 (1, N=51)=5.44, p= 0.02$.

Conclusions:

Intervention in the form of ED didactic session led to a statistically significant increase in percentage of CTAs ordered by ED. Results highlight the importance of resident educational interventions to improve patient care.

Keywords: Ischemic Stroke, Imaging, Angiographic Ct, Acute Ischemic Stroke Intervention

Financial Disclosures: The authors had no disclosures.

Grant Support: None.

Poster

Early Recanalization Of Large Vessel Occlusions By TPA On The Mobile Stroke Unit

Alexandra L Czap, MD¹, James C Grotta, MD², Mengxi Wang, PhD¹, Stephanie Parker, RN¹, Patti Bratina, RN¹, Kenny Phan, BS¹, Amanda L Jagolino-Cole, MD¹, Sunil A Sheth, MD¹, Suja S Rajan, PhD¹, Jose-Miguel Yamal, PhD¹, Ritvij Bowry, MD¹

¹Univ of Texas Health Science Ctr at Houston, Houston, Texas, United States of America; ²Memorial Hermann Hosp The Medical Ctr, Houston, Texas, United States of America

Introduction:

The benefit of intravenous tissue plasminogen activator (tPA) in acute ischemic stroke patients with large vessel occlusions (LVOs) is limited but time dependent. We evaluated pre-hospital treatment with tPA on the Mobile Stroke Unit (MSU) to explore the recanalization rate in patients with LVOs and its effect on clinical improvement upon Emergency Department (ED) arrival.

Methods:

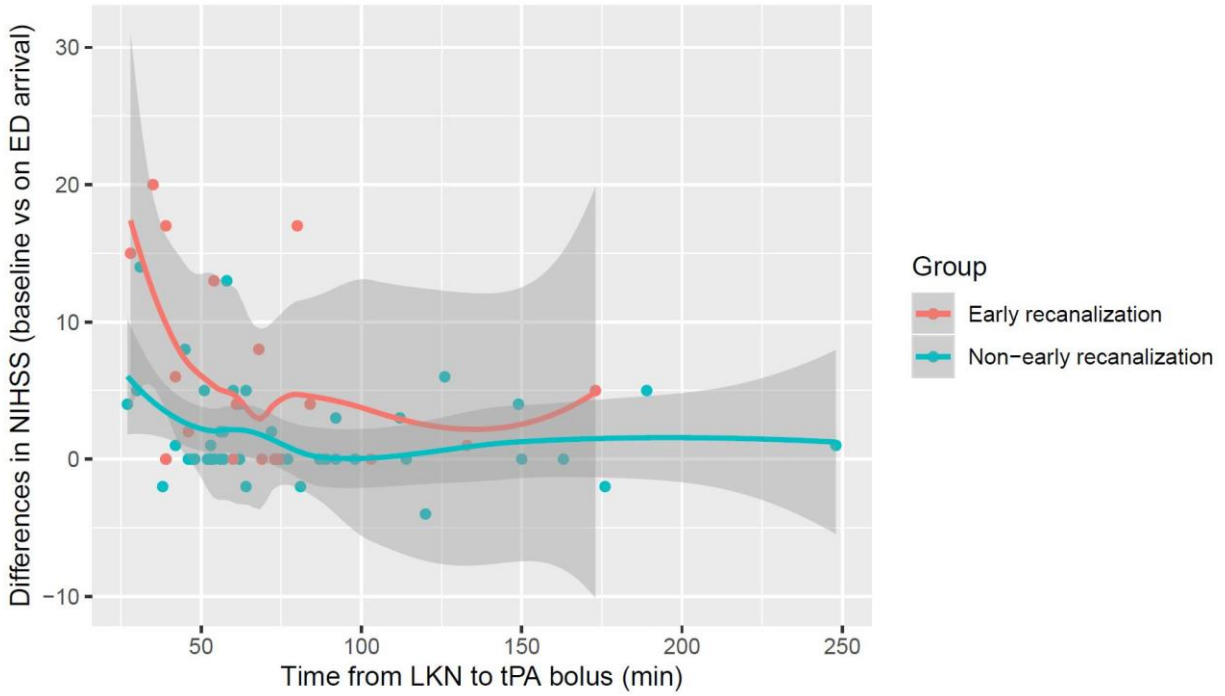
Prospectively derived data were analyzed from patients on the MSU who were treated with tPA and had LVOs identified by hyperdense artery on MSU computed tomography (CT) or arterial occlusion on MSU CT angiography (CTA). The primary outcome was early recanalization, categorized as resolution of LVO on repeat vascular imaging in the ED or on emergent angiography versus no recanalization. Secondary outcome was change in baseline National Institutes of Health Stroke Scale (NIHSS) at 24 hours. Differences in NIHSS were evaluated using Wilcoxon rank sum test with continuity correction.

Results:

Seventy-one patients received tPA and had proximal LVOs both in the anterior and posterior circulation. Eleven had recanalization on CTA upon ED arrival (15.5%), while 7 had recanalization on emergent angiography (9.9%). The total early recanalization rate with tPA was 25.4%. Forty-seven patients with persistent LVOs on ED arrival (66.2%) underwent endovascular thrombectomy (EVT). Time from symptom onset (last known normal) to tPA bolus did not differ significantly between the early recanalization versus non-early recanalization groups (64.5 minutes [IQR 43.0-78.5] versus 64.0 minutes [52.5-92.0]; $p = 0.41$). Early recanalization resulted in greater improvement in baseline to ED arrival NIHSS (median NIHSS change 4.0 [0-11.8] versus 0 [0-3.5]; $p = 0.01$). There were no differences in ED arrival to 24 hour NIHSS between the early recanalization versus non-early recanalization groups irrespective of EVT.

Conclusions:

Recanalization by ED arrival occurs in 25% of LVO patients with tPA treatment on a MSU and was associated with early clinical improvement. Subsequent EVT did not “make up” for the clinical benefit of early recanalization.



Keywords: TPA, Ischemic Stroke, Revascularization

Financial Disclosures: The authors had no disclosures.

Grant Support: Patient Centered Outcomes Research Institute (PCORI R-1511-33024)

Poster

Modifiable Stroke Risk Factors as Prognostic Tools for Patient Outcome

Adnan Mujanovic, /¹, Merjem Begic, /²,

¹Medical faculty, University of Tuzla, Tuzla, Bosnia and Herzegovina; ²Medical University of Vienna, Vienna, Austria

Introduction:

Ischemic stroke is a major cause of morbidity and mortality worldwide. As the number of people with hypertension, diabetes mellitus and dyslipidemia increase, it is highly likely that this problem worsens. This paper represents latest data on stroke in Tuzla Canton, Bosnia and Herzegovina. Certain modifiable stroke risk factors have been analyzed in this study, with the aim of their further use as prognostic tools for patient's clinical outcome.

Methods:

Data was collected through a retrospective hospital-based study at the Stroke Unit of the Neurology Department. All patients which were admitted between January 1st and December 31st 2018 with first-ever ischemic stroke (FEIS) were included in the study. Recurrent ischemic strokes and other stroke types were excluded. All data were extracted from the hospital patient's records. The severity of the neurological deficit on admission and discharge was assessed using the NIHSS. Outcome at one month after stroke onset included information on vital status and handicap using the mRS. SPSS software for Windows (version 20, SPSS Inc., Chicago, IL, USA) was used for the statistical analysis of the data. $p < 0.050$ was considered statistically significant.

Results:

FEIS was diagnosed in 749 patients (mean age $72,33 \pm 10,779$) out of which the 48,4% ($n=358$) were men and 51,6% ($n=381$) women (mean age $71,00 \pm 11,01$ & $73,59 \pm 10,41$ respectively). Leading modifiable risk factors were hypertension (94,0%; $n=695$), diabetes mellitus (40,72%; $n=301$), dyslipidemia (38,82%; $n=287$), smoking (25,62%; $n=189$) and alcohol (10,71%; $n=79$) overuse. Diabetes ($p < 0.004$) was mostly registered with female patients, while alcohol ($p < 0.0001$) and cigarette ($p < 0.0001$) abuse were statistically more present in male patients. There was no significant difference in the presence of other modifiable stroke risk factors between the genders. High mortality rate was observed in individuals who had diabetes ($\chi^2=3,852$; $p=0.05$) or dyslipidemia ($\chi^2=45,879$; $p < 0.001$). In the surviving patient group, most notable factors deciding negative patient outcome (mRS > 2) were dyslipidemia ($\chi^2 = 25,191$; $p < 0.0001$) which had a strong effect, and atrial fibrillation ($\chi^2=9,326$; $p < 0.002$) having a moderate effect.

Conclusions:

The need to intensify prevention and intervention programs for managing modifiable stroke risk factors should be prioritized. Improving stroke outcomes in individuals with modifiable risk factors requires prompt and persistent implementation of evidence-based medical protocols as well as the adoption of beneficial lifestyle practices. Despite the single hospital-based analysis, this study provides the latest data on stroke incidence and its epidemiological features in Bosnia and Herzegovina. With the multitude of these studies, we will be able to form a standardized national registry, which will further facilitate better health-care planning, prevention, and stroke management.

Keywords: Epidemiology, Acute Stroke, Ischemic Stroke, MRS, Clinical Investigations

Financial Disclosures: The authors had no disclosures.

Grant Support: None.

Poster

Utility of Routine Transfer for Patients Administered Intravenous Alteplase for Ischemic Stroke

Emmanuel Okematti, Student¹, Hope Ukatu, MD², Zahrah Shakur, Student¹, Mary Okematti, Student³, Christopher Streib, MD²

¹*University of Minnesota Twin Cities Medical School, Minneapolis, Minnesota, United States of America;*

²*University of Minnesota Department of Neurology, Minneapolis, Minnesota, United States of America;*

³*Northwestern University, Evanston, Illinois, United States of America*

Introduction:

Intravenous Alteplase is currently the only approved medical therapy for treatment of acute ischemic stroke (AIS). Although complications are uncommon, AIS patients receiving IV Alteplase are routinely transferred to higher level stroke centers for monitoring. This resource intensive treatment paradigm is of unclear medical benefit.

Methods:

We reviewed the stroke thrombolysis database of a single comprehensive stroke center. All presumed AIS patients who received IV Alteplase without thrombectomy from 01/01/2015 to 12/31/2019 were included. Baseline demographics including age, sex, race, ethnicity, comorbidities and NIHSS were abstracted. Complication rates including angioedema, intracranial and extracranial hemorrhage were recorded. To determine the utility of routine transfer, medical and surgical/neurosurgical interventions to treat complications of Alteplase administration were studied. Complication rates in the transfer and non-transfer cohorts were compared via Fischer's exact test.

Results:

Three hundred eighteen patients were reviewed and 222 consecutive AIS patients (median age 67 [IQR 55.5-77], female 48.6%, median NIHSS 5 [IQR 2-10], transfers 54.5%) were eligible for our analysis. Complication rates were not statistically different between transfer and non-transfer patients. Four (1.8%) patients suffered symptomatic intracranial hemorrhage (sICH). All sICH patients received cryoprecipitate and aggressive blood pressure management; none underwent emergent neurosurgical intervention.

Conclusions:

The overall rate of complications post-Alteplase administration for AIS patients was similarly low between transfer and non-transfer patients. These findings call into question the utility of routine transfer of AIS patients treated with Alteplase. Further study of alternative post-Alteplase monitoring strategies, including remote specialist management via telemedicine, should be considered.

Table 1. Demographic Characteristics, Complications, and Interventions for AIS Patients Treated with Intravenous Alteplase

Measure	Non-transfer N=101	Transfer N=121	Total N=222
Age, years (median [IQR])	67 (57-79)	68 (55-76)	67 (55.5-77)
Sex, female, n (%)	50 (50.5)	57 (47.1)	107 (48.6)
Race, n (%)			
White/Caucasian	75 (74.3)	108 (89.3)	183 (82.4)
Black/African American	8 (7.9)	2 (1.7)	10 (4.5)
Asian/Pacific Islander	4 (4.0)	3 (2.5)	7 (3.2)
Hispanic/Latino	3 (3.0)	3 (2.5)	6 (2.7)
Other	11 (10.9)	5 (4.1)	16 (7.2)
Past Medical History, n (%)			
Hypertension	74 (73.3)	78 (64.5)	152 (68.5)
Hyperlipidemia	57 (56.4)	50 (41.3)	107 (48.2)
Diabetes mellitus	37 (36.6)	32 (26.4)	69 (31.1)
Tobacco use	18 (17.8)	28 (23.1)	46 (20.7)
Atrial fibrillation	18 (17.8)	22 (18.2)	40 (18.0)
Obstructive sleep apnea	13 (12.8)	15 (12.4)	28 (12.6)
Medications, n (%)			
Antiplatelet	64 (63.4)	61 (50.4)	125 (56.3)
Anticoagulant	8 (7.9)	8 (6.6)	16 (7.2)
Stroke Treatment Data			
NIHSS (median [IQR])	5 (3-10)	5 (2-9)	5 (2-10)
Time to Alteplase administration, minutes (median [IQR])	115 (89-168)	129 (96-180)	123 (93-176)
Hemorrhagic transformation, n (%)			
PH1	3 (3.0)	1 (0.8)	4 (1.8)
PH2	2 (2.0)	3 (2.5)	5 (2.3)
sICH	2 (2.0)	2 (1.7)	4 (1.8)
Medical Intervention, n (%)			
Blood Pressure intervention	2 (2.0)	2 (1.7)	4 (1.8)
Cryoprecipitate	2 (2.0)	2 (1.7)	4 (1.8)
Intubation	1 (1.0)	2 (1.7)	3 (1.4)
Neurosurgical intervention	0 (0.0)	0 (0.0)	0 (0.0)

AIS = Acute Ischemic Stroke; NIHSS = National Institutes of Health Stroke Scale; IQR = interquartile range
 PH1 and PH2 = parenchymal hemorrhage types 1 and 2, respectively, as defined by the Heidelberg
 Bleeding Classification; sICH = symptomatic intracerebral hemorrhage defined by presence of parenchymal
 hematoma and NIHSS increase of >4

Keywords: Acute Ischemic Stroke Intervention, TPA, Intracerebral Hemorrhage, Hemorrhagic Transformation, Neuromonitoring

Financial Disclosures: The authors had no disclosures.

Grant Support: None.

Poster

Carotid Web in Patients Treated for Patent Foramen Ovale

Sitara Koneru, MD¹, Raul G Nogueira, MD¹, Fadi Nahab, MD¹, Alhamza Al-Bayati, MD¹, Michael Frankel, MD¹, Michael C McDaniel, MD¹, Diogo C Haussen, MD¹

¹Emory University, Atlanta, Georgia, United States of America

Introduction:

Patent foramen ovale (PFO) can lead to paradoxical embolism and subsequent ischemic stroke. The prevalence of PFO is higher in patients with cryptogenic stroke. Multiple randomized controlled trials have looked at PFO closure to prevent recurrent stroke and there may be a reduced risk of recurrent stroke with closure when compared to medical therapy. Carotid webs (CaW), a ridge-like filling defect in the carotid bulb that serves as a nidus for cerebral thromboembolism, have more recently become recognized as a potential etiology of stroke especially in young patients. These malformations are frequently missed on vascular imaging, and therefore we aim to investigate the presence of CaW in patients with stroke or transient ischemic attack (TIA) who underwent PFO closure.

Methods:

A retrospective review was performed of all patients who had a diagnosis of cryptogenic stroke/TIA and had a PFO found on cardiac work-up with transthoracic echocardiogram (TTE) and transesophageal echocardiogram (TEE), which was subsequently closed at our center between January 2015 and May 2020. High risk PFO was defined as PFO that was either described as large in size or had an atrial septal aneurysm present. All patients with neck vessel imaging at our center, either digital subtraction angiogram (DSA), computed tomography angiography (CTA) with contrast, magnetic resonance angiography (MRA) with contrast or carotid ultrasound (CaUS), were included in the study cohort. These images were reviewed blindly by 2 neurointerventionalists for the presence of CaW.

Results:

A total of 72 patients were identified, of which 41 (57%) were male. Age of patients ranged from 19 to 85 years-old with a median age of 52.5 years-old (45% were > 55 years-old). 34 out of 72 patients (47.2%) had hypertension, 25 (34.7%) had hyperlipidemia, 12 (16.7%) had diabetes mellitus, 18 (25%) reported tobacco use, and 6 (8.3%) had a history of coronary artery disease. Of these 72 patients, 44 (62.5%) had high risk PFOs identified on TTE and TEE. There was a total of 5 DSA, 37 CTA with contrast, 5 CaUS, and 43 MRA with contrast that were reviewed. Out of these 72 patients, 2 (2.8%) were found to have carotid web on vessel imaging.

Conclusions:

The frequency of CaW in this PFO cohort was very low. The relative advanced age of the treated patients may in part explain these findings. It is reasonable, therefore, to consider careful evaluation of neck vessel imaging for CaW prior to PFO closure.

Keywords: Carotid, Stroke, Vascular Imaging, Decision Analysis

Financial Disclosures: The authors had no disclosures.

Grant Support: None.

Poster

Infective Endocarditis Associated With Subarachnoid Hemorrhage Portend High Morbidity and Mortality: A Population Study

Zafar Karimov, BS¹, Linda Ye, BS¹, Andrew Nazarenko, MS¹, Tolga Sursal, MD¹, Fawaz Al-Mufti, MD¹

¹Westchester Medical Center, Valhalla, New York, United States of America

Introduction:

Infective endocarditis (IE) patients with subsequent subarachnoid hemorrhage (SAH) may result in poorer prognosis compared to infective endocarditis-positive patients without SAH. However, this has never been demonstrated on a sufficient scale with a large patient population.

Methods:

Using the National Inpatient Sample (NIS) database, we identified patients with IE and SAH based on appropriate ICD 9 and 10 codes. Annual NIS data files from 2010 to 2016 were obtained from the HCUP Central Distributor. Using this database, we conducted a retrospective cohort study on data extracted from the NIS to compare different groups of patients with IE and SAH.

Results:

Based on our inclusion/exclusion criteria, we were able to identify 82,844 IE-positive patients. Of this group, 641 patients experienced IE and subsequent SAH. Our results demonstrate that IE patients who underwent SAH had a more complicated course and need for further intervention. Overall, compared to IE only patients, the IE+SAH group had higher risk of ventriculitis, ischemic and hemorrhagic stroke, need for temporary as well as permanent CSF diversion, and craniotomies. Moreover, our results also revealed that patients in the SAH cohort showed significantly higher mortality risk compared to the patients without SAH, with 89.1% of patients with IE and SAH placed in the "Extreme Risk" category (versus the 35.5% of IE patients without SAH). The odds ratio for mortality was found to be 4.65 (CI95% 3.9-5.5, $p < 0.001$). These results are consistent with previous literature and further provide evidence for poor outcomes tied to SAH in IE patients.

Conclusions:

Our analysis indicates that, on a large scale, there are demonstrable differences in co-morbidities in IE patients with SAH compared to IE patients without SAH. Patients with IE that experience subsequent SAH are at increased risk for numerous complications and higher incidence of co-morbidities and mortality. Proper treatment and careful monitoring of mycotic aneurysms should be done in order to minimize the risk of subarachnoid hemorrhage occurring as a sequela to infective endocarditis.

Keywords: Subarachnoid Hemorrhage, Epidemiology, SAH

Financial Disclosures: The authors had no disclosures.

Grant Support: None.

Poster

Telestroke Consultation in The Emergency Medical Services Unit-A Novel Approach For Acute Stroke Prehospital Triage

Eyad Almallouhi, MD¹, Sami Al Kasab, MD¹, Cheryl Grant, BS¹, Morgan Baki, DO¹, Perette Sabatino, RN¹, David Jones, RN¹, Christine A Holmstedt, DO¹

¹Medical University of South Carolina, Charleston, United States of America

Introduction:

Faster treatment times are associated with improved outcomes in patients with acute ischemic stroke. In this prospective pilot study, we assess the feasibility of initiating telestroke consultation in emergency medical services unit (TEMS).

Methods:

Patients with stroke symptoms were evaluated via TEMS using a video-call with a stroke provider. After TEMS evaluation, patients were transferred to the nearest stroke center (NSC) or thrombectomy capable center (TCS) depending on stroke severity and symptom onset time. We compared time metrics between patients evaluated via TEMS to those via standard telestroke (STS) consultation.

Results:

49 patients were evaluated via TEMS between May 2017 and March 2020. Median age was 66, 24 (49%) were females, 15 (30.6%) received intravenous alteplase (tPA) after arrival to a local hospital, and 3 (6.1%) underwent mechanical thrombectomy (MT) after bypassing the NSC. Compared to 52 tPA patients treated through STS consultation, TEMS patients had shorter door to needle (DTN) time (21 vs. 38 minutes, $p < 0.001$). In addition, patients who received MT after bypassing the NSC had shorter onset to groin time compared to those transferred from NSC (216 vs. 293 minutes, $P = 0.04$).

Conclusions:

Prehospital stroke triaging using TEMS is feasible, and could result in shorter DTN and onset to groin times.

Tables:

Table 1: Comparison between TEMS tPA and STS tPA groups

	TEMS tPA (n=15)	STS tPA (n=52)	P-value†
Age, median(IQR)	66(65-80)	69(53-82)	0.781
Female sex, n(%)	4(26.7%)	25(48.1%)	0.236
White, n(%)	11(73.3%)	35(67.3%)	0.76
NIHSS, median(IQR)	5(4-12)	7(4-12)	0.898
Onset-to-Door, median(IQR)	98(80-108)	60(43-135)	0.122

Door to tPA decision, median(IQR)	13(8-21)	29(23-40)	<0.001
Door to needle, median(IQR)	21(13-31)	38(29-44)	<0.001
Discharge outcome, n(%)*			0.671
Home/Rehab	13(92.9%)	38(82.6%)	
Nursing home/Hospice/dead	1(7.1%)	8(17.4%)	
Discharge mRS 0-2, n(%)**	8(57.1%)	34(69.4%)	0.522
Symptomatic intracerebral hematoma, n(%)	0	1(1.9%)	1

*missing 7

**missing 4

Keywords: Door To Needle, Door To Groin Puncture

Financial Disclosures: The authors had no disclosures.

Grant Support: None.

Poster

Bilateral Carotid Dissection Due To Eagle Syndrome: Case Report And Systemic Review Of Case Reports

Walter Duarte-Celada, MD¹, Dongkwan Jin, MD¹, Thomas Windisch, MD²

¹*Texas Tech University Health Sciences Center - Neurology Department, Lubbock, Texas, United States of America*; ² *Covenant Medical Center, Department of Interventional Radiology, Lubbock, Texas, United States of America*

Introduction:

Eagle syndrome is a rare condition characterized for the elongation of the styloid process or calcification of stylohyoid ligament causing compression of local structures in the neck. It is an uncommon cause of bilateral internal carotid artery (ICA) dissection. Limited information is available about the acute and long-term management of this complication. Antithrombotics, observation, neck immobilization, angioplasty, stenting, and styloidectomy have been described.

Methods:

Case report and systematic review of previous published case reports, in the English literature, of patients with bilateral carotid dissection in the setting of Eagle Syndrome.

Results:

We present a case of a 43-year-old woman who presented with intractable headache, neck pain and left Horner syndrome. Patient was diagnosed with bilateral ICA dissection and bilateral elongated styloid processes abutting the arteries. She underwent angioplasty with covered stents on bilateral carotid arteries. Subsequently, she received right and left styloidectomy 5 and 8 months after the discharge respectively. Styloidectomy led to dramatic improvement in neck pain and odynophagia, but effect on headache was minimal. One year follow-up MRI showed a small T2 hyper-intensity in left centrum semiovale which corresponded possibly to a silent new stroke. After two years of her diagnosis, patient remains with no neurological deficits. Stents are patent, and the genetic screening for soft tissue disease was negative.

In the medical literature, we found 12 cases of patients with bilateral internal carotid dissection due to Eagle syndrome, including our case (Table 1). Seven cases documented an acute ischemic event on presentation. Nine cases were treated medically or with thrombectomy on admission (but no stents), and 5 of them ended up having new cerebrovascular accidents. Including our current case, there were only 2 cases treated with stenting on initial presentation. One case that had left ICA stenting, but complicated by worsening of right ICA dissection. To our best knowledge, this is the first reported case where bilateral angioplasty with covered stent placements was conducted as initial management, and the patient only had a potential asymptomatic small stroke found in a following MRI after 1 year.

Conclusions:

Eagle syndrome is a rare cause of bilateral ICA dissection. Limited information is available about its management. Treating with endovascular procedures in the acute phase may be beneficial to reduce the

chance of recurrent vascular complications. Referring the patient for possible styloidectomy is also recommended in an attempt to remove primary causative lesion as well as to treat symptoms.

Table 1. Summary of previously reported cases of Eagle Syndrome with bilateral carotid artery dissection.

Author, year	Age, sex	Precipitating factor	Symptoms	Initial brain MRI	Vascular studies	Initial treatment	Additional tx	Follow-up
Faivre et al, 2009.	60, male	Shaking dance	Headache, L sided hemiplegia hemianopia. R Horner	R MCA acute infarct	b/l ICAD, R petrous carotid stenosis	tPA. Followed by anti-thrombotics, neck brace.	Possible styloidectomy, no description	ND
Todo et al, 2012	57, male	Cervical massage	Transient aphasia, neck pain, unsteadiness	L fronto-parietal acute infarct	b/l ICAD	IV heparin	Complicated: L ICA occlusion. Had L ICA thrombectomy, angioplasty, stent.	1 year – No events. No surgery planned
Vodopivec et al. 2013	52, male	Hyper-extension	Headache, diplopia	No acute infarct	b/l ICAD	Not described	Not described	Not described
Naito et al, 2014	55, male	Head position	Dizziness, L amaurosis fugax.	L cerebral hemisphere acute infarct	b/l ICAD, with L side occlusion	Heparin and warfarin	Complicated by aphasia and R sided hemiparesis. b/l styloidecto, followed by R stenting	1 month – No events.
Ogura et al, 2014	55, male	None	L amaurosis fugax	L cerebral hemisphere acute infarct	b/l ICAD. Thrombus in the L pseudo lumen	IV heparin, neck brace.	Complicated with complete L ICA occlusion 4 days later. 2 days later R styloidectomy, followed by R ICA stent (PRECISE).	3 months – no events
Zammit et al, 2018	45, male	Not recently. Car accident many years before.	Headache, R facial sensory symptoms, R Horner	Old L frontal infarct	b/l ICAD	ASA and Clopidogrel	Complicated by R ICA occlusion. 3 days later: another infarct in the R MCA territory	Weeks – No events
Torikoshi et al, 2019	46, male	Unclear, patient with alcohol intoxication	L hemiplegia	R fronto-parietal acute infarct	b/l ICAD, L side nearly occluded	tPA, Stenting of L ICA, followed by ASA and clopidogrel , collar	Complicated with R ICA deterioration. Had R stent. b/l styloidectomy 8 months later.	3 years – no events
Galletta et al, 2019	53, male	ND	L hemiparesis, facial droop, dysarthria	R MCA infarct	R ICA thrombus, dissection and occlusion	R ICA thrombectomy.	3 days later complicated by b/l ICAD, Removal of L C1 transverse process	Paresis of L lower lip for 3 months. No further events
Baldino et al, 2020	45, male	ND	Headache, L amaurosis fugax,	ND	b/l ICAD, L false lumen thrombosis	Anti-coagulation	L styloidectomy	5 year – no events.
Baldino et al, 2020	49, male	ND	Transient aphasia	ND	b/l ICAD	Anti-coagulation	b/l staged styloidectomy 2 and 4 weeks later	1 year – no events
Ikenouchi et al, 2020	30, male	Ehlers-Danlos syndrome.	L Sensory disturbances	R MCA acute infarct	Old L ICAD. New R ICAD	ASA,	Close observation	4 months – no events
Present case	43, female	None	Headache, neck pain, ear pain, left Horner	No acute infarct	b/l ICAD, R side pseudo aneurysm, L side occluded.	Enoxaparin, R stenting, and L stenting (Fluency covered stents)	b/l styloidecotmy 5 and 8 months post admission. Retrospectively: small L centrum semiovale infarct post L stent.	1 year – intermittent occipital pain

L: left; R: right; b/l: bilateral; ICAD: internal carotid artery dissection; ND: no data

Keywords: Acute Ischemic Stroke Intervention, Carotid Stenting And Angioplasty, Endovascular Therapy, Interventional Neuroradiology, Stenting

Financial Disclosures: The authors had no disclosures.

Grant Support: None.

Poster

Complication Rates Following Cerebral And Coronary Angiography Using The NIS Database (2008-2014)

Fawaz Al-Mufti, Assistant Professor¹, Smit Patel, Neurology Resident², Rajkumar S Pammal, M.D. Candidate³, Justin M Lapow, M.D. Candidate³, Martina Brozynski, M.D. Candidate³, Samantha Sudol, M.D. Candidate³

¹Westchester Medical Center, Valhalla, New York, United States of America; ²University of Connecticut, Farmington, Connecticut, United States of America; ³New York Medical College, Valhalla, New York, United States of America

Introduction:

Catheter-based angiography is an invaluable method used for the diagnosis and treatment of vascular complications in patients. Since cerebral and coronary angiography are similar techniques that utilize the same access sites and general principles, the associated risks overlap and should be identified in order to help direct patient care. Previous nationwide-cohort studies have examined cerebral and coronary angiography separately with relation to a presenting condition of interest, rather than the specific complications of catheter-based intervention. The purpose of this study was to determine complication rates of these catheter-based procedures in a combined cohort using an administrative database.

Methods:

We utilized the National Inpatient Sample (NIS), the largest all-payer inpatient database in the United States, from 2008-2014. Patients >18 years of age undergoing cerebral or coronary angiography were identified using ICD-9 codes 88.41 and 37.21, 37.22, 37.23, 88.52, 88.53, 88.54, 88.55, 88.56, and 88.57 respectively. Descriptive analysis was performed using SAS 9.4 software.

Results:

A total of 3,763,651 hospitalizations were included in our study cohort (3,505,715 coronary angiographies and 257,936 cerebral angiographies). The median age was 62.9 years, with females being 46.42%. Our cohort most-prevalent comorbidities were hypertension (69.92%), coronary artery disease (69.48%), smoking (35.64%), and diabetes mellitus (35.13%). The most common in-hospital complications included acute/unspecified renal failure (9.26%), respiratory failure (6.36%), hemorrhage/hematoma complicating a procedure (1.13%), hemorrhage requiring blood transfusion (0.63%), deep vein thrombosis and/or pulmonary embolism (0.62%), and perioperative stroke (hemorrhagic and/or ischemic) 0.15%. The majority of patients were discharged to home (77.62%), with inpatient mortality being 1.06%.

Conclusions:

Our study showed that renal and respiratory failure are the most common complications. Only <1% perioperative strokes were reported. Further study is recommended to identify potential patient- and hospital-level risk factors increasing burden of in-hospital complications.

Keywords: Angiogram, Endovascular, Intravascular Imaging

Financial Disclosures: The authors had no disclosures.

Grant Support: None.

Poster

A Real-World Study of Enterprise Stent Assisted Coiling in Treating Intracranial Ruptured Aneurysms

Zhenbao Li, Doctor¹, Chang Bi, Senior specialist², Bingbing Zhang, Doctor¹, Xigen Fang, Doctor¹, Xintong Zhao, Doctor¹, Jiaqiang Liu, Doctor¹, Niansheng Lai, Doctor¹, Jianwei Xuan, Pofessor³

¹Yijishan hospital of Wannan Medical College, Wuhu, China; ²Johnson and Johnson Medical (Shanghai)Limited, Shanghai, China; ³Health Economics Research Institute, Sun Yat-sen University, Guangzhou, China

Introduction:

Enterprise™ stent is an innovative, self-expandable nitinol stent system used in stent-assisted coiling (SAC). Although the technology is a well-accepted clinical practice, data is limited on its real-world clinical effectiveness in ruptured intracranial aneurysms (RIA) treatment. The objective of this study was to evaluate the clinical effectiveness of Enterprise™ stent in treating RIA in a real-world setting in China.

Methods:

A retrospective database analysis was conducted using electronic medical records from January 2013 to June 2018 at Yijishan hospital of Wannan Medical College. Patients diagnosed as RIA and underwent SAC procedure with Enterprise™ stent were identified from the database. All clinical information was abstracted from the database. The immediate complete occlusion (Raymond-Roy class I) rate, good outcome (modified Rankin Scale ≤ 2), intraoperative complications were measured as outcomes.

Results:

A total of 270 eligible patients were included and 70.7% were female. Median age was 59.50 year. More than half of aneurysms located in posterior communicating artery (33.23%), and anterior communicating artery (22.91%). The mean size of aneurysms was 4.6 ± 2.8 mm, 50.4% in small size (< 5 mm) and 48.1% in medium size (5-15 mm) while the mean neck width of aneurysms was 4.1 ± 1.9 mm. The stent deployment was all successful. Immediate complete occlusion was achieved in 75.1%. Most of patients achieved good outcome at discharge (81.1%) and at the last follow-up (81.8%)(mean follow-up 102.79 days), among this, mRS=0(no symptoms at all) increased 10.74% from 57.04% to 67.78%. The intraoperative complication rate was 13.0% in total, including hemorrhage events (2 cases, 0.7%), and ischemic events (33 cases,12.3%). Univariate analysis showed in the patients with ischemic events, the neck width of aneurysm was wider ($P=0.017$).

Conclusions:

The application of Enterprise™ stent demonstrated encouraging clinical effectiveness in treating RIA in China.

Keywords: Aneurysm

Financial Disclosures: The authors had no disclosures.

Grant Support: None.

Poster

Computational Fluid Dynamics versus Angiographic Flow Diversion Analysis of Evolve, Pipeline, and LVIS Devices

Chander Sadasivan, PhD¹, Nakisa Dashti, BSc², Elisabeth Steadman, MSc², Ram Ghosh, PhD², Brandon Kovarovic, PhD², David Fiorella, MD, PhD¹

¹*Stony Brook University Medical Center, Stony Brook, New York, United States of America*; ²*Stony Brook University, Stony Brook, New York, United States of America*

Introduction:

Several different flow diverter designs are used to treat aneurysm patients globally. Numerous studies have been conducted to analyze the changes in intraneurysmal flow using Computational Fluid Dynamics (CFD) as well as Angiographic quantification. Both techniques have their advantages and disadvantages but very few studies have directly compared these methods [1, 2]. The primary goal of this study was to correlate CFD and Angiographic parameters in the context of flow diversion. The secondary goal was to assess the relative flow diversion efficacy of the tested devices.

Methods:

Copies of three patient-specific silicone replicas (Models-I to III) of carotid aneurysms were manufactured. Four devices (Surpass Evolve, Pipeline Shield, FRED, and LVIS Blue) were deployed in Model-I, and two devices (Evolve and Pipeline) were deployed in both Model-II and Model-III. Angiographic runs were acquired (n=6 injections per case) and intraneurysmal time-density curves were quantified with seven parameters based on transit-time and contrast transport mechanisms (Figure A, gray boxes) [3]. The replicas were scanned with micro-CT at 10.3 μm resolution (4.3 μm for FRED) and the wall apposition of the devices was calculated (3Matic, Materialise) along the device length. The micro-CT scans were converted to meshes for CFD simulations (Fluent, ANSYS). Flow diversion efficacy of the devices was assessed based on reduction in Angiographic parameters and CFD volumetric average intraneurysmal velocity (Figure A) and surface average wall shear stress (WSS). Correlations between mean Angiographic and CFD parameters were statistically evaluated (Instat, GraphPad).

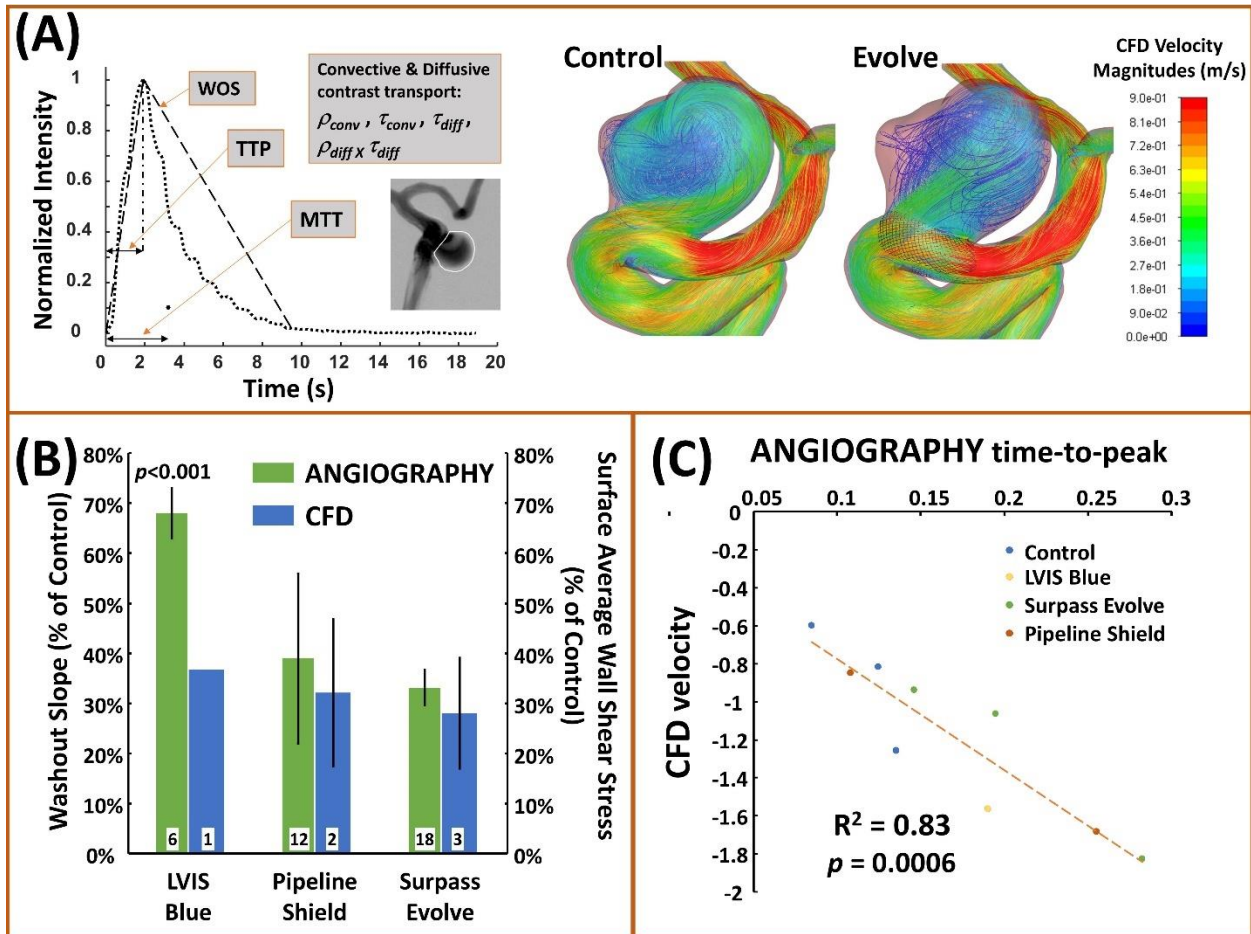
Results:

Only the FRED device had a statistically poorer apposition (0.46+/-0.3 mm gap, $p < 0.0001$) than other devices (0.23+/-0.12 mm). The Model-III Pipeline device was inadvertently dislodged during preparation for micro-CT. These two cases were discarded. Overall CFD and Angiographic trends clearly showed that the effectiveness of intraneurysmal flow reduction was Evolve > Pipeline > LVIS Blue (Figure B). The time-to-peak (TTP, $R^2=0.83$, $p=0.0006$) (Figure C) angiography parameter representing the contrast wash-in phase and the convective decay constant parameter (τ_{conv} , $R^2=0.46$, $p=0.04$) representing the contrast wash-out phase significantly correlated to the CFD aneurysmal velocity.

Conclusions:

Based on the design parameters of the four devices tested, intraneurysmal flow diversion efficacy is directly related to higher device metal coverage and pore density. The moderate to strong correlations found between CFD and Angiographic analyses suggest that both techniques can be reliably used to

quantify aneurysmal flow reduction. CFD analysis can be a valuable tool for pre-treatment device selection whereas Angiographic analysis can provide real-time guidance during the procedure.



Keywords: Angiogram, Cerebral Blood Flow, Flow Diverter, Pipeline, Surpass

Financial Disclosures: Research Grant Support: Stryker Neurovascular Research Grant Support, Consulting Fees, Stock Owner: Vascular Simulations

Grant Support: Stryker Neurovascular: SUNY RF award #82609/project #1149207

Poster

MANAGEMENT OF ANEURYSM ASSOCIATED WITH MOYAMOYA DISEASE: A CASE SERIES OF 5 PATIENTS

Noor ul h Maria, PGR¹, Qurrat ul ain Siddiq, Assoc.Prof², Ali Hammed, Postgrad Resident³

¹Punjab Institute of Neurosciences, LAHORE, Pakistan; ²PGMI, LAHORE, Pakistan; ³Tishreen University Hospital, Lattakia, Syrian Arab Republic

Introduction:

Moyamoya disease is a rare vascular disorder causing blockage of the carotid artery in the skull, reducing blood flow to the brain and causing resultant opening of tiny blood vessels at the base of the brain the flame shaped "Moyamoya" vessels in an attempt to supply the brain with blood. The first symptom of moyamoya disease is usually stroke especially in children. Adults also may experience these symptoms but also experience bleeding in the brain from abnormal brain vessels. MMD is occasionally accompanied by intracranial aneurysms. The incidence of intracranial aneurysms in patients with MMD has been estimated to be 3%–14% in adults. The prognosis of MMD with aneurysms is unfortunately poor. There are various options to treat the aneurysms associated with MMD. Since the vascular dynamics are different than normal and there are risks associated in the presence of MMD, surgery needs to be performed with proper planning and training with attention to pre and postop management as well. Endovascular treatment has now gained interest in the management of aneurysms associated with MMD

We performed this study to compare the surgical treatment with endovascular treatment in the management of MMD-associated aneurysms

Methods:

Study was conducted on 5 patients with aneurysms associated with MMD. Age range was 18-45, 3 females and 2 males, 2 were anterior communicating artery aneurysms, 1 at bifurcation of ICA and AchA, 1 posterior communicating and the other one was paraclinoidal artery aneurysm. Hunt-Hess score was 3 in 4 cases and was 4 in one case with anterior communicating artery aneurysm. Surgical clipping with STA-MCA anastomosis was performed in one patient with a-comm aneurysm while the other one had only clipping performed and he died on 2nd postoperative days, endovascular coiling was performed for the rest of the patients.

Results:

Patients who underwent endovascular coiling had a better outcome as compared to the surgically treated group. Surgery is challenging in the case of Moyamoya disease. Many surgeons do not have enough experience to perform surgery in cases with Moyamoya disease, many do not have experience of STA-MCA anastomosis as well. The risk of vasoconstriction is high after surgical manipulations and there can be disruption of the established collateral circulation during surgery. 2 patients (both with anterior communicating artery aneurysm) were surgically treated, 1 had a good recovery while the other died. Those patients who were treated with endovascular coiling made a remarkable recovery

Conclusions:

From our study we conclude that endovascular coiling is a safe and better option for patients having aneurysm associated with Moyamoya disease

Keywords: Aneurysm

Financial Disclosures: The authors had no disclosures.

Grant Support: None.

Poster

Volumetric analysis as an index of intracranial aneurysm growth

Ashrita Raghuram, BSE¹, Alberto Varon Miller, MD¹, Ryan Sabotin, BS¹, Jorge Roa, MD¹, Edgar Samaniego, MD, MS¹

¹*Department of Neurology, University of Iowa Hospitals and Clinics, Iowa City, Iowa, United States of America*

Introduction:

Aneurysm growth of unruptured intracranial aneurysms is traditionally assessed using subjective 2D measurements. There are many variables to consider in selecting the most accurate measurements, including the image windowing, slice choice, and marker placement. Comparing 2D measurements between two different clinicians may lead to disagreement and inaccuracies. Although the same clinician may measure the aneurysm, reliably measuring the aneurysm at two different time points requires strict control of all of these variables. Volumetric measurements may provide a more holistic view of aneurysm growth by considering more subtle dimension changes. The efficacy of volume measurement as a tool for characterizing aneurysm growth was investigated in this follow-up study.

Methods:

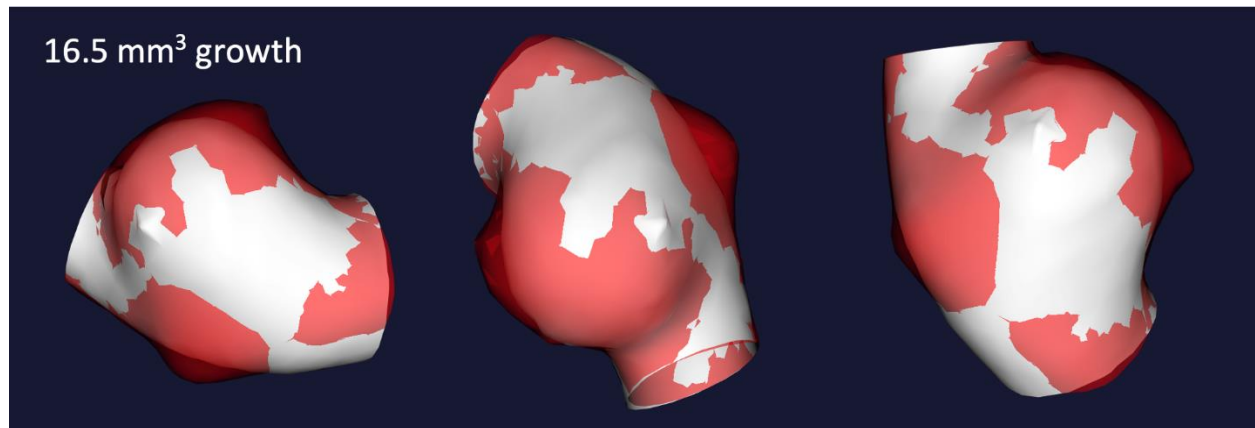
Patient imaging was collected from May 2015 to September 2020 using 3T and 7T MRI protocols. MR angiogram and T1-post contrast MRI images were analyzed retrospectively. Aneurysms under 3 mm in size were excluded from the study. Each aneurysm was segmented MRA images using the Vascular Modeling Tool Kit (VMTK), and volume changes were compared against a clinical expert's size measurements of the aneurysm neck, dome height, and diameter on the T1 post-contrast MRI images. Both saccular and fusiform aneurysms were analyzed. Aneurysm wall enhancement was quantified using high-resolution vessel wall imaging on T1-post contrast MRI sequences. Volume change in correlation with ELAPSS score was also investigated.

Results:

12 patients with 15 aneurysms total were included in the study. The mean follow-up time was 9.6 months. Of the 15 aneurysms segmented, 12 were measured by a clinical expert. Measurements of change in volume agreed with clinical rating in 9 instances. For most aneurysms, diameter was a reliable dimension for volumetric growth correlation. There were no trends found between aneurysm wall enhancement and volume change. A study on the interrater reliability of the 2D measurement system resulted in low kappa scores.

Conclusions:

Volume analysis may provide a more accurate metric for aneurysm growth than simple 2D size measurements. Using MRA-segmented aneurysms as a basis for volume analysis allows for an accessible and less invasive technique for assessing aneurysm growth. Volume analysis can also provide insight into the growth of fusiform aneurysms, where global dilation is more common and harder to detect in one 2D slice.



ICA aneurysm growth characterized by overlaying 3D segmentations of baseline (white) and follow up (red) MRA images.

Keywords: Aneurysm, Intracerebral Aneurysm, MRI, MRA,

Financial Disclosures: The authors had no disclosures.

Grant Support: This work was supported by the 2019 Brain Aneurysm Research Grant from The Bee Foundation and by a Pilot Research Grant from the Society of Vascular and Interventional Neurology (SVIN), both granted to Edgar Samaniego.

Poster

Identifying Long-term Hemodynamic Adaptations Following Pipeline Embolization with Quantitative Magnetic Resonance Angiography

Brendan Ryu, BS¹, Timothy G White, MD¹, Kevin A Shah, MD¹, Justin Turpin, MD¹, Thomas Link, MD¹, Amir R Dehdashti, MD¹, Jeffrey Katz, MD², Henry H Woo, MD¹

¹Department of Neurosurgery, Zucker School of Medicine at Hofstra/Northwell, Manhasset, New York, United States of America; ²Department of Neurology, Zucker School of Medicine at Hofstra/Northwell, Manhasset, New York, United States of America

Introduction:

The Pipeline Embolization Device (PED) has rapidly become the endovascular treatment of choice for unruptured wide neck internal carotid artery (ICA) aneurysms, with multiple studies demonstrating excellent safety and rates of occlusion. Quantitative magnetic resonance angiography (QMRA) with Non-invasive Optimal Vessel Analysis (NOVA) serve as powerful tools to collect and analyze hemodynamic data from post-Pipeline embolization patients. At our institution, all patients receive post embolization QMRA within 24 hours of treatment and within four months for follow-up to evaluate Pipeline patency. With the follow-up data, we aim to elucidate the long-term hemodynamic adaptations following PED placement.

Methods:

Medical records of patients who underwent PED placement for a distal ICA aneurysm between 2017 to 2019 were reviewed. Those patients who received post (post-NOVA) and four-month follow-up PED QMRA NOVA (F/U-NOVA) were included in the study (n=32). Location of aneurysm, number of Pipeline devices, post-procedural complications, aneurysm size, and aneurysm occlusion were collected along with the NOVA report, which shows flow volume rate (ml/min), mean, systolic, and diastolic flow velocities (cm/s), and vessel diameter (mm). ICA vessel flow rate was measured proximal to the PED. MCA and ACA measurements were made in the M1 and A2 segments, respectively. Derivations of hemodynamic parameters (pulsatility index (PI), Lindegaard ratio, and wall shear stress (WSS)) were calculated.

Results:

The MCA mean flow velocity from the F/U-NOVA was significantly lower than that of the post-NOVA (20.7 vs. 23.0; P=0.03). Moreover, F/U-NOVA reflects lower MCA WSS on the side with flow diversion when compared to that of the post-NOVA (16.2 vs. 17.6; P=0.07). There was no difference in ICA or ACA WSS and mean flow velocity when comparing post-NOVA and F/U-NOVA. MCA diastolic velocity was significantly lower in F/U-NOVA compared to post-NOVA (18.0 vs. 19.7; P=0.02). Systolic velocity was not different in any vessel and there was no difference in vessel diameter when comparing post-NOVA to F/U-NOVA. Interestingly, flow volume rate was not altered for all vessels when comparing between post-NOVA and F/U-NOVA. Mean PI and Lindegaard ration were not different between the post-NOVA vs. F/U-NOVA in the ICA, MCA, or ACA.

Conclusions:

Long-term hemodynamic adaptations post PED demonstrate decreased WSS, mean flow velocity, and diastolic velocities distal to the stent in the MCA territory with the analysis showing no difference when comparing the post-NOVA to F/U-NOVA in ICA and ACA. Of note, the Lindegaard ratio is also not different when comparing the post-NOVA to F/U-NOVA for all territories. These findings suggest decreasing velocity of flow with endothelialization of the device in the territory distal to the PED.

Keywords: Aneurysm Embolization, Angiographic Technology, Cerebral Blood Flow, Pipeline, MRA

Financial Disclosures: The authors had no disclosures.

Grant Support: None.

Poster

Utility of Quantitative Magnetic Resonance Angiography in Characterizing Hemodynamic Changes Following Pipeline Embolization

Timothy G White, MD¹, Brendan Ryu, BS¹, Kevin A Shah, MD¹, Justin Turpin, MD¹, Thomas Link, MD¹, Amir R Dehdashti, MD¹, Jeffrey Katz, MD², Henry H Woo, MD¹

¹Department of Neurosurgery, Zucker School of Medicine at Hofstra/Northwell, Manhasset, New York, United States of America; ²Department of Neurology, Zucker School of Medicine at Hofstra/Northwell, Manhasset, New York, United States of America

Introduction:

Delayed intraparenchymal hemorrhage is a known complication of the Pipeline Embolization device (PED); however, the etiology of this is unclear. Flow changes of intracranial vessels have been implicated as a contributing factor. Empirical evidence of the pathophysiology is not adequately outlined in the literature. The advent of quantitative magnetic resonance angiography (QMRA) and Non-invasive Optimal Vessel Analysis (NOVA) serves as a powerful tool to collect and analyze hemodynamic data from post-Pipeline embolization patients. We aim to report a detailed characterization of short-term hemodynamics after PED placement.

Methods:

Medical records of patients who underwent PED placement for a distal internal carotid artery (ICA) aneurysm between 2017 to 2019 were reviewed. Patients who received post-PED QMRA NOVA were included in the study (n=67). Location of aneurysm, number of Pipeline devices, post-procedural complications, aneurysm size, and aneurysm occlusion were collected along with the NOVA report, which shows flow volume rate (ml/min), mean, systolic, and diastolic flow velocities (cm/s), and vessel diameter (mm). ICA vessel flow rate was measured proximal to the PED. MCA and ACA measurements were made in the M1 and A2 segments, respectively. Derivations of hemodynamic parameters (pulsatility index (PI), Lindegaard ratio, and wall shear stress (WSS)) were calculated.

Results:

Post-procedure patients were found to have a significantly lower ICA flow on the side with flow diversion when compared to the side without flow diversion (218 vs. 236; P<0.05). The effect on flow was not seen when aneurysms >2cm (n=7) were no longer included in the analysis. Average ICA flow after flow diversion for aneurysms >2 cm was significantly lower when compared to the untreated side (188 vs. 240; P<0.05). There was no difference in MCA or ACA flow when comparing treated to untreated side. Mean velocity was found to be significantly lower in the treated ICA compared with the contralateral ICA (16 vs. 17; P<0.05). There was no difference in mean velocity in the MCA or ACA. Maximum velocity was not different in any vessel. There was no difference in vessel diameter when comparing treated to untreated sides. WSS was significantly lower in the ICA with flow diversion (8 vs. 9; P<0.05). There was no difference in WSS in the ACA or MCA when comparing treated and untreated sides. Mean PI was not different between the treated vs. untreated sides in the ICA, MCA, or ACA. Finally, Lindegaard ratio was not different in the treated vs. untreated sides even in the cohort with aneurysms >2cm.

Conclusions:

PED placement for distal ICA aneurysms results in lower flow, mean velocity, and WSS when compared to the untreated ICA. This effect was mainly seen after embolization for aneurysms >2cm. However, this change is not demonstrated distal to the Pipeline device in the ACA or MCA territories. Ultimately these findings support the theory that embolic phenomenon may precipitate delayed hemorrhagic complications as we did not demonstrate significant distal flow changes.

Keywords: Aneurysm Embolization, Angiographic Technology, Cerebral Blood Flow, Pipeline, MRA

Financial Disclosures: The authors had no disclosures.

Grant Support: None.

Poster

Flow Diverter vs Stent-assisted Coiling for the Management of Ruptured Aneurysms: A Meta-analysis of Prevalence

Ayman Bsath, MD¹, Shadi Bsath, MD², Hani Chanbour, MD¹, Charbel Moussalem, MD², Mohamad Nabih El Houshiemy, MD², Safwan Alomari, MD³, Sarah Kawtharani, MD², Adham Halaoui, MD², Houssein Darwish, MD²

¹Lebanese University - Faculty of Medical Sciences, Beirut, Lebanon; ²Department of Neurosurgery, American University of Beirut Medical Center, Beirut, Lebanon; ³Department of Neurosurgery, The Johns Hopkins School of Medicine, Beirut, Lebanon

Introduction:

Flow diversion and stent-assisted coiling are both integral treatment modalities in the neurointerventional toolkit that are enjoying emerging indications and continuously evolving applications. However, reports of their usage in the setting of acute aneurysmal subarachnoid hemorrhage are still relatively limited and clouded by controversy. Thus, we aimed to systematically review the literature and compare the occlusion rates, complication rates, clinical outcomes and mortality rates between flow diverters and stent-assisted coiling when used in the setting of an acutely ruptured aneurysm.

Methods:

We searched PubMed and Google Scholar for articles published between 2009 and 2019 and stratified selected articles based on risk of publication bias. Data on occlusion rates, procedure-related complication rates, clinical outcomes and mortality rates were analyzed using quality-effects model and double arcsine transformation to determine their pooled prevalence.

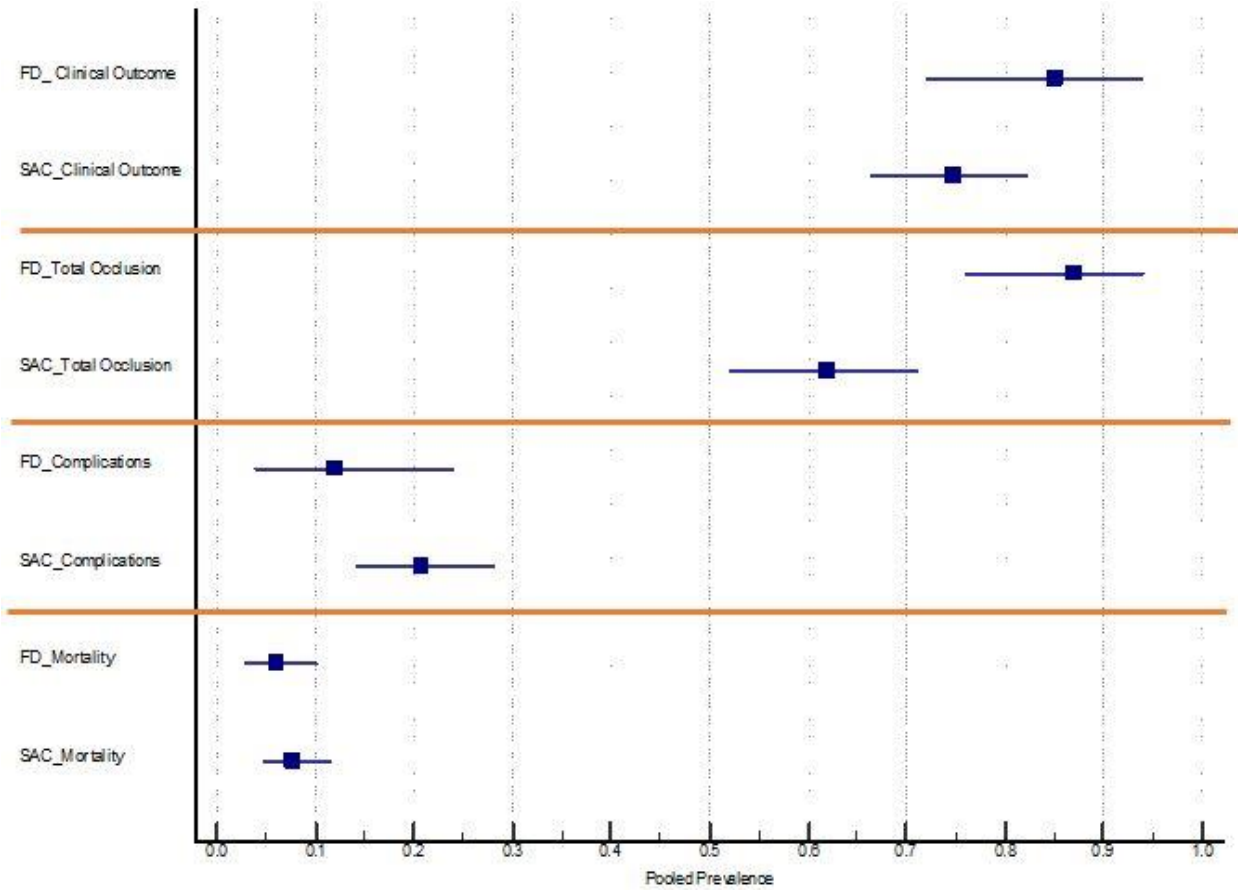
Results:

31 articles on flow diverters and 24 articles on stent-assisted coiling were included, comprising 722 and 1582 patients, respectively. Most of the articles were retrospective cohort studies featuring a limited number of patients. Favorable clinical outcomes (modified Rankin scale 0 - 2) were reported in 85.0% [95% CI: 72 - 94%; I²=80.0] of patients that received flow diverters and in 74.7% [95% CI: 66.4 - 82.2%; I²=86.0] of patients that received stent-assisted coiling. Complete occlusion (Raymond-Roy class 1) was achieved in 87.0% [95% CI: 76 - 94%; I²=67%] of aneurysms treated with flow diverters and in 62.0% [95% CI: 52 - 71%; I²=92%] of aneurysms treated with stent-assisted coiling. Total procedure-related complication rate was 12.0% [95% CI: 4 - 24%; I²=79%] in flow diverter group and 20.8% [95% CI: 14.2 - 28.1%; I²=87.0%] in stent-assisted coiling group. Overall mortality rate amounted to 6.0% [95% CI: 3 - 10%; I²=45%] in patients treated with flow diverters and 7.8% [95% CI: 4.8 - 11.6%; I²=76.9%] in patients treated with stent-assisted coiling.

Conclusions:

Both flow diversion and stent-assisted coiling of acutely ruptured intracranial aneurysms are feasible procedures. Acutely ruptured intracranial aneurysms managed with flow diverter stents appeared to have lower complication and overall mortality rates when compared to those treated with stent-assisted coiling. In addition, it seems that flow diverters are associated with higher rates of total angiographic

occlusion and favorable clinical outcome. Our study was limited by significant publication bias and there is a need for randomized control trials to determine if there are any statistically significant difference in outcomes between flow diverters and stent-assisted coiling when used to manage acutely ruptured intracranial aneurysms.



Graph 1: Pooled Prevalence of favorable clinical outcomes, total occlusion rate, total complication rate and mortality of flow diverter and stent-assisted coiling. FD = Flow diverter; SAC = Stent-assisted coiling

Keywords: Flow Diverter, Stent Assisted, Ruptured, Subarachnoid Hemorrhage, Aneurysm

Financial Disclosures: The authors had no disclosures.

Grant Support: None.

Poster

US Single-center, initial use of the Comaneci Device—a temporary bridging device used during coil embolization

Muhammad A Taqi, MD, FAHA¹

¹*Vascular Neurology of Southern California, Thousand Oaks, United States of America*

Introduction:

In April 2019, Rapid Medical (Yokneam, Israel) received FDA 510(k) clearance for its Comaneci device. The Comaneci acts as a temporary bridging device that can be deployed across the neck of an intracranial aneurysm during coil embolization. The device is an adjustable and fully-visible remodeling tool, through which coiling may occur without obstruction of antegrade flow in the parent artery and can be removed once the coiling procedure is complete. Here we report our single-center experience using the device in the 16-months since commercial availability in the United States.

Methods:

The data reported in this study were obtained during retrospective review of a single center's patients all of whom were designated to coil embolization of an unruptured or ruptured intracranial aneurysm. The inclusion criteria for this review was the use of the Comaneci device during index procedure. Our institution collected information of patients who visited our center between June 2019 and August 2020. Here we demonstrate our clinical specifications, angiographic variables, and endovascular procedure results.

Results:

Included in our study sample are 16 total individuals found with intracranial aneurysms and designated for coil embolization, 12 of which are female and 4 are male. The mean age was 59 years (range from 42-81). Of the total 8 presented with ruptured intracranial aneurysms and 8 unruptured. The locations intracranial aneurysms varied with 7 located in the anterior communicating artery, 6 located in the middle cerebral artery, one in posterior communicating artery, one anterior cerebral artery, and one vertebral artery. The mean aneurysm width measured at 5.59 mm (range 3.4-9.9), the mean neck size was 3.44 mm (range 1.93-6.5), and the mean height was 5.50 mm. The mean dome-to-neck ratio was 1.74 mm (range 0.87-3.39). During procedure all patients were administered Heparin, most with unruptured aneurysms received Aspirin and Plavix therapy. Otherwise, patients who presented with ruptured aneurysms received no antiplatelet therapy, furthermore, five of sixteen patients received Aspirin alone. In 14 of 16, only one Comaneci device was deployed at a time. In 2 of 16 cases, two Comaneci devices were deployed simultaneously. The mean device exposure time was 21.8 minutes (range 9-56). Immediately post-procedure angiographic imaging demonstrated complete occlusion of target aneurysm was achieved in 10 patients, near-complete occlusion was noted in 5 patients, 1 patient demonstrated residual filling. Complications were only noted in one case but were corrected without clinical sequelae.

Conclusions:

Our results, while limited due to sample size and single-center experience, shows that the Comaneci device is a reasonable and safe alternative to stenting or use of a balloon guide catheter during coil

embolization of intracranial aneurysms. Our initial encounter with the device proves positive and promising.

Keywords: Aneurysm Embolization, Coiling, Cerebrovascular Disease, Intracerebral Aneurysm, Embolization

Financial Disclosures: MAT reports consulting fees for advisory roles for Rapid Medical and Balt, LLC.

Grant Support: None.

Poster

Predictors of Symptomatic Hemorrhage after Endovascular Treatment for Anterior Circulation Stroke: A Multicenter Analysis

Semih Giray, Doctor Of Neurology¹, Nihat Sengeze, Doctor of Neurology², Atilla Ozcan Ozdemir, Doctor of Neurology³, Vedat Ali Yurekli, Doctor of Neurology², Alper Eren, Doctor of Neurology⁴, Semih Giray, Doctor of Neurology¹, Yusuf Inanc, Doctor of Neurology¹, Ozlem Aykac, Doctor of Neurology³, Cetin Kursat Akpınar, Doctor of Neurology⁵, Serhan Yildirim, Doctor of Neurology⁶, Elif Sarionder Gencer, Doctor of Neurology⁷, Bilgehan Acar, Doctor of Neurology⁸, Erdem Gurkas, Doctor of Neurology⁹, Ayca Ozkul, Doctor of Neurology¹⁰, Emrah Aytac, Doctor of Neurology¹¹, Mustafa Gokce, Doctor of Neurology¹², Aysel Milanlioglu, Doctor of Neurology¹³, Recep Baydemir, Doctor of Neurology¹⁴, Demet Funda, Doctor of Neurology¹⁵, Utku Cenikli, Doctor of Neurology¹⁶, Murat Cabalar, Doctor of Neurology¹⁷, Ahmet Sair, Doctor of Neurology¹⁰, Talip Asil, Doctor of Neurology¹⁸

¹Gaziantep University Medicine Faculty Hospital, Gaziantep, Turkey; ²Suleyman Demirel University Hospital, Isparta, Turkey; ³Eskisehir Osmangazi Medicine Faculty Hospital, Eskisehir, Turkey; ⁴Ataturk University Hospital, Erzurum, Turkey; ⁵Samsun Training and Research Hospital, Samsun, Turkey; ⁶Derince Training and Research Hospital, Kocaeli, Turkey; ⁷Antalya Training and Research Hospital, Antalya, Turkey; ⁸Sakarya University Medicine Faculty Hospital, Sakarya, Turkey; ⁹Kartal Dr.Lütfi Kırdar Training and Research Hospital, İstanbul, Turkey; ¹⁰Adnan Menderes University Hospital, Aydın, Turkey; ¹¹Firat University Medicine Faculty Hospital, Elazığ, Turkey; ¹²Sutcu Imam University Hospital, Kahramanmaraş, Turkey; ¹³Yuzuncu Yil University Hospital, Van, Turkey; ¹⁴Erciyes University Hospital, Kayseri, Turkey; ¹⁵Tepecik Training and Research Hospital, İzmir, Turkey; ¹⁶Sitki Kocman University Hospital, Muğla, Turkey; ¹⁷Bakırköy Dr Sadi Konuk Training&Research Hospital, İstanbul, Turkey; ¹⁸King Hamad University Hospital, Busaiteen, Bahrain

Introduction:

Acute large vessel occlusions account for 25% to 40% of all acute ischemic strokes and cause significant morbidity and mortality. Hemorrhagic transformation is a devastating complication that can develop after the endovascular treatment of strokes due to large vessel occlusion.

Although endovascular treatment does not increase the risk of SIH, identifying patients with a high risk of bleeding and revealing predictive factors can increase the efficacy and safety of endovascular therapy.

Here, we aimed to evaluate the predictive factors of hemorrhagic transformation and symptomatic intracranial hemorrhage in acute anterior circulation occlusions with endovascular treatment.

Methods:

The study is derived from the endovascular database, where data is entered in a multi-centered (Turkish Interventional Neurology Database) manner. A total of 975 patients from the center were included in the study. The study was planned prospectively, the data were recorded in a data system from these centers, and then the data were analyzed retrospectively.

Results:

The average age of 975 patients included in the study was 65.2±13.1, and 469 (48.1%) were women. The mean NIHSS was 15.6±4.5 and ASPECT score was 8.7±1.3.

When patients included in the study were grouped according to the development of cerebral hemorrhage in control CT, the history of hypertension and diabetes was significantly higher in patients who developed SIH (p; 0.027 and <0.001, respectively). However, while there was no significant difference in systolic blood pressure values at the time of admission for patients with SIH, significantly higher symptomatic hemorrhage developed in patients with high diastolic blood pressure (p: 0.017).

The multivariate logistic analysis of the predictive factors detected in patients who developed SIH was presented in Table 2. OR in patients with diabetes mellitus, 2.01; 95% CI, (1.35-2.95), applicants with higher NIHSS OR, 1.08; 95% CI (1.04-1.14), time from stroke symptoms onset to puncture and recanalization were determined as OR, 1.09, 95% CI, (1.00-1.01). In patients with high total intracranial procedures during the endovascular treatment, OR, 1.17; 95% CI (1.05-1.30) and intraarterial thrombolytic was detected as OR, 1.70; 95% CI (1.15-2.50).

Conclusions:

Identifying predictors of intracerebral hemorrhage after endovascular treatment may guide us to prevent this devastating complication.

Table 1: Evaluation of demographic and clinical data of patients according to the occurrence of symptomatic intracranial hemorrhage

Demographic and clinical data	Symptomatic Intracranial Hemorrhage		p-value
	Non-SIH (n=845)	With SIH (n=133)	
Age, median (IQR), years	67 (57-75)	68 (58-76)	0.356
Gender (female), n(%)	406 (48.2)	63 (47.4)	0.855
Hypertension, n (%)	607 (72.1)	108 (81.2)	0.027
Diabetes, n (%)	229 (27.2)	59 (44.9)	<0.001
Atrial fibrillation, n (%)	315 (37.5)	58 (43.6)	0.175
Smoking, n,(%)	257 (30.6)	45 (33.8)	0.448
Coronary artery disease, n (%)	217 (25.8)	36 (27.1)	0.751
Passed stroke, n (%)	71 (8.4)	13 (9.8)	0.608
Obesity, n (%)	123 (14.8)	17 (12.9)	0.560
Antiagregan usage history, n (%)	270 (32.1)	43 (32.3)	0.952
Anticoagulant use history, n (%)	67 (8)	10 (7.5)	0.862
Clinical measures			
Systolic blood pressure, median (IQR), mm Hg	150 (130-170)	150 (137.5-170)	0.064
Diastolic blood pressure, median (IQR), mm Hg	80 (80-95)	90 (80-100)	0.017
Application NIHSS, median (IQR)	16 (12-18)	18 (14-19)	<0.001
Application ASPECT, median (IQR)	9 (8-10)	9 (8-10)	0.516
Glucose, median (IQR), mg / dL	126 (107-160)	148 (119-197)	<0.001
Leukocyte, median (IQR), 10 ³ /L	9510 (7800-11800)	10300 (8000-12900)	0.05
Platelet, median (IQR), 10 ³ /L	232 (189-284)	239 (180-285)	0.745
RDW, median (IQR),%	14.3 (13.4-15.6)	14.4 (13.7-15.5)	0.391
Causes of stroke			
Extracranial atherosclerosis, n (%)	119 (14.1)	15 (11.3)	0.374
Cardioembolic, n (%)	348 (41.3)	50 (37.6)	0.415
Intracranial atherosclerosis, n (%)	23 (2.7)	3 (2.3)	0.752
Other, n (%)	352 (41.8)	65 (48.9)	0.126
Occlusion Location			

Tandem, n (%)	157 (18.6)	30 (22.6)	0.287
Internal carotid artery, n (%)	139 (16.5)	23 (17.3)	0.821
MCA M1 proximal, n (%)	336 (39.9)	54 (40.6)	0.879
MCA M1 distal, n (%)	96 (11.4)	15 (11.3)	0.967
MCA M2, n (%)	105 (12.5)	9 (6.8)	0.057
ACA, n (%)	9 (1.1)	2 (1.5)	0.659
Endovascular evaluation and results			
Symptom - puncture time, median (IQR), min	210 (145-284)	240 (180-300)	0.005
Symptom - recanalization time, median (IQR), min	260 (195-344)	300 (247-370)	<0.001
Successful mTICI 2b-3 recanalization, n (%)	724 (86)	116 (87.2)	0.702
Successful mTICI 2b-3 recanalization, n (%)	557 (66.2)	72 (54.1)	0.007
Recanalization with the first pass, n (%)	377 (44.8)	43 (32.3)	0.007
Successful recanalization (mTICI 2c-3) first 45 minutes, n (%)	376 (44.8)	40 (30.1)	0.001
The total intracranial procedure, median (IQR)	2 (1-3)	3 (2-3)	<0.001
Intravenous thrombolytic, n (%)	226 (26.8)	31 (23.3)	0.390
Intraarterial thrombolytic, n (%)	218 (25.9)	53 (39.8)	0.001
ADAPT technique, n (%)	171 (20.3)	30 (22.6)	0.552
Stent retriever used, n (%)	682 (81.2)	114 (85.7)	0.209
Third-month mRS (0-2), n (%)	406 (48.2)	14 (10.2)	<0.001
Third-month mortality, n (%)	158 (18.8)	76 (57.1)	<0.001

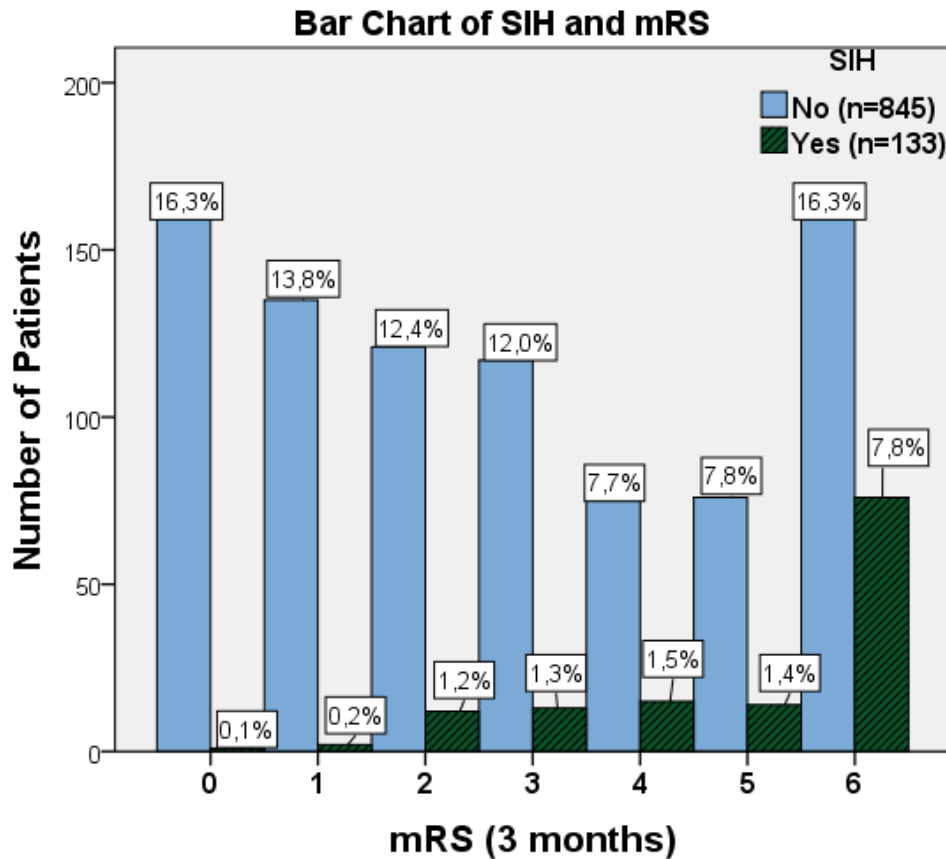
SIH, Symptomatic Intracranial Hemorrhage; IQR, interquartile range; NIHSS, National Institute of Health Stroke Scale; ASPECTS, Alberta Stroke Program Early Computed Tomography Score; RDW, Red Distribution Width; MCA, Middle Cerebral Artery; ACA, Anterior Cerebral Artery; mTICI, modified Thrombolysis in Cerebral Infarction; mRS: modified Rankin Scale; ADAPT, A Direct Aspiration First Pass Technique

Table 2: Multivariate logistic analysis of predictors of SIH after endovascular treatment of anterior circulation stroke

Multivariate Analysis of Predictors of SIH After Endovascular Treatment	Beta	OR [95% CI]	p value
<i>Stroke risk factors and pre-procedure factors</i>			
Hypertension, n (%)	0.34	1.40 (0.85-2.30)	0.182
Diabetes, n (%)	0.69	2.01 (1.35-2.95)	0.001
Diastolic blood pressure, median (IQR), mm Hg	0.05	1.00 (0.99-1.01)	0.547
Application NIHSS, median (IQR)	0.73	1.08 (1.04-1.14)	0.002
Glucose, median (IQR), mg / dL	0.01	1.00 (0.99-1.00)	0.540
Leukocyte, median (IQR), 10 ³ /L	0.001	1.00 (1.00-1.00)	0.045
Symptom - puncture time, median (IQR), min	0.09	1.09 (1.00-1.01)	0.004
Symptom - recanalization time, median (IQR), min	0.09	1.09 (1.00-1.01)	0.001
<i>Endovascular treatment factors</i>			
Successful mTICI 2b-3 recanalization, n (%)	0.24	1.26 (0.84-1.91)	0.256
Recanalization with the first pass, n (%)	0.05	1.05 (0.64-1.73)	0.838
Successful recanalization (mTICI 2c-3) first 45 minutes, n (%)	0.27	1.30 (0.79-2.14)	0.766
The total intracranial procedure, median (IQR)	0.16	1.17 (1.05-1.30)	0.004
Intraarterial thrombolytic, n (%)	0.53	1.70 (1.15-2.50)	0.007
<i>Prognostic factors</i>			
Third-month mRS (0-2), n (%)	1.51	4.55 (2.46-8.44)	0.001
Third-month mortality, n (%)	1.15	3.17 (2.09-4.83)	0.001

NIHSS, National Institute of Health Stroke Scale; ASPECTS, Alberta Stroke Program Early Computed Tomography Score; CI, confidence interval; mTICI, modified Thrombolysis in Cerebral Infarction; OR, odds ratio; SIH, Symptomatic Intracranial Hemorrhage; mRS: modified Rankin Scale

Figure 1: Distribution of modified Rankin Scale (mRS) scores at third months in patients with and without symptomatic intracranial hemorrhage (SIH)



Keywords: Stroke, Hemorrhagic Transformation, Endovascular Therapy

Financial Disclosures: The authors had no disclosures.

Grant Support: None.

Poster

Comparison of First Pass Efficacy among Four Mechanical Thrombectomy Techniques | A Single Center experience

Muhammad Ubaid Hafeez, Resident¹, Peter Kan, Associate Professor¹, Aditya Srivatsan, Medical Student¹, Shawn Moore, Resident¹, Mostafa Jafari, Resident¹, Carlos DeLaGarza, Resident¹, FNU Komal, Resident¹, Fabio Nascimento, Resident¹, Visish Srinivasan, Resident¹, Stephen Chen, Assistant Professor², Jan-Karl Burkhardt, Assistant Professor¹, Jeremiah Johnson, Assistant Professor¹, Yasir Saleem, Assistant Professor¹

¹Baylor College of Medicine, Houston, Texas, United States of America; ²MD Anderson, Houston, Texas, United States of America

Introduction:

First Pass Efficacy (FPE) is an established marker of technical and clinical efficacy among Mechanical Thrombectomy (MT) techniques. It is unclear what the optimal approach is in achieving FPE. We present a single-center experience comparing rates of FPE between four MT techniques and to evaluate the potential predictors of FPE among other outcomes.

Methods:

A single-center retrospective analysis of consecutive LVOS of anterior circulation from January 2015 to April 2019 who underwent MT. Four MT techniques were identified: A direct First Pass Aspiration (ADAPT), stent retriever with aspiration (SrADAPT), stent retriever with Balloon guide catheter (SRBG) & Stent retriever-aspiration and proximal flow arrest (STRAP). The primary outcome was FPE and secondary outcomes included rate of successful reperfusion, early neurological change (defined as 24-hour National Institute of Health Stroke Scale [NIHSS] minus admission NIHSS), late neurological change (NIHSS at day 7 or discharge minus admission NIHSS). Safety outcomes included symptomatic intracerebral hemorrhage.

Results:

Among 226 cases of LVOS of anterior circulation that underwent MT 164 (72.6%) cases had data on FPE for the 4 MT techniques. SRBG was the most prevalent technique followed by STRAP, SrADAPT and ADAPT. No significant difference was found in rates of FPE among the 4 MT techniques ($p=0.332$). No independent predictors of FPE were identified on multivariable analysis. STRAP had the highest rate of successful reperfusion compared to the other techniques ($p=0.049$). STRAP was the only independent predictor of successful reperfusion on multivariable analysis. ($p=0.027$).

Conclusions:

Among patients with LVOS of the anterior circulation, the rate of FPE did not differ between the 4 MT techniques. There were no predictors of FPE. The use of STRAP was the only predictor of successful reperfusion. Larger prospective and randomized controlled studies are needed to assess the optimal approach for achieving FPE and to ascertain its predictors.

Table: Outcomes and Adverse Events:

	ADAPT n = 22	SRBG n = 57	Sr-ADAPT n = 34	STRAP n = 51	p value
First Pass Efficacy (%)	18.2	29.8	38.2	23.5	0.332
Successful reperfusion (%)	90.9	83.6	70.6	92.0	0.049
Early neurological change **	5.81 ± 6.52	2.71 ± 7.56	4.81 ± 7.32	4.69 ± 8.45	0.544
Late neurological change ***	7.69 ± 7.37	6.4 ± 8.0	6.89 ± 6.97	5.1 ± 8.63	0.662
mRS 0-2 at discharge (%)	9.1	24.6	29.0	20.0	0.340
Symptomatic Intracranial hemorrhage (%)	9.1	7.0	6.1	4.1	.859
Parenchymal hemorrhage (%)	14.3	3.5	6.1	8.3	.394
In hospital mortality (%)	15.8	9.3	8.8	10.2	.863

** Early Neurological Change = Change in NIHSS from baseline at day 1.

*** Late Neurological Change = Change in NIHSS from baseline at day 5 or discharge (whichever comes first).

Keywords: Acute Ischemic Stroke Intervention, Access Catheters, Balloon Guide Catheter, Mechanical Thrombectomy, Stentriever

Financial Disclosures: The authors had no disclosures.

Grant Support: None.

Poster

Impact of Procedural Techniques on Clinical Outcomes in treating LVOs with Endovascular Therapy: ASSIST Registry

Rishi Gupta, MD, MBA, FANA¹, Ansaar Rai, MD², David S Liebeskind, MD³, Antonin Krajina, MD⁴, Marios-Nikos Psychogios, MD⁵, Timo Krings, MD⁶, Woong Yoon, MD⁷, Amrou Sarraj, MD⁸, Osama O Zaidat, MD⁹, Ajit Puri, MD¹⁰, Markus Möhlenbruch, MD¹¹

¹Wellstar Medical Group Neurosurgery Wellstar Health System, Marietta, Georgia, United States of America; ²Department of Neurointerventional Radiology, West Virginia University, Morgantown, West Virginia, United States of America; ³Dept of Neurology and Comprehensive Stroke Center, UCLA, Los Angeles, California, United States of America; ⁴Department of Diagnostic Radiology Simkova Hradec Kralove, Hradec Kralove, Czechia; ⁵University Hospital Basel, CH, Basel, Switzerland; ⁶Toronto Western Hospital, Toronto, Canada; ⁷Department of Radiology Chonnam National University Hospital, Gwangju, Korea (Republic of); ⁸University Texas Health Center, Houston, Texas, United States of America; ⁹Neuroscience Department, Mercy Health St. Vincent Medical Center, Toledo, Ohio, United States of America; ¹⁰University of Massachusetts Medical School, Worcester, Massachusetts, United States of America; ¹¹Uniklinik Heidelberg, Germany, Heidelberg, Germany

Introduction:

Different treatment strategies employed for endovascular thrombectomy (EVT) may impact successful reperfusion and functional outcome. The ASSIST Registry is a post market observational study for continued evaluation of new products per their intended use. The aim of the ASSIST registry is to collect real-world data to develop clinical evidence regarding the use of various techniques of EVT in large vessel occlusions (LVOs). Analysis include evaluating which strategies are associated with first pass reperfusion and better clinical outcomes.

Methods:

Prospective, global, consecutive enrollment registry (up to 1500 subjects) of acute ischemic stroke patients (AIS) with LVO treatment in anterior circulation treated with multiple interventional techniques [Stentriever + Balloon guide catheter (BGC); Stentriever + Aspiration ± BGC; Aspiration ± BGC] using Stryker Neurovascular devices for the first pass. Patients will be distributed in each arm with accommodations made for reducing heterogeneity by geographical and operator location. The data from ASSIST will be analyzed using a generalized linear mixed model which will employ a binary distribution and logit link function to predict mRS. The model will accommodate any categorical and continuous variables that are shown to be confounders by separate univariate analyses, will include a random effect for site, and a four-level variable denoting the technique type.

Results:

A total of 645 patients have been enrolled to date across 48 global centers. Severity of disability (90-day mRS 0-2) and procedural outcome (eTICI 2c or greater on first pass as adjudicated by core lab) will be evaluated for each technique. Secondary clinical outcomes include NIHSS drop of ≥10 points from baseline or NIHSS score of 0 or 1. Safety outcomes include mortality, neurological deterioration, symptomatic intracerebral hemorrhage (ICH) and embolization to a new territory. Baseline, follow-up and angiographic outcomes will be core lab adjudicated.

Conclusions:

There is limited evidence demonstrating clinical benefit or impact on outcomes based on the treatment strategy being employed to treat LVO with EVT. The ASSIST Registry will collect global real-world benchmark data on a large AIS population using the most common techniques and most recently available devices. Study results will provide valuable information on the relative effectiveness of different EVT treatment techniques and aid in the identification of optimal treatment approaches.

Keywords: Acute Ischemic Stroke Intervention, Stent retriever, Access Catheters, Mechanical Thrombectomy, Access Catheters

Financial Disclosures: PI: ASSIST Registry, Stryker, Modest Compensation PI: Tiger Retriever Study, Rapid Medical, Modest Compensation PI: Reclaim trial, Zoll Medical, No compensation; Consultant Cerenovous, Modest Compensation

Grant Support: None.

Poster

Bailout Procedures For Failed Mechanical Thrombectomy In Anterior Circulation Stroke- Retrospective Observational Study

Amit A Bhatti, Dr¹, Vikram Huded, Dr¹, Mudasir Mushtaq, Dr¹, Niranjan Mahajan, Dr¹

¹*Narayana Institute of Neurosciences, Narayana Health City, Bengaluru, India*

Introduction:

Despite the use of currently available tools in various combinations for the treatment of acute ischemic strokes (AIS) due to large vessel occlusion (LVO), mechanical thrombectomy (MT) fails in approximately one third cases to achieve successful recanalization. The strongest predictor of clinical improvement is the extent to which the occluded arterial tree is recanalized. In order to improve recanalization rate, various rescue strategies are used. There have been many retrospective observational studies on rescue/bailout angioplasty and/or stenting for failed MT. We chose to share our experience of bailout procedures for AIS due anterior circulation LVO in a tertiary care centre.

Methods:

This was a retrospective observational analysis of the data obtained from the prospectively maintained institutional stroke registry. Patients who had undergone MT for anterior circulation AIS between October 2010 and January 2020 were enrolled from this database. Patients with posterior circulation stroke, incomplete details or the ones lost to follow up were excluded. Patients were divided into two groups. The first group (MT plus) consisted of patients who had undergone a bailout procedure in addition to the standard MT. The second group (MT only) consisted of those who underwent mechanical thrombectomy only (using stent retriever and/or aspiration). These two groups were compared for various parameters. Functional outcome was assessed at 90 days with the modified Rankin Scale (mRS). Safety evaluation included symptomatic intracranial hemorrhage (sICH), mortality, and intervention-related serious adverse events (SAEs).

Results:

Out of 232 patients who underwent MT between January 2011 and September 2019, 180 patients were included in final analysis. Out of 180 cases, 143 underwent MT while 37 required MT and a rescue procedure. Majority of patients were male in both the groups with patients in MT plus being significantly older (mean age 49 versus 56; P value-0.03). There was statistically more number of patients with intracranial atherosclerotic disease (ICAD), hypertension, diabetes and coronary artery in MT plus group and more number of patients with non-valvular atrial fibrillation and rheumatic heart disease in MT only group. As far as the baseline parameters of median NIHSS (National Institute of Health Stroke scale) at presentation, ASPECTS (Alberta Stroke program early CT score) on imaging, mean time of onset, intravenous thrombolytics are concerned; the groups were similar. There was no difference on the primary outcome at the end of three months as per the modified Rankin Scale with 58% and 59.5% patients achieving mRS 0-2 in MT only and MT plus group respectively. Also, there was no significant difference in the rate of complications including sICH between the two groups.

Conclusions:

In carefully selected patients, bailout stenting and/or angioplasty after a failed MT is a feasible and effective recanalization method for AIS stroke with good functional outcome and is associated especially with low rates of sICH.

Keywords: Acute Ischemic Stroke Intervention, Intra Caranial Stenosis, Intracranial Stenosis Stenting And Angioplasty, Angioplasty, Carotid Stenting And Angioplasty

Financial Disclosures: The authors had no disclosures.

Grant Support: None.

Poster

Predictors Of Functional Outcome In Post-Mechanical Thrombectomy Patients

Carlos De la Garza, MD¹, Ameer E Hassan, DO¹, Gabriel Torrealba, MD¹, Mostafa Jafari, MD¹, Aaron Desai, MD¹, Alexander Sellers, MD¹, Hayden Hall, DO¹, Shawn Moore, MD¹, Mohammad Hirzallah, MD¹, Eric Bershad, MD¹, Chethan P Rao, MD¹, Rahul Damani, MD¹

¹Baylor College of Medicine, Houston, Texas, United States of America; ²Valley Baptist Medical Center, UTRGV, Harlingen, Texas, United States of America

Introduction:

Patients with acute ischemic stroke with large vessel occlusion benefit from mechanical thrombectomy (MT).. The aim of this study is to identify potential variables as predictors of patients' functional outcome and complications.

Methods:

A retrospective review of consecutive patients admitted to the neurocritical care unit at a Baylor St. Luke's Medical Center in Houston, TX was performed. Data was collected and analyzed, pertaining to post-MT patients; spanning the time period between January 2015 and April 2019. We collected demographic information along with baseline and 24-hour post-MT NIHSS, vital signs, laboratory and radiological data. Neutrophil-lymphocyte (NLR) and platelet-lymphocyte (PLR) ratios were calculated. Data for continuous variables is presented as means and medians according to their normality distribution, and percentages for categorical variables. We compared means and medians with t-student and Wilcoxon-Mann-Whitney tests, respectively; as well as Fisher exact test for the comparison of proportions. Functional outcome, as indexed by 90-day mRS was modeled through uni and multivariate logistic regression, significance was set at p value < 0.05

Results:

A total of 176 acute ischemic stroke patients underwent mechanical thrombectomy (MT) (52.27% male, mean age 65.63 ± 14.89 years, and median baseline NIHSS of 16 (IQR 12-20)). Outcomes were dichotomized as poor (90-day mRS \geq 3) or good (90-day mRS<3) . Patients with poor outcome were significantly older (68.69 ± 14.10 vs 59.85 ± 14.73 , $p=0.001$), had higher baseline (17 (IQR 14-22) vs 14 (IQR 9-18), $p=0.0016$), 24-hour post MT (17 (IQR 13-22) vs 5 (IQR 2-8), $p=0.000$) and discharge (15 (IQR 9-20) vs 2 (IQR 1-5), $p=0.000$) NIHSS, a greater proportion of patients needing antihypertensives within 24 hours post MT (77.33% vs 22.67%, $p=0.003$), a higher incidence of acute kidney injury (AKI) (89.74% vs 10.26%, $p=0.000$) as well as higher values of baseline PLR (17.87 ± 15.47 vs 12.98 ± 13.12 , $p=0.0375$) and NLR (6.45 ± 5.13 vs 4.26 ± 4.35 , $p=0.0052$) in addition to 24-h post MT PLR (28.67 ± 38.47 vs 15.97 ± 17.18 , $p=0.0189$) and NLR (11.56 ± 15.18 vs 5.58 ± 4.98 , $p=0.0044$). Multivariate analysis adjusted for sex and baseline NIHSS, established age (OR 1.09, 95% CI: 1.03-1.15), discharge NIHSS (OR 1.53, 95% CI: 1.30-1.80) and need for antihypertensive in 24-h post MT (OR 5.70, 95% CI 1.58-20.62) as independent significant predictors of poor functional outcomes at 3-months follow up.

Conclusions:

Patients with poor outcome (90-day mRS => 3), were significantly older, had higher baseline/24h and discharge NIHSS, more frequently required antihypertensives post MT, had greater incidence of AKI and higher values of baseline and 24-h PLR and NLR. Uni and multivariate analysis confirmed these factors as independent predictors of poor outcome at 90 day follow up.

Keywords: Acute Stroke, Mechanical Thrombectomy, Door To Needle, Interventional Neuroradiology, Acute Ischemic Stroke Intervention

Financial Disclosures: The authors had no disclosures.

Grant Support: None.

Poster

Cell Count Ratios As Outcome Predictors In Acute Ischemic Stroke Patients Treated With Mechanical Thrombectomy

Carlos De la Garza, MD¹, Ameer E Hassan, DO², Gabriel Torrealba, MD¹, Shawn Moore, MD¹, Hayden Hall, DO¹, Alexander Sellers, MD¹, Aaron Desai, MD¹, Mostafa Jafari, MD¹, Mohammad Hirzallah, MD¹, Eric Bershad, MD¹, Chethan P Rao, MD¹, Rahul Damani, MD¹

¹Baylor College of Medicine, Houston, Texas, United States of America; ²Valley Baptist Medical Center, UTRGV, Harlingen, Texas, United States of America

Introduction:

In acute ischemic stroke, inflammatory mediators account for local and systemic changes that determine outcomes. Neuroinflammation may be a potential marker in the selection of intervention. Platelet-to-Lymphocyte ratio (PLR), Neutrophil-to-Lymphocyte ratio (NLR) and Lymphocyte-to-Monocyte ratio (LMR) are suggested as indicators of inflammation and independent predictors of outcome in stroke patients after mechanical thrombectomy (MT).

Methods:

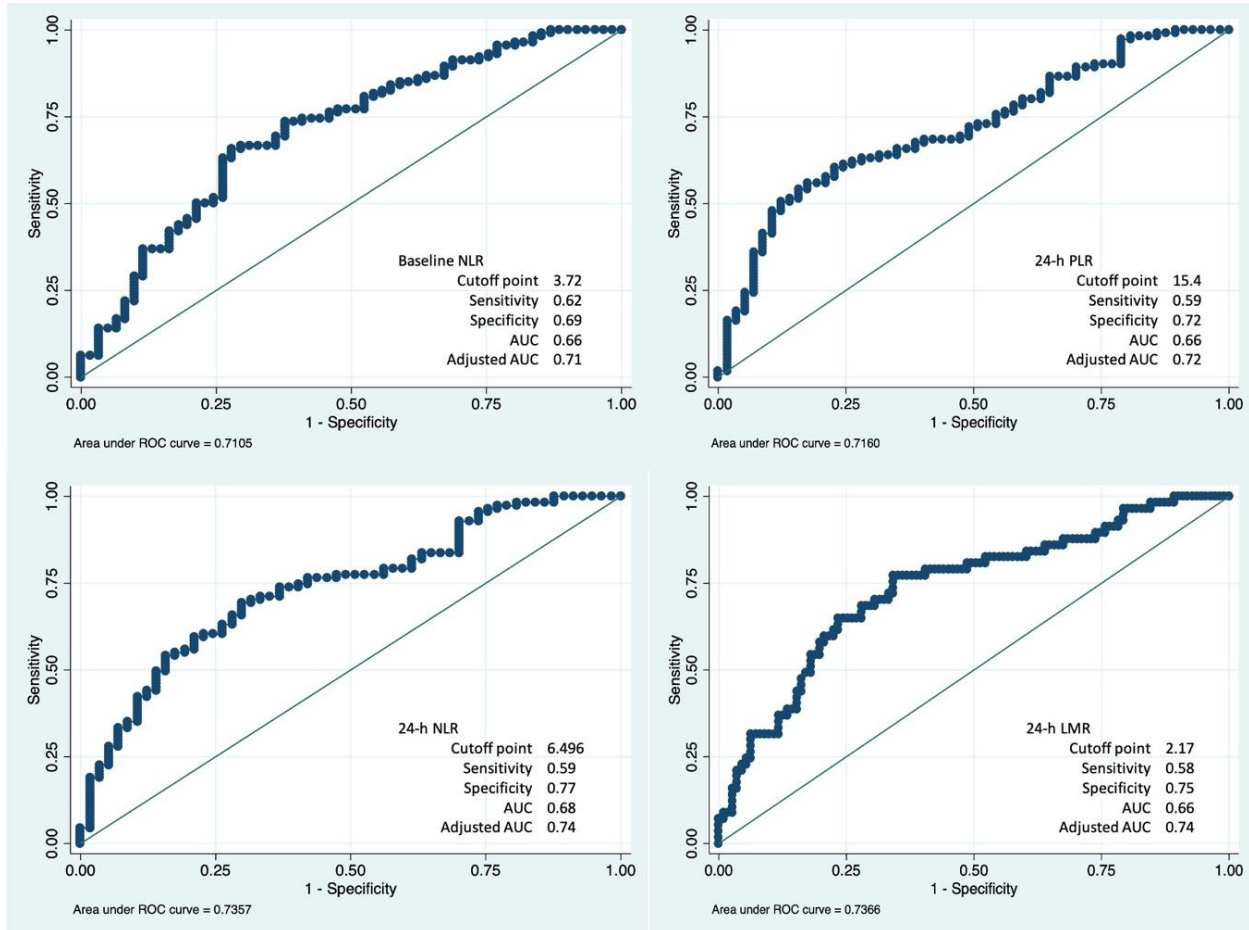
Retrospective review of consecutive patients that underwent MT at Baylor St. Luke's Medical Center in Houston, TX. Data from the January 2015-April 2019 period was analyzed. Demographics, laboratory, radiological and functional outcomes (90-day mRS) were collected. Receiver operating characteristics (ROC) analysis were performed to determine the area under the curve (AUC), sensitivity and specificity of baseline and 24h postMT NLR, PLR and LMR as predictors of functional outcome. Youden Index was utilized to identify best cutoff points for each marker. Adjusted Cox-proportional hazard survival analysis and multivariate logistic regression modeling was also utilized for prediction.

Results:

176 stroke patients underwent mechanical thrombectomy (MT) (52.27% male, mean age 65.63 ± 14.89 years, median baseline NIHSS of 16 (IQR 12-20)). Outcomes were dichotomized as poor (90-day mRS \geq 3) or good (90-day mRS $<$ 3). Patients with poor outcome had higher baseline PLR (17.87 ± 15.47 vs 12.98 ± 13.12 , $p=0.0375$) and NLR (6.45 ± 5.13 vs 4.26 ± 4.35 , $p=0.0052$) in addition to higher 24h postMT PLR (28.67 ± 38.47 vs 15.97 ± 17.18 , $p=0.0189$) and NLR (11.56 ± 15.18 vs 5.58 ± 4.98 , $p=0.0044$), and lower 24h LMR (1.73 ± 0.92 vs 3.49 ± 7.57 , $p=0.0168$). Baseline PRL (61% sensitivity and 67% specificity, cutoff point of 9.72) baseline NLR (62% sensitivity and 69% specificity, cutoff point of 3.72) as well as 24-h PLR (59% sensitivity, 72% specificity, cutoff point of 15.4), 24h NLR (59% sensitivity and 77% specificity, cutoff 6.50) and 24h LMR (58% sensitivity and 75% specificity, cutoff 2.17); all with adjusted $AUC \leq 0.74$, were established as predictors of functional outcome only in the univariate analysis. Correlations lost significance when adjusted by sex, age and baseline NIHSS. Cox-proportional hazards regression analysis controlled by sex, age and baseline NIHSS suggested cutoff points of baseline NLR (HR 1.94, 95% CI: 1.0-3.77, $p=0.051$) and 24h LMR (HR 1.88; 95% CI: 0.94-3.74, $p=0.073$) as non-significant predictors of survival.

Conclusions:

Baseline PRL, NLR and 24-h PLR, NLR and LMR were predictors of functional outcomes in univariate analysis. Adjusted ROC curve analysis reported sensitivities and specificities from 59-62% and 67-77% for outcome prediction, with $AUC \leq 0.74$. Baseline NLR and 24h LMR cutoff points showed a non-significant association with 90-day survival after controlling by age, sex and baseline NIHSS



Keywords: Acute Ischemic Stroke Intervention, Acute Stroke, Mechanical Thrombectomy, Acute Stroke, Ischemic Stroke

Financial Disclosures: The authors had no disclosures.

Grant Support: None.

Poster

Clinical Description Of Post-Mechanical Thrombectomy Patients, Treated at a Comprehensive Stroke Center

Carlos De la Garza, MD¹, Gabriel Torrealba, MD¹, Ameer E Hassan, DO², Shawn Moore, MD¹, Hayden Hall, DO¹, Mostafa Jafari, MD¹, Alexander Sellers, MD¹, Aaron Desai, MD¹, Mohammad Hirzallah, MD¹, Eric Bershada, MD¹, Rahul Damani, MD¹, Chethan P Rao, MD¹

¹Baylor College of Medicine, Houston, Texas, United States of America; ²Valley Baptist Medical Center, UTRGV, Harlingen, Texas, United States of America

Introduction:

Mechanical thrombectomy (MT) has become the treatment of choice for acute ischemic stroke with large vessel occlusion (LVO). The goal of the study is to develop a database of post-MT patients' and will include demographics, clinical, laboratory and radiological characteristics as well as procedure specifications and outcomes. This database will allow us to understand patient profiles, analyze procedural performance and aid in future study design and the eventual development of outcome prediction scores.

Methods:

Retrospective data from consecutive ischemic stroke MT treated patients from January 2015 to April 2019 at Baylor St. Luke's Medical Center in Houston, TX. Demographic, clinical and imaging variables were recorded. Procedure aspects along with patient functional outcomes, as indexed by the modified Rankin score (mRS, poor functional outcome=3-6), were analyzed. Data for continuous variables is presented as means and medians according to their normality distribution, and percentages for categorical variables.

Results:

A total of 176 acute ischemic stroke patients that underwent mechanical thrombectomy (MT) (52.27% male, average age 65.63 ± 14.89 years, and median baseline NIHSS of 16 (IQR 12-20)). Most common site occluded was M1/M2 (72.16%) followed by ICA/MCA (10.80%) and intracranial-ICA (7.9%). Basilar and PCA occlusions accounted for 7.95% of the cases. Major risk factors were hypertension (78.29%), smoking (39.77%), hyperlipidemia (37.71%) and diabetes mellitus DM (30.86%). 65 (36.9%) patients were on antiplatelets and 26 (14.8%) had anticoagulation therapy. The majority of procedures used retrievable stents (51.72%). Median time from stroke onset to recanalization was 5 h (IQR 3.53-7) and 3 h (IQR 2-4) for door to recanalization time, with a median number of 2 (IQR 1-2) passes to recanalization. 107 (60.80%) patients received IV- tPA prior to thrombectomy and 75 (42.61%) required antihypertensives in the first 24 hours post procedure. 49.43% achieved TIC13 and 32.39% TIC12B; 61 (34.65%) patients reported good functional outcome (mRS<3) at 90-day follow up.

Conclusions:

Our description of patients with MT is consistent with prior literature reports. Majority of patients achieved complete to almost complete reperfusion and more than a third of patients presented good functional outcome (mRS<3) at 90-day follow up.

Keywords: Mechanical Thrombectomy, Interventional Neuroradiology, Stent retriever, Door To Needle, Acute Ischemic Stroke Intervention

Financial Disclosures: The authors had no disclosures.

Grant Support: None.

Poster

The Use of Intravenous Milrinone for Treatment of Cerebral Vasospasm Due to Non-aneurysmal Subarachnoid Hemorrhage

Christine Hawkes, MD, FRCPC¹, Michelle Kameda-Smith, MD, PhD¹, Aviraj Deshmukh, MD¹, Melissa Lannon, MD¹, Almunder Algird, MD, FRCSC¹, Bill Wang, MD, MSc, FRCSC¹, Brian van Adel, MD, PhD, FRCPC¹

¹McMaster University, Hamilton, Canada

Introduction:

After direct mortality from an aneurysmal subarachnoid hemorrhage (aSAH), delayed cerebral ischemia (DCI) secondary to cerebral vasospasm is a cause of severe morbidity and mortality. Non-aneurysmal SAH, specifically perimesencephalic distribution of SAH has been described as an entity typically associated with a more benign clinical course. Non-aneurysmal diffuse SAH however has been observed to have a more tenuous outcome and therefore requires close clinical observation as this subset of patients has a similar likelihood for developing DCI as patients with diffuse aSAH. Several recent publications have demonstrated promising results with using intravenous (IV) milrinone to treat cerebral vasospasm. Here we audit the application of the use of IV Milrinone in the clinical management of vasospasm and DCI in an adult non-aneurysmal SAH population.

Methods:

A retrospective quality audit was conducted at a single neurosurgical center over a 1-year period (i.e., 2019). The study was approved by the local university ethics committee. Data was extracted from electronic medical records (Meditech and Sovera) and the Picture Archives and Communication Systems (PACS). Statistical analysis was completed in SPSS (www.ibm.com).

Results:

A total of 93 adult patients were admitted for management of SAH. Twenty-five patients presented with non-aneurysmal SAH. These patients were similar age to the aSAH but with a predilection for male gender, lower clinoradiological grade (i.e., WFNS, HH, Fisher scores), lower initial lymphocyte and platelet counts. Four patients in this group required symptomatic DCI management. All 4 patients presented with a diffuse pattern of SAH with hydrocephalus requiring external ventricular drain (EVD) insertion in 2 patients. All but 2 patients in the non-aneurysmal SAH group at last follow up had an mRS of 0-2. Of the 2 patients with poor clinical outcome (i.e., mRS 3-4) presented with poorer clinoradiological grade with 1 requiring an EVD for hydrocephalus. Intravenous milrinone was commenced for reduced level of consciousness (LOC) in 2/4 patient with focal neurological deficit prompting initiation of IV therapy in the remaining 2 patients. No bolus was provided for any patient and with a starting dose of 0.25 and maximal dose ranging from 0.25-1.0 mcg/kg/min. Subsequent intraarterial vasodilatory therapy was provided in 2. There was a trend for patients receiving higher maximal doses of milrinone to have better neurological outcome.

Conclusions:

Variability in practice exists among clinicians treating symptomatic DCI prompting an audit of local practice at a large Neurosurgical center. Patients with diffuse non-aneurysmal SAH can develop

symptomatic DCI and should be adequately monitored and provided a standardized protocol for cerebral vasodilatory therapy. The role of an IV milrinone bolus and maximal doses of infusion therapy remains controversial and its rationale should be studied in the context of a large randomized control trial.

Keywords: Subarachnoid Hemorrhage, Vasospasm Intervention, Vasodilator, Ischemic And Hemorrhagic Stroke, Endovascular Therapy

Financial Disclosures: The authors had no disclosures.

Grant Support: None.

Poster

Identification of segmental vulnerability and anomalies in cerebral arteries and their association with cerebral aneurysms

Saima Ahmad, Neuroradiologist¹

¹Lahore General Hospital, Lahore, Pakistan

Introduction:

Clinical experience shows that certain diseases involve specific areas of the vascular tree and remarkably spare others. Topographic differences in the vascular environment already suggest a regional specificity of the vascular anatomy. The biological grounds of such regional differences, we call this property segmental identity and thus vulnerability. Most of this identity is established during development and is preserved throughout life; its expression, however, may vary over time according to various stresses and create various clinical phenotypes. Similar observations can be made for some unusual, nongenetical arterial lesions. Serpentine arterial aneurysm, arterial dysplasia, basilar artery dysplasia, Moya-Moya disease, dolichoarterial segments, rete mirabile, immune arterial lesions may all represent diseases demonstrating this segmental vulnerability and timing. The aim of this study was to identify the underlying cause of vascular anomalies and variations and to assess their relationship with aneurysm formation.

Methods:

A retrospective angiographical review was performed on 200 patients with intracranial aneurysms seen from 2018 to September 2020. Patients were assessed for the location of the aneurysm and co-incident vascular variations and/or anomalies. There were two observers in the study, both of them were experienced interventional neuroradiologists with 7 and 20 years experience.

Results:

The most common were: fenestrations of basilar artery, asymmetric caudal basilar fusion, extradural origin of the PICA, dorsal ophthalmic artery, accessory middle cerebral artery, persistent trigeminal artery, dolichoectasia of basilar artery and Moya–Moya Disease. These aneurysm locations bled proportionally more frequently when associated with the related vascular anomaly.

Conclusions:

Due to an increased hemodynamic stress, congenital anomalies of the intracranial arteries predispose to the formation of saccular aneurysms. These anomalies are detected more frequently in patients with cerebral aneurysms compared to the normal population. We need to investigate more on identification of segmental identity and vascular anomalies at larger population sample to rule out the cause of rupture in associated aneurysms.

Keywords: Angiogram, Aneurysm, Clinical Investigations, Collateral, Carotid

Financial Disclosures: The authors had no disclosures.

Grant Support: None.

Poster

Increased Contrast Enhancement of the Parent Vessel of Unruptured Intracranial Aneurysms in 7T MR Imaging

Alberto Varon, MD¹, Edgar A Samaniego, MD, MS¹, Jorge A Roa, MD¹, Ryan Sabotin, MS2¹, Ashrita Raghuram, BSE¹, Honghai Zhang, PhD¹, Timothy R Kosciak, PhD¹, Santiago Ortega-Gutierrez, MD, MSc¹, Girish Bathla, MD¹, Milan Sonka, PhD¹, Colin P Derdeyn, MD¹, Vincent Magnotta, PhD¹, David M Hasan, MD¹

¹University of Iowa, Iowa City, Iowa, United States of America

Introduction:

Inflammation of the arterial wall may lead to aneurysm formation. The presence of aneurysm enhancement on high-resolution vessel wall imaging (HR-VWI) is a marker of wall inflammation and instability. We aim to determine if there is any association between increased contrast enhancement in the aneurysmal wall and its parent artery.

Methods:

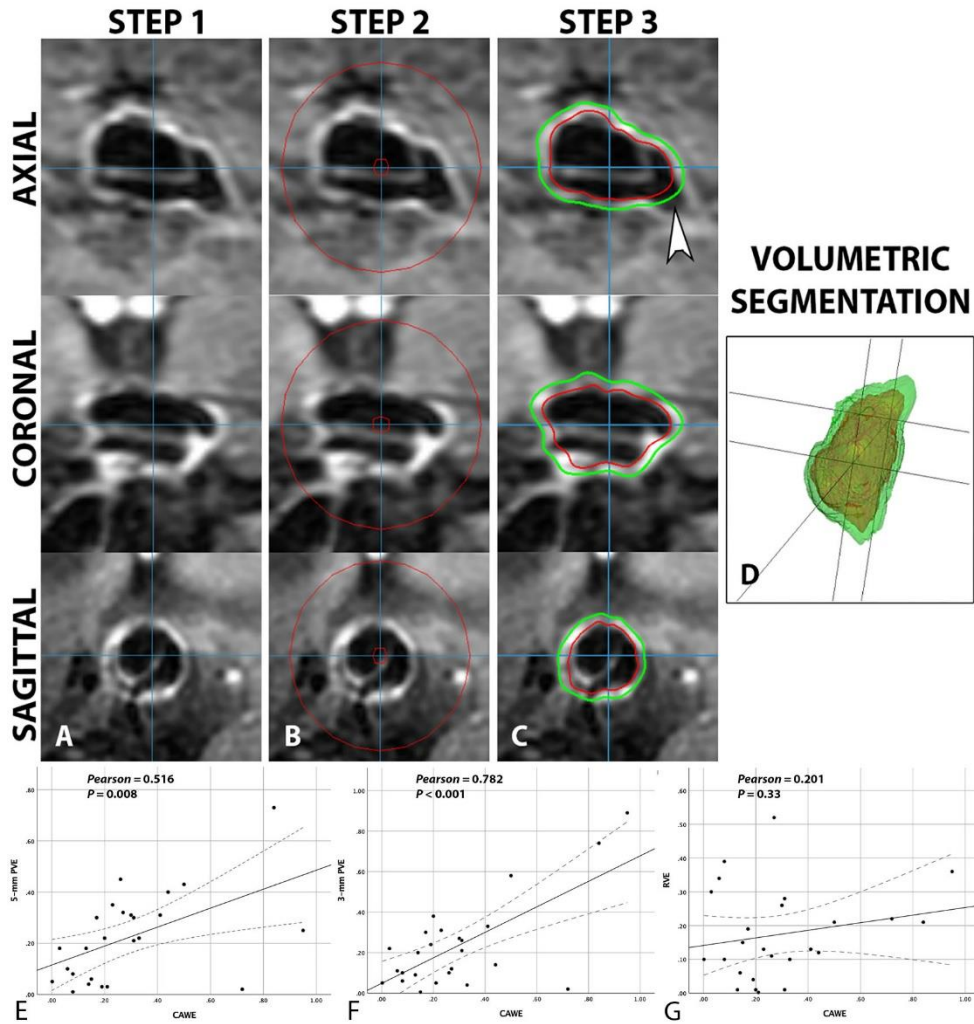
Patients with unruptured intracranial aneurysms (UIAs) prospectively underwent 7T HR-VWI. Regions of interest were selected manually and with a semi-automated protocol based on gradient algorithms of intensity patterns. Mean signal intensities in pre- and post-contrast T1-weighted sequences were adjusted to the enhancement of the pituitary stalk and then subtracted to objectively determine: circumferential aneurysmal wall enhancement (CAWE); parent vessel enhancement (PVE); and reference vessel enhancement (RVE). PVE was assessed over regions located 3- and 5 mm from the aneurysm's neck. RVE was assessed in arteries located in a different vascular territory.

Results:

Twenty-five UIAs were analyzed. There was a significant moderate correlation between CAWE and 5 mm PVE (Pearson $R=0.52$, $P=0.008$), whereas no correlation was found between CAWE and RVE (Pearson $R=0.20$, $P=0.33$). A stronger correlation was found between CAWE and 3 mm PVE (Pearson $R=0.78$, $P<0.001$). Intra-class correlation analysis demonstrated good reliability between measurements obtained using semi-automated and manual segmentation (ICC coefficient= 0.790 , 95% CI 0.58 to 0.90).

Conclusions:

Parent arteries exhibit higher contrast enhancement in regions closer to the aneurysm's neck, especially in aneurysms ≥ 7 mm. A localized inflammatory/vasculopathic process in the wall of the parent artery may lead to aneurysm formation and growth.



Keywords: Intracerebral Aneurysm, Vascular Imaging, Inflammation,

Financial Disclosures: The authors had no disclosures.

Grant Support: This work was supported by the 2019 Brain Aneurysm Research Grant from The Bee Foundation and by a Pilot Research Grant from the Society of Vascular and Interventional Neurology (SVIN), both granted to Edgar Samaniego. This work was conducted on an MRI instrument funded by 1S10RR028821-01.

Poster

Abdominal Obesity and Rupture Risk of Intracranial Aneurysms – a Case-Control Study.

Katja Loevik, Medical student¹, Johnny Laupsa-Borge, PhD Candidate¹, Nicola Logallo, MD PhD¹, Christian A Helland, Prof. MD PhD¹

¹University of Bergen, Bergen, Norway

Introduction:

A rupture of an intracranial aneurysm resulting in a subarachnoid hemorrhage (SAH) is a life-threatening situation accounting for 5% of the deaths from stroke, and as much as 27% of all stroke-related years of life lost before the age of 65 [1]. Obesity is an increasing health challenge associated with numerous comorbidities, including cardiovascular disease, diabetes and cancer. However, recent studies have shown a surprising decreased risk of SAH with increasing body mass index (BMI) [2]. Associations between other obesity variables (body composition) and the rupture risk of an intracranial aneurysm have to our knowledge not yet been explored.

Methods:

Using a bio impedance device, InBody S10, we performed body composition analyses on 31 patients (17 females and 14 males) admitted with acute SAH and 28 patients (22 females and 6 males) with planned intervention on their unruptured intracranial aneurysm (UIA). We also collected information on comorbidities and relevant risk factors, such as hypertension, smoking, and statin use. Logistic regression was used to explore associations between anthropometric variables and patients with ruptured versus unruptured aneurysms.

Results:

Unadjusted estimates showed a significant inverse relationship between body fat percent and aneurysmal rupture, with each one-unit increase in body fat percent associated with an approximate 8% reduction in rupture risk (odds ratio, OR [95% CI]: 0.92 [0.86, 0.97]; P= 0.009). This relationship remained significant after adjusting for age and sex (OR [95% CI]: 0.93 [0.87, 0.99]; P= 0.028). We also found an inverse, but non-significant association between BMI and rupture risk (adjusted OR [95% CI]: 0.92 [0.83, 1.02]; P= 0.132). Measures of abdominal obesity (waist circumference and visceral fat area) showed no relationship with the risk of aneurysmal rupture.

Conclusions:

In recent studies showing a paradoxical relation between SAH and obesity [2], BMI was the only parameter investigated. We further explored this “obesity paradox” by measuring the body composition in 59 patients with intracranial aneurysms and found that rupture risk was inversely associated with body fat percent, but not with measures of abdominal obesity. Future studies should investigate these relationships in larger samples and explore sex-dependent differences.

Keywords: Aneurysm, Subarachnoid Hemorrhage, Clinical Trial, Ruptured, SAH

Financial Disclosures: The authors had no disclosures.

Grant Support: None.

Poster

A Multi-Omics Approach to the Discovery of Biomarkers for Intracranial Aneurysm Growth

Christina P Rossitto, BS¹, Carina Seah, BS¹, Dominic Nistal, MD¹, Kurt A Yaeger, MD¹, J Mocco, MD MS¹, Christopher P Kellner, MD¹

¹Icahn School of Medicine at Mount Sinai, New York, New York, United States of America

Introduction:

Intracranial aneurysm (IA) is a cerebrovascular disorder that when ruptured can cause devastating subarachnoid hemorrhage. The purpose of this study was to utilize multi-omics data to identify differential expression of monocyte RNA and protein in patients with IA. Analytes that correlate with IA size have the potential to be used as a blood-based test to monitor IA presence and growth in patients. Our approach illustrates the power of multi-omics analysis in IA biomarker discovery.

Methods:

Patients were identified through the hospital's cerebrovascular center. Clinical data was gathered through interview at the time of consent. IA characteristics and blood samples were obtained through cerebral angiography. Sequencing was performed at a read depth of 40 million 150-base pair paired-end reads using Illumina HiSeq 4000 platform. Sequences were pseudo-aligned using Kallisto. Plasma protein levels were assessed through the Olink Inflammatory Panel. To analyze monocyte RNA expression, the patient samples were divided into large aneurysm (diameter ≥ 7 mm) and small aneurysm (< 7 mm) cohorts and differentially expressed genes were identified using edgeR and Glimma in R version 1.3.9. The differential expression of each gene transcript between size cohorts were identified. The top 20 differentially expressed transcripts and clinical characteristics underwent linear regression to evaluate ability to predict aneurysm size. To analyze protein expression, the top 70 expressed proteins underwent linear regression to predict aneurysm size.

Results:

Of the 8 patients with IA, 87.5% (n=7) were female, with a mean aneurysm size of 7.8 mm. 4 patients (50%) had aneurysms ≥ 7 mm. Expression analysis revealed 20 genes that were differentially expressed between the large and small aneurysm cohorts. Linear regression of monocyte RNA revealed 4 transcripts that were predictive of aneurysm size at a significance threshold of $P < 0.05$: HIST2H4A ($P = 0.0122$), CAMK2D ($P=0.0267$), WARS1 ($P=0.0378$), ANXA1 ($P=0.0418$). Linear regression of protein expression revealed 7 proteins that were predictive of aneurysm size at a significance threshold of $P < 0.05$: Beta-NGF ($P=0.0318$), CASP-8 ($P=0.0382$), CXCL6 ($P=0.039$), CCL28 ($P=0.0447$), TNFRSF9 ($P=0.0443$), CXCL11 ($P=0.0461$), MCP-2 ($P=0.0465$). Clinical characteristics and multiple linear regression models were not significantly predictive.

Conclusions:

Multi-omics analysis is a promising tool to understand the integrated mechanisms of IA development. Given the inflammatory processes in IA formation, we utilized monocyte RNA and whole blood proteins to identify differential expression in IA patients. In this small pilot study, we were able to identify potential biomarkers for IA growth. The adoption of this protocol at a larger scale may have a direct impact on precision medicine and the discovery of biomarkers for IA.

Keywords: Intracerebral Aneurysm, Basic/Translational Vascular Science, Neuromonitoring, New Innovation, Subarachnoid Hemorrhage

Financial Disclosures: The authors had no disclosures.

Grant Support: The Bee Foundation, The Brain Aneurysm Foundation

Poster

Gender differences in Risk Factors from a Cohort of Stroke patients with Obstructive Sleep Apnea

Camron K Edrissi, Presenter¹, Nicolas Poupore, co-author¹, Chase Rathford, co-author¹, Krista Knisely, co-author¹, Carolyn Sanders, co-author¹, Thomas Nathaniel PhD, Principal investigator¹

¹*University of South Carolina School of Medicine Greenville, Greenville, South Carolina, United States of America*

Introduction:

Obstructive Sleep Apnea (OSA) is a common condition that occurs when the muscles surrounding the oropharyngeal cavity relax and cause a decrease in oxygen intake during sleep. Continuous, chronic obstruction of the airway during sleep may lead to an increase in risk for stroke related co-morbidities. Our team sought to determine the gender differences between demographic and clinical risk factors stratifying for OSA.

Methods:

We used data from the ischemic stroke registry in a total population of 5,469 patients who arrived at Prisma Health Upstate hospital with an Acute Ischemic Stroke where 2,662 were male and 2,807 were female. We determined the sub population of patients with OSA that arrived at the hospital with an Acute Ischemic Stroke. 101 were male and 69 were female. A logistic regression model was used and an odds ratio (OR) was calculated to determine what factors were most or least likely to be associated with a patient's gender along dependent on the co-morbidity of OSA.

Results:

In the group with OSA who had an acute ischemic stroke, females had a larger NIHSS score (OR = 1.058, 95% CI, 0.994-1.13, P=0.078), HDL level (OR = 1.125, 95% CI, 1.067-1.19, P<0.001), lipid level (OR = 1.243, 95% CI, 0.999-1.55, P=0.051), BMI (OR = 1.103, 95% CI, 1.036-1.18, P=0.002), depression incidence (OR = 3.804, 95% CI, 1.369-10.6, P=0.01), family history of stroke incidence (OR = 3.442, 95% CI, 0.891-13.3, P=0.023), PVD incidence (OR = 4.892, 95% CI, 1.248-19.2, P=0.076), but lower systolic blood pressure (OR = 0.984, 95% CI, 0.968-1, P=0.066), and ambulatory improvement (OR = 0.406, 95% CI, 0.15-1.1, P=0.076).

Conclusions:

In the group with a previous diagnosis of OSA, females were shown to have an increased risk for a more severe stroke per the NIHSS score and a lower improvement in ambulation. Females also had a higher BMI, lipid levels, incidence of depression, and incidence of PVD. We determined that this study gives insight into the different co-morbidities that will help create a gender tailored treatment plan for the prevention and treatment of strokes.

Keywords: Stroke

Financial Disclosures: The authors had no disclosures.

Grant Support: None.

Poster

Human plasma proteomics for biomarker discovery for ischemic stroke and TIA

Supriya Ramesha, MD¹, Michael Liu, MD², Michael Frankel, MD³, Srikant Rangaraju, MD²

¹West Virginia University, Morgantown, West Virginia, United States of America; ²Emory University, Atlanta, Georgia, United States of America; ³Emory University and Grady Hospital, Atlanta, Georgia, United States of America

Introduction:

Previous studies have shown that the proteomic analysis of plasma proteins is a reliable tool to identify blood-based biomarkers in acute stroke cases (Penn AM *et al*, *Translational Stroke Research*, 2018; Qin C *et al*, *Journal of Translational Medicine*, 2019). However, TIA can often be difficult to distinguish from stroke mimics especially in the emergent setting. Blood-based biomarkers to distinguish these diagnostic groups could be immensely useful in the acute management of stroke.

We hypothesized that mass spectrometry proteomic profiling of plasma proteins collected in the acute setting from patients with acute ischemic stroke, transient ischemic attack (TIA) and stroke mimics is a feasible strategy to differentiate these diagnostic groups.

Methods:

Blood was drawn acutely upon patient's presentation in the ER and plasma samples were stored at -80C until further processing. 29 age and sex-matched samples (7 TIA, 10 ischemic stroke and 12 stroke mimics) were selected randomly in this pilot feasibility study. Top-14 most abundant (e.g. albumin, globulins) proteins were depleted to allow measurement of less abundant proteins. Pre- and post-depletion measurements were performed to confirm adequate and equal depletion. Proteins were digested with LysC and trypsin enzymes and processed for label-free quantitation mass spectrometry (LFQ-MS). Data were analyzed by differential expression and principal component analysis (PCA) approaches.

Results:

Age (range 61-16 years), sex and comorbidities were equally balanced across groups and mean NIHSS at presentation were similar (4, 7 and 6 for TIA, AIS and mimics respectively, $p=0.77$) LFQ-MS of plasma samples identified 400 proteins of which 279 had <50% missing values across samples and were included for analysis. 51 proteins were differentially expressed across groups and PCA identified 3 PCs that explained 47.5% of the variance in the data (PC1:23.3 % PC2:14.9% PC3: 9.3%). PC1 differentiated TIA from mimics while PC2 differentiated stroke from TIAs and mimics. Higher levels of fibrinogen and complement activation differentiated TIA from mimics while higher levels of acute-phase reactants (CRP, SAA1) differentiated TIA from ischemic stroke. Plasma proteins with highest levels in stroke mimics were also identified (SPATS2L, SERPINA3 and ATRN).

Conclusions:

We establish the feasibility of proteomic analysis of plasma as an approach to identify novel stroke and TIA biomarkers. Ongoing validation studies may facilitate the development of panels of biomarkers to differentiate TIA from stroke mimics in the emergency room setting. This approach has potential for extension to the study of large vessel occlusion stroke and cryptogenic stroke as well.

Keywords: Acute Stroke, TIA, New Innovation

Financial Disclosures: The authors had no disclosures.

Grant Support: None.

Poster

Risk Factors Contributing to Gender Differences in AIS Patients with a history of Atrial Fibrillation

Chase A Rathfoot, Presenter, Author¹, Camron Edrissi, Co-Author¹, Carolyn B Sanders, Co-Author¹, Krista Knisely, Co-Author¹, Thomas I Nathaniel, PI¹

¹*University of South Carolina School of Medicine - Greenville, Greenville, South Carolina, United States of America*

Introduction:

Within the neuroscience community, it has been well established that female Acute Ischemic Stroke (AIS) patients have increased morbidity and mortality. It has been similarly established that men are diagnosed more frequently and earlier with Atrial Fibrillation. However, there is a lack of statistical evidence concerning the gender differences of AIS patients with a past medical history of Atrial Fibrillation. In this study, demographic and clinical factors were analyzed to determine which factors were associated with being male or female in patients having both a history of Atrial Fibrillation and Ischemic Stroke.

Methods:

Previously collected data in an ischemic stroke registry was analyzed using IBM's SPSS software. In a population of 5,469 AIS patients, 921 were identified as having a past medical history of Atrial Fibrillation. This group was subdivided by gender for analysis, with 381 male and 542 female patients being assessed for demographic factors such as age, race, or BMI as well as clinical factors such as depression and sleep apnea. Logarithmic Regression was used to determine the Odds Ratio (OR) that these risk factors would be associated with the female gender.

Results:

In the population of patients with Atrial Fibrillation, a history of Drug and Alcohol Use (OR = 0.250, 95% CI, 0.497-1.006, P = 0.016), Sleep Apnea (OR = 0.321, 95% CI, 0.133-0.777, P = 0.012), HDL (OR = 1.035, 95% CI, 1.020-1.050, P < 0.001), LDL (OR = 1.006, 95% CI, 1.001-1.011, P = 0.012), Serum Creatinine (OR = 0.693, 95% CI, 0.542-0.886 P = 0.003), and the Inability to Ambulate on Admission to hospital (OR = 2.258, 95% CI, 1.368-3.727, P = 0.001) were found to be significantly associated with female AIS patients with a history of Atrial Fibrillation.

Conclusions:

As a result of this study, several clinical and demographic factors were identified as being associated with female AIS patients with a history of Atrial Fibrillation. By identifying the risk factors that may contribute to gender differences in Acute Ischemic Stroke patients, improved risk assessments and management strategies might be developed for the care of patients with a history of Atrial Fibrillation.

Keywords: Stroke, Ischemic Stroke

Financial Disclosures: The authors had no disclosures.

Grant Support: None.

Poster

Obstructive Sleep Apnea and Stroke Severity: Impact of Clinical Risk Factors

Carolyn B Sanders, Medical Student¹, Krista Knisely, Medical Student¹, Camron Edrissi, Medical Student¹, Chase Rathfoot, Medical Student¹, Nicolas Poupore, Medical Student¹, Leah Wormack, Medical Student¹, Thomas I Nathaniel, Principal Investigator¹

¹*University of South Carolina School of Medicine Greenville, Greenville, South Carolina, United States of America*

Introduction:

Specific clinical and demographic risk factors may contribute to improving or worsening neurological functions in acute ischemic stroke (AIS) patients with obstructive sleep apnea (OSA). Research suggests that NIHSS scores greater or less than 7 are a significant predictor of neurological outcomes following a stroke. In this study, we use this model to determine the effect of clinical risk factors on stroke severity and neurological outcomes in the OSA population.

Methods:

Retrospective data for baseline clinical and demographic data from January 2010 to June 2016 in a regional stroke center were analyzed. Of the 5,469 patients identified with AIS, 170 had OSA. Odds ratios (ORs) and 95% confidence intervals were used to determine which clinical factors influenced the likelihood of presenting with improving (NIHSS score \leq 7) or worsening (NIHSS score $>$ 7) neurological function.

Results:

Adjusted multivariate analysis demonstrated that in the AIS population with OSA, atrial fibrillation (OR=3.36, 95% CI, 1.289-8.762, p=0.013) and changes in ambulatory status (OR=2.813, 95% CI, 1.123-7.041, p= 0.027) showed an association with NIHSS score $>$ 7 while being Caucasian (OR= 0.214, 95% CI, 0.06-0.767, p=0.018) was associated with NIHSS score \leq 7.

Conclusions:

In patients with OSA, atrial fibrillation and changes in ambulatory status are associated with worsening neurological function while identifying as Caucasian is associated with improving neurological function after an acute ischemic attack. We believe this study provides information into the preventative management of AIS in patients with OSA and insight into the neurological recovery within this population.

Keywords: NIHSS, Acute Stroke

Financial Disclosures: The authors had no disclosures.

Grant Support: Fullerton Research Grant

Poster

Single Versus Dual Dose Of Intra-arterial Stem Cell Therapy For Stroke

Roshni Thakkar, Assistant Professor¹, Mitsuyoshi Watanabe, Fellow², Pallab Bhattacharya, Associate Professor³, Chuanhui Dong, Associate Professor¹, Ami Raval, Associate Professor¹, Aisha Khan, Executive Director⁴, Joshua Hare, Professor⁴, Dileep Yavagal, Professor¹

¹Department of Neurology, Miller School of Medicine, University of Miami, Miami, Florida, United States of America; ²Department of Neurosurgery, Jikei University School of Medicine, Tokyo, Japan; ³National Institute of Pharmaceutical Education and Research, Ahmedabad, India; ⁴Interdisciplinary Stem cell Institute, University of Miami, Miami, Florida, United States of America

Introduction:

Pre-clinical studies have shown great promise in the use of cell-based therapies for stroke. Intraarterial (IA) delivery directs the cells to the injured brain, is minimally invasive and widely available, making it attractive for clinical translation. Our group and others have shown the safety and efficacy of IA Mesenchymal Stem Cell (MSC) treatment in a rodent stroke model at 24 hours post-reperfusion. The optimal timing of a single dose of IA MSC is unknown. Also, whether an additional dose will lead to greater benefit and the optimal timing of the second dose need to be determined for successful translation of IA MSC to clinic. The objective of this study is to determine if dual dose IA-MSC treatment is superior to single dose and find the optimal timing for the second dose.

Methods:

We used a reversible middle cerebral artery occlusion (rMCAO) model for stroke in rats. IA-MSCs were administered using a PE-10 catheter at 1, 2 and 4 day after stroke as single dose. Based on the results of the first experiment, dual doses were given at 1-4, 1-6 and 1-15 day. Behavioral analysis of rotarod, neurological deficit scoring and stroke volume were determined at 30 days after treatment.

Results:

Single dose IA-MSC at 1day was superior ($p=0.02$, 0.01 , 0.04) to single dose given on day 2 and no benefit was seen when given on day 4. Among the dual dose groups, 1-6 day after stroke showed significant improvement in neurodeficit score and stroke volume ($p=0.007$, $p=0.03$). However, the percentage increase in improvement in 1-6day (dual) was much higher than that observed in 1day (single) group (Fig 1). Detailed results will be presented at the meeting.

Conclusions:

The results of our study indicate that 1day after stroke is optimal for single dose of IA-MSC. An additional dose at 6days after stroke enhances the effect of IA-MSC in aiding symptomatic recovery and stroke lesion reduction. In summary, our findings contribute to understanding of the benefit of dual dose of IA MSC for translation to the clinic.

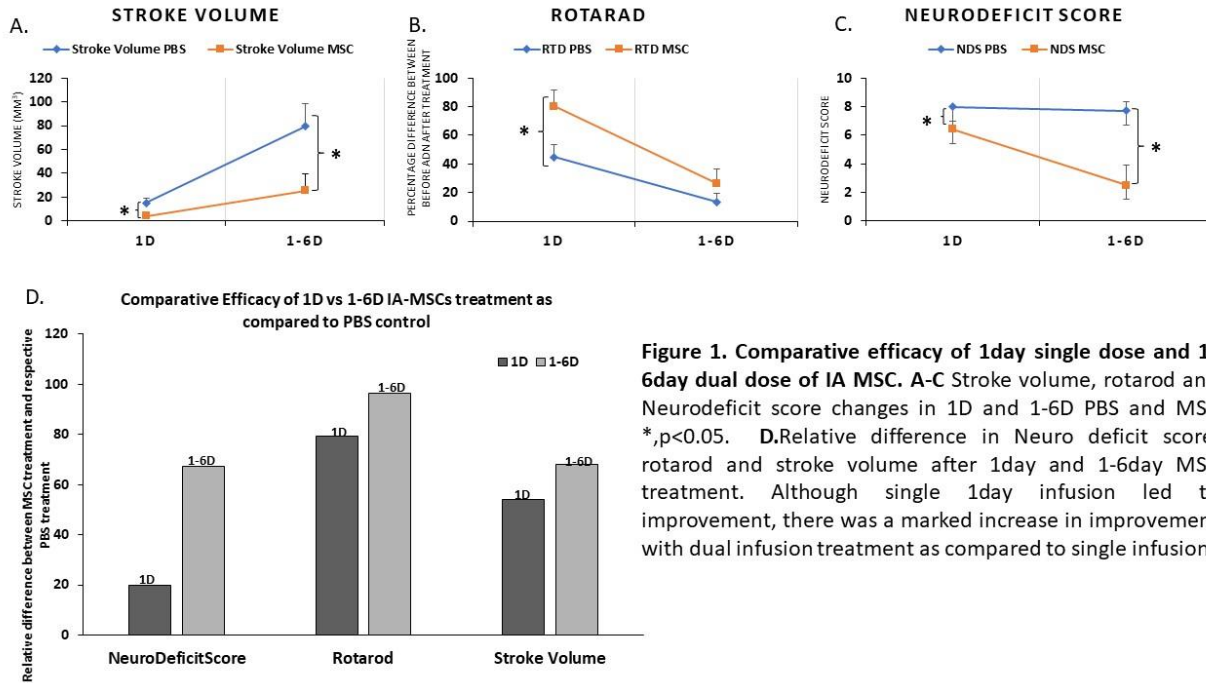


Figure 1. Comparative efficacy of 1day single dose and 1-6day dual dose of IA MSC. A-C Stroke volume, rotarod and Neurodeficit score changes in 1D and 1-6D PBS and MSC *, $p < 0.05$. D. Relative difference in Neuro deficit score, rotarod and stroke volume after 1day and 1-6day MSC treatment. Although single 1day infusion led to improvement, there was a marked increase in improvement with dual infusion treatment as compared to single infusion.

Keywords: Acute Stroke, Basic/Translational Vascular Science, Endovascular Therapy, Intra-Arterial Therapy, Stem Cell Therapy

Financial Disclosures: The authors had no disclosures.

Grant Support: None.

Poster

Cognitive Improvement after Global Ischemia is Not Driven By BDNF-Mediated Neurogenesis in Rats

Holly M Stradecki-Cohan, M.D., Ph.D.¹, Charles H Cohan, Ph.D.², Nathalie Khoury, Ph.D.², Miguel A Perez-Pinzon, Ph.D.²

¹University of Miami/Jackson Memorial Hospital, Miami, Florida, United States of America; ²University of Miami Miller School of Medicine, Miami, Florida, United States of America

Introduction:

Previously, we showed that a 5-day period of aerobic exercise 3 days after a focal or global ischemia improved contextual memory more than 2 weeks later in Sprague-Dawley rats (Stradecki-Cohan et al., 2017); however, no clear molecular mediators were identified. The dentate gyrus is necessary for contextual memory (Wiltgen et al., 2006) and the site of exercise-induced neurogenesis (Brown et al., 2003). This neurogenesis is brain-derived neurotrophic factor (BDNF)-mediated as genetic deletion of the downstream TrkB receptor (Li et al., 2008) or hippocampal expression of BDNF interfering RNA (Taliaz et al., 2010) prevents exercise-induced neurogenesis. Due to our findings that exercise enhanced contextual fear conditioning, we reasoned that this was possibly due to enhanced neurogenesis driven by BDNF signaling.

Methods:

All experiments were approved by our institution's IACUC. Rats were acclimated to human touch and treadmill usage 8 days before surgery. Rats underwent a sham or global cerebral ischemia (asphyxia cardiac arrest) surgery. After three days of recovery, rats were subject to no exercise (0 m/min) or aerobic exercise (10 m/min) for 5 days. This created three experimental groups: sham surgery + no exercise; ischemia surgery + no exercise; and ischemia surgery + aerobic exercise. Animals were then used to analyze BDNF signaling or neuronal proliferation. For BDNF experiments, plasma was obtained immediately after daily exercise; 24 hours after the last exercise session, hippocampi were harvested for PCR and western blot analysis. For neurogenesis examination, animals were injected with bromodeoxyuridine (BrdU) daily post-exercise and hippocampi were imaged 17 days later (timepoint of improved contextual memory) with appropriate staining methods (including NeuN staining for neuronal identification).

Results:

There was no significant difference in plasma BDNF levels between groups ($p=0.1160$). Hippocampal mRNA expression of BDNF was not elevated after completion of exercise training ($p=0.7802$) nor was there any significant difference in downstream of BDNF signaling (i.e. arc, NR1, NRB2A, and NRB2B; $p=0.8638$, $p=0.6187$, $p=0.6642$, and $p=0.3861$ respectively). However, mature BDNF protein expression in the hippocampus was significantly elevated in the ischemia + exercise group versus the other two groups ($p=0.0005$). This increase was not accompanied downstream differences in TrkB activation ($p=0.9086$) or due to enhanced transcription of tPA ($p=0.2158$) which promotes the conversion of pro-BDNF to mature BDNF. In regard to neurogenesis, the number of BrdU+NeuN+ cells in the dentate gyrus is significantly increased after ischemia ($p=0.0002$) but not further increased by exercise.

Conclusions:

Overall, we examined the canonical pathway of BDNF signaling as a possible mechanism of improvement in contextual memory with a brief period of exercise after brain ischemia. Here, we found that the delayed benefits of a brief period of early exercise is not driven by BDNF-mediated neurogenesis. Therefore, further studies into the mechanism of improvement are necessary to allow for development of targeted therapeutics. Doing so will allow improved brain function and therefore quality of life in survivors of brain ischemia.

Keywords: Acute Stroke, Basic Sciences, Ischemic Stroke, Pathophysiology

Financial Disclosures: The authors had no disclosures.

Grant Support: AHA Predoctoral Fellowship (15PRE2236000): Physical Exercise mechanisms that Facilitate Cognitive Recovery after Global Cerebral Ischemia (HM Stradecki-Cohan) NIH NINDS (2R01NS045676-05A2): Mechanisms of Neuroprotection Against Cardiac Arrest (MA Perez-Pinzon)

Poster

History of Stroke Increases Mortality among Middle-aged Patients with COVID19- The Louisville COVID19 Study

Naga Krishnakanth Madireddy, M.D.¹, Saurav Das, MD², Amr Aboelnasr, MD¹, Meredith Cahill, MPHc¹, Stephen Furmanek, MS, MPH¹, Ozan Akca, MD²

¹University of Louisville School of Medicine, Louisville, United States of America; ²Washington University School of Medicine, St Louis, Missouri, United States of America

Introduction:

The global coronavirus disease (COVID19) pandemic has been reported to cause high mortality in patients with past history of stroke. The objective of this study was to retrospectively evaluate mortality patterns among patients with past history of stroke/TIA who were hospitalized with COVID19 at eight different hospitals in the city of Louisville, Kentucky.

Methods:

Patient charts from the Louisville COVID19 Study database met inclusion criteria if the hospitalization occurred between the dates March 15 to June 20, 2020. Groups with and without past history of stroke were compared for significant events in the clinical course (e.g., Myocardial Infarction, Deep Vein Thrombosis, Pulmonary Embolism, acute stroke, cardiac arrest and mortality) using chi-square test. The mortality between these groups were compared stratified by age groups <18, 18-35, 36-65, 66-85 and >86 yrs.

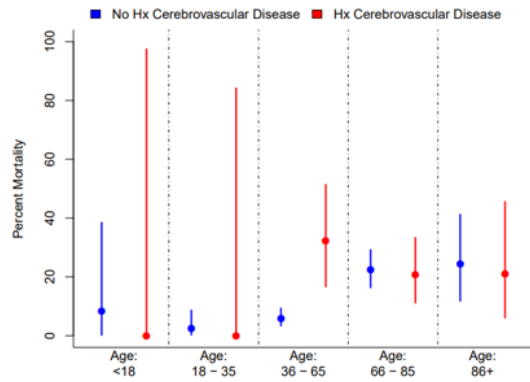
Results:

692 COVID19 positive patients were admitted during this period, 93 (13%) had a past history of stroke. The frequency of significant events in clinical course is compared in figure-1. 12 patients (2%) in the group with no history of stroke experienced a cardiac arrest vs 7 patients (8%) in the group with no history of stroke, $p=0.007$. The mortality among patients with past history of stroke, 26 (28%) was higher than patients without past history of stroke, 85 (14%); $p=0.001$. Patients <35 years of age experienced <10% mortality while those >35 years of age had mean mortality of 25%. Among middle aged patients (36-65 years group), the mortality was six times higher (30%) when there was a past history of stroke compared to no past history of stroke (5%). The mortality among older patients (>66 years) was similar within these groups (~20%), figure-1.

Conclusions:

In this cohort of COVID-19 patients in our registry, a history of past stroke confers a high risk of mortality, which is especially high among middle aged patients. These results beckon further analyses to identify underlying pathophysiological mechanisms and biomarkers related to such age-specific mortality.

Clinical Course	No History of Stroke (n=599,%)	History of Stroke (n=93,%)	P Value
Acute Stroke/ TIA	4 (1)	3 (3)	0.084
Myocardial Infarction	9 (2)	4 (4)	0.152
Deep Vein Thrombosis	6 (1)	3 (4)	0.159
Pulmonary Embolism	7 (1)	3 (3)	0.282
Cardiac Arrest	12 (2)	7 (8)	0.007
Mortality	85 (14)	26 (28)	0.001



Keywords: Acute Stroke, Cerebrovascular Disease, Stroke, Epidemiology, Pathophysiology

Financial Disclosures: The authors had no disclosures.

Grant Support: None.

Poster

Heparin Induced Thrombocytopenia Type II in Aneurysmal Subarachnoid Hemorrhage Patients: Institutional Report and Literature Review

Boyi Li, BA¹, Erick Martinez, BS¹, Zafar Karimov, BS¹, Matthew McIntyre, MD², Mohamed Halabi, BS¹, Andrew Long, BS¹, Alexander Van Hoof, BS¹, Adil Afridi, BS¹, Christian Bowers, MD³, Simon Hanft, MD⁴, Zeeshan Hafeez, MD⁴, Justin Santarelli, MD⁴, Jared Pisapia, MD⁴, Carrie Muh, MD⁴, Rachana Tyagi, MD⁴, Stephan Mayer, MD⁴, Chirag Gandhi, MD, FACS, FAANS⁴, Fawaz Al-Mufti, MD⁴

¹New York Medical College, Valhalla, New York, United States of America; ²Oregon Health and Sciences University, Portland, Oregon, United States of America; ³University of New Mexico, Albuquerque, New Mexico, United States of America; ⁴Westchester Medical Center, Valhalla, New York, United States of America

Introduction:

Heparin induced thrombocytopenia Type II (HIT II) is a potentially fatal complication of prophylactic heparin treatment that poses increased risk for thromboembolic complications. The current literature on incidence and outcomes of HIT II in aneurysmal subarachnoid hemorrhage (aSAH) patients remains inconsistent and scarce, with notable discrepancies in definition of diagnosis. This study aimed to report our institution's incidence and outcomes of HIT II in aSAH patients, as well as review existing literature on HIT II in the aSAH and ICU populations.

Methods:

We performed a retrospective cohort study at a quaternary academic medical center between June 2014 and July 2018. All patients had aSAH confirmed by digital subtraction angiography. Diagnosis of HIT II was determined by positive results on heparin PF4-platelet antibody ELISA test (anti-PF4) and serotonin release assay (SRA). Literature review was conducted via PubMed and Google Scholar databases.

Results:

204 patients met criteria for inclusion in our study. Seven patients (7/204, 3.5%) met clinical suspicion for HIT II and underwent laboratory testing. HIT II incidence was confirmed 2/204 (0.98%) of patients. These two patients had an average 4T score of 7 ± 1 in contrast to 1.0 ± 0.1 in the non-HIT II patients. Outcomes in HIT II patients included higher BMI, longer hospital and ICU length of stay (LOS), as well as greater rate of thromboembolic complications, vasospasm and delayed cerebral infarction (DCI) than non-HIT II patients.

Conclusions:

We are the only group to report HIT II incidence in aSAH using both anti-PF4 and SRA tests, whereas prior studies used only clinical criteria and/or anti-PF4. Our institution's report of HIT II incidence in aSAH patients is significantly lower than previous reports of average 7.8% HIT II incidence in this population (n=1,875), and more closely parallels the average 0.9% HIT II incidence in the general and surgical ICU setting (n=37,493), suggesting the possibility of overdiagnosis in aSAH patients. Consistency in HIT criteria for diagnosis presents an area for improved management. Widely-accepted ACCP clinical diagnostic criteria in conjunction with the 4T scoring system, heparin PF4-platelet antibody ELISA test,

and serotonin release assay should be the gold standard of clinical diagnosis and management of HIT II in aSAH patients.

Keywords: Subarachnoid Hemorrhage, SAH, Antiplatelet

Financial Disclosures: The authors had no disclosures.

Grant Support: None.

Poster

Evaluation of Neurovascular Emergencies by Safety Net Status: Insights from a national administrative database

Deep Pujara, MBBS, MS, MPH¹, Haris Kamal, MD², Osman Mir, MD³, Bhanu Gogia, MD⁴, Sujan Reddy, MD, MPH¹, Kaushik Parsha, MD MPH¹, Faris Shaker, MBChB¹, Clark Sitton, MD¹, Anjail Sharrief, MD¹, Kartikram Raghuram, MD¹, Prashant Rai, MD¹, Ameer Hassan, DO⁵, Amrou Sarraj, MD¹

¹UT McGovern Medical School, Houston, Texas, United States of America; ²New York Medical College, New York, New York, United States of America; ³New York University, New York, New York, United States of America; ⁴UT Medical Branch - Galveston, Galveston, Texas, United States of America; ⁵The University of Texas Health Science Center at Rio Grande Valley, Harlingen, Texas, United States of America

Introduction:

Safety-net hospitals (SNH) are important to US Healthcare, carrying increased burden of care for patients without sufficient healthcare coverage. However, safety net status is frequently associated with perceived reduction in quality of care. We assessed and compared the care metrics in Ischemic stroke (AIS), intracerebral hemorrhage (ICH) and aneurysmal subarachnoid hemorrhage (aSAH) by safety net status.

Methods:

Using National Inpatient Sample, an administrative database containing a 20% sample of all inpatient admissions in the US, patients admitted with AIS, ICH or aSAH in 2012-2014 were identified using ICD-9-CM diagnosis codes. SNH were identified using previously validated definition of top quartile of hospitals with overall inpatient burden of uninsured and Medicaid insured patients. ICD-9-PCS procedure codes were used to identify type of care including EVT and IV-tPA for ischemic stroke, decompressive craniectomy in ICH and surgical clipping and coiling for patients with aneurysmal SAH. Outcomes including in-hospital deaths, lengths of hospital stay (LOS), cost of hospitalization and institutionalized care utilization were assessed using multivariable linear and logistic regression models, adjusted for patient demographic, comorbidities (using Elixhauser Comorbidity Index), hospital level characteristics and interventions.

Results:

Of 418,108 AIS patients, 113,736(27.2%) were treated at SNHs; who were younger(67(56-79) vs 60(72-82), $p<0.001$) & had significantly higher proportion of African Americans(23.8% vs 13.9%, $p<0.001$) and Hispanics(14.9% vs 5.7%, $p<0.001$). Rates of IV-tPA(4.8% vs 4.8%, $p=0.69$) were similar, but thrombectomy utilization was higher(0.92% vs 0.78%, $p<0.001$) in SNHs. In-hospital mortality(10.8% vs 9.8%, aOR: 1.09(1.07-1.12), $p<0.001$), LOS (5(3-9) vs 4 (2-8), $p<0.001$) & average cost of hospitalization(\$34k (19k-69k)vs \$44k(24k-90k, $p<0.001$) were significantly higher in SNH, whereas institutionalized care utilization was significantly lower(38.9% vs 42.4%,aOR: 0.88(0.87-0.90), $p<0.001$). Of 62,176 ICH patients, 18,457(30%) were treated at SNHs; who were younger(65(53-77) vs 70(58-81), $p<0.001$) & had higher proportion of African Americans(22.5% vs 13.7%, $p<0.001$) and Hispanics (15.4% vs 6.8%, $p<0.001$). SNHs performed craniectomy more frequently (9.2%vs 8.2%, $p<0.001$), but non-SNH hospitals had higher proportion of procedures performed within first 24 hours (SNH:37.2%vsNon-SNH:41.0%, $p=0.008$). In-hospital mortality (SNH:22.9%vsNon-

SNH:22.3%,aOR:1.11(1.03-1.20), $p<0.001$) and median cost of hospitalization (SNH:\$60k(29k-135k) vs Non-SNH:\$47k(22k-104k),adj. increase of \$ 9k(4k-14k), $p<0.001$) were significantly higher. Hospital stay(SNH:6(3-12)vs Non-SNH:5(3-10), $p<0.001$) was longer, whereas Institutionalized care utilization (SNH:41.5%vs Non-SNH:44.0%, $p<0.001$) was lower.

Of 22,926 aSAH patients, 7,352(32%) SNH patients were younger(58(47-70)vs 61(50-74), $p<0.001$) and had higher proportion of African-Americans(19.0%vs13.0%, $p<0.001$) and Hispanics (16.5%vs8.7%, $p<0.001$). Rates of surgical clipping(SNH:11.9%vs Non-SNH:8.3%, $p<0.001$) were higher in SNH, whereas rate of coiling was not statistically significantly different(SNH:19.5%vs Non-SNH:20.3%, $p=0.62$). In-hospital mortality(SNH:22.0%vs Non-SNH:21.6%,aOR:1.09(1.02-1.18), $p=0.016$) was higher, but average cost of hospitalization (SNH:\$118k(45k-252k)vs Non-SNH:\$97k(35k-232k),decrease of \$10k(4k-16k), $p=0.002$) was significantly lower. Rates of delayed coiling(>72 hours) (SNH:15.0%vs Non-SNH:12.6%, $p=0.041$)and LOS (SNH:9(3-16)vs Non-SNH: 8(3-15), $p<0.001$) were higher, whereas discharge to institutionalized care was lower in SNH (SNH:29.7%vs Non-SNH:31.3%, $p=0.014$).

Conclusions:

Safety-net hospitals (SNH) care metrics demonstrated several deficits across utilization, outcomes and cost measures in patients with neurovascular emergencies, while demonstrating better utilization of EVT for AIS and clipping for aSAH. Further exploration into reasons for specific care metrics deficits pertaining to SNH may provide insights into improving care for neurovascular emergencies.

Keywords: Cerebrovascular Disease, Acute Ischemic Stroke Intervention, Subarachnoid Hemorrhage, Intracerebral Hemorrhage

Financial Disclosures: The authors had no disclosures.

Grant Support: None.

Poster

FAST TRACK tPA: Early de-escalation of clinically stable post-tPA patients

Alexander T Clark, B.A.¹, Kavita Shah, MD², Shashvat Desai, MD³, Ashutosh Jadhav, MD PhD²

¹University of Pittsburgh School of Medicine, Pittsburgh, Pennsylvania, United States of America; ²Barrow Neurological Institute and UPMC Stroke Institute, Pittsburgh, Pennsylvania, United States of America;

³Barrow Neurological Institute, Pittsburgh, Pennsylvania, United States of America

Introduction:

Current guidelines recommend high-acuity stroke care for 24 hours after treatment with IV tPA to monitor neurological status and key physiologic variables; however, recent data suggests that early neurologic decline (END) and symptomatic intracranial hemorrhage (sICH) occurs in most clinically stable individuals within 12 hours of IV tPA, supporting earlier de-escalation of higher acuity monitoring. 1,2,3 Reducing frequency of neurological checks in stable patients may be a more pragmatic approach particularly in the COVID-19 era. In this study, we prospectively evaluated clinically stable post-IV tPA patients who were transferred from an ICU between 12 – 24 hours of tPA administration.

Methods:

We performed a prospective analysis of AIS receiving IV tPA based on AHA/ASA guidelines. We included those that presented within 4.5 hours of last seen well (LSW), NIHSS < 10, without large vessel occlusion (LVO) or flow-limiting stenosis (FLS) on non-invasive angiographic imaging. Patients must have maintained NIHSS < 10, did not require intravenous anti-hypertensive medications, did not have hemodynamic and or respiratory concerns, and have had a 12-hour post-tPA CTH or MRI that did not demonstrate hemorrhage. Outcomes included END (≥4-point worsening of NIHSS at 24 hours) from any cause, parenchymal hemorrhage (PH1 or PH2), and symptomatic intracranial hemorrhage (sICH; ≥4-point NIHSS worsening with presence of hemorrhage).

Results:

Forty-two patients met inclusion criteria and were included in the study. Mean age was 63 +/- 11 years and 59.6% (25) were males. 40.4% (17) of patients received early de-escalation (fast track group). The fast track group was comparable in baseline demographic and clinical characteristics. The rate of END (11.7% vs 8%, p=0.68) were comparable between patients in the fast track group versus the non- fast track group. No patients were observed to have Ph-1/2 and sICH in the fast track and non-fast track groups.

Conclusions:

By introducing a de-escalation protocol, post-tPA patients could be safely fast tracked through the ICU with reduced need for higher acuity monitoring without higher rates of complications compared to patients undergoing routine post-tpa ICU monitoring.

Keywords: Acute Stroke, Acute Ischemic Stroke Intervention, TPA, Intracerebral Hemorrhage

Financial Disclosures: The authors had no disclosures.

Grant Support: None.

Poster

Adaptive approach to endovascular management of large vessel occlusion during the COVID-19 pandemic

Borna E Tabibian, MD¹, Sasha Howell, MD¹, Ekatarina Bakradze, MD¹, Mark Harrigan, MD¹

¹University of Alabama at Birmingham, Birmingham, Alabama, United States of America

Introduction:

The COVID-19 pandemic has resulted in unprecedented strain on the health care system. An adaptive strategy for the handling of thrombectomy for patients with large vessel occlusion has evolved at our center to optimize patient care while also minimizing risk of virus transmission. The purpose of this study was to evaluate the effects of the new thrombectomy protocol by comparing thrombectomy times and patient outcomes during the pandemic and pre pandemic period.

Methods:

A retrospective cohort study was conducted on patients who underwent emergent thrombectomy from April 4th, 2020 to August 25th, 2020 (pandemic period) and between December 2nd, 2019 to March 28th, 2020 (pre-pandemic period). The new protocol centered on a standardized approach to airway management in patients considered 'high-risk' for infection. An array of patient-specific factors and outcomes were compared between the two groups.

Results:

A total of 126 patients were included in the study. There was no significant difference in door-to-recanalization or other time parameters between the two groups (138 min during the pandemic vs. 129 min pre-pandemic; $p=0.37$). However, outcomes measured as discharge modified Rankin Scale (mRS) were worse for patients during the pandemic (mRS < 2, 10/58; 17.2% during pandemic vs. 24/68; 35.3% pre-pandemic, $p=0.02$). No neurointerventional providers have been found to contract COVID-19.

Conclusions:

Our approach to mechanical thrombectomy during the COVID-19 era was associated with similar recanalization rates but worse clinical outcomes compared to pre pandemic period. Further studies are necessary to identify factors contributing to worse outcomes during this ongoing pandemic.

Comparison of stroke management time intervals and outcomes			
	Pre-pandemic (n=68)	Pandemic (n=58)	p value
Door to code stroke interval*	12	7	0.3
Door to imaging interval*	15	12	0.38
Door to puncture interval*	79	90	0.07
Door to first pass interval*	104	129	0.07
Door to recanalization interval*	129	138	0.37

Puncture to recanalization interval*	40	44	0.91
LKW to Recanalization interval*	487	481	0.93
Number of patients with TICl score ≥ 2^b	57(83.8%)	50(86.2%)	0.73
Number of patients with discharge mRS ≤ 2	24(35.3%)	10(17.2%)	0.02
Number of patients with favorable disposition**	40(58.8%)	35(60.3%)	0.6
Mortality	10(14.7%)	10(17.2%)	0.576

*values reported in minutes; **defined as discharge to home or inpatient rehabilitation

LKW: last known well, TICl: thrombolysis in cerebral infarction, mRS: modified Rankin scale

Keywords: Door To Groin Puncture, Acute Ischemic Stroke Intervention, Mechanical Thrombectomy, Recanalization, General Anesthesia

Financial Disclosures: The authors had no disclosures.

Grant Support: None.

Poster

Dyna CT Effectively Evaluates the Presence of Intracranial Hemorrhage Immediately following Mechanical Thrombectomy

David Dornbos III, MD¹, Violiza Inoa, MD¹, Julie DiNitto, PhD², David Martineau, MD³, Joseph Sullivan, MD³, Jacqueline Angel, MD⁴, Vikki Nolan, DSc, MPH⁵, Adam S Arthur, MD, MPH¹, Daniel Hoit, MD¹, Christopher Nickle, MD¹, Nitin Goyal, MD¹, Lucas Eljovich, MD¹

¹Semmes-Murphey Clinic, University of Tennessee Health Science Center, Memphis, Tennessee, United States of America; ²Siemens Medical Solutions; University of Tennessee Health Science Center, Memphis, Tennessee, United States of America; ³Mid South Imaging, Baptist Memorial Hospital, Memphis, Tennessee, United States of America; ⁴University of Tennessee Health Science Center, Memphis, Tennessee, United States of America; ⁵University of Memphis School of Public Health, Memphis, Tennessee, United States of America

Introduction:

Despite the efficacy of thrombectomy for ischemic stroke secondary to large vessel occlusion, the risk of symptomatic intracranial hemorrhage (ICH) approaches nearly 5%, and identification of potential ICH is critical. To this end, Syngo Dyna computed tomography (Dyna CT) imaging software (Siemens Medical Solutions, Malvern, PA) can be used immediately following the procedure to evaluate for potential ICH. While this scan provides image quality similar to that of a conventional CT, we sought to evaluate the accuracy and reliability of Dyna CT images in comparison to conventional post-operative CT and MR imaging.

Methods:

Twenty-six consecutive patients undergoing thrombectomy were enrolled between October 2016 and December 2016. A Dyna head CT (20 second, 70 kV) was performed immediately following the procedure. A post-procedural CT or MRI was obtained approximately 24 hours later. Patient characteristics and procedural metrics were collected. Two blinded, independent neuroradiologists evaluated the Dyna CT, post-procedural CT, and MR imaging, identifying ICH, stroke, and presence of subarachnoid contrast. Baseline characteristics and procedural metrics were assessed with descriptive statistics. Cohen's κ statistic was used to assess inter-rater agreement for each imaging outcome and to compare the Dyna CT to conventional imaging.

Results:

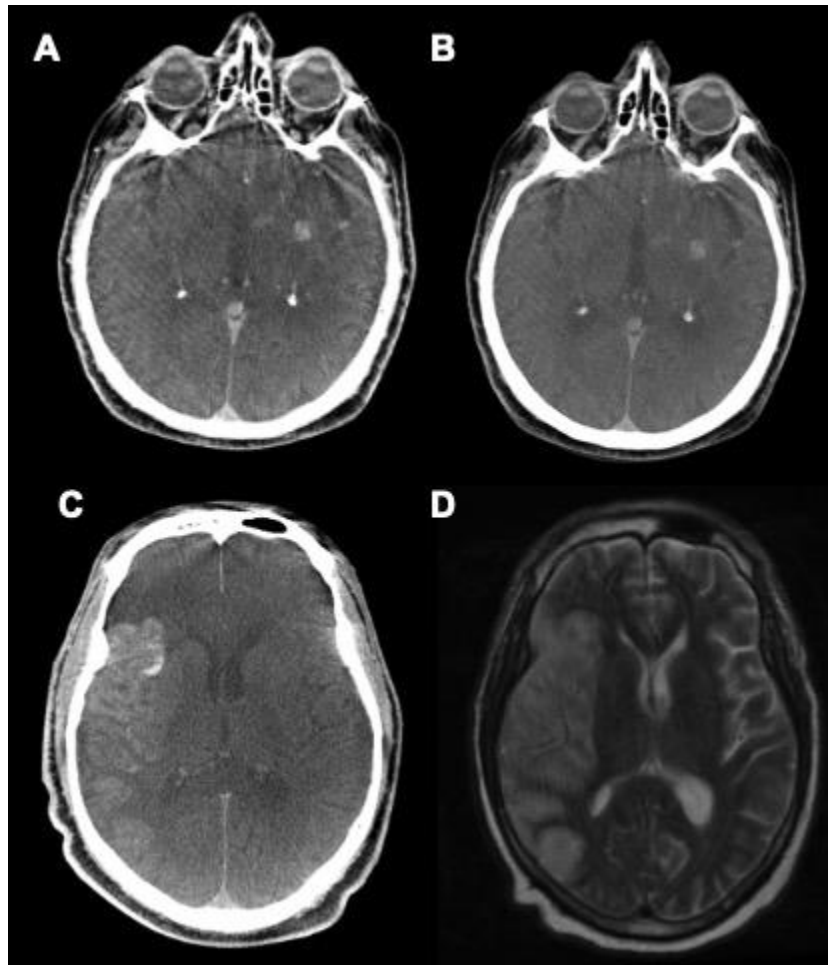
Median age of the patient cohort was 67 (IQR 53, 78) with 50.0% being female. Median NIHSS score on admission was 11.5 (IQR 9, 14.5). The most common occlusion was M1 (54.2%), although 25.0% presented with a tandem occlusion. TPA was administered in 73.1%, Solombra technique was most commonly employed (76.0%), and TICI 2b-3 was achieved in 84.0% of the patients.

Evaluation of the Dyna head CT for the presence of ICH demonstrated a very strong degree of inter-rater reliability (κ 0.896, 95% CI 0.734-1.057), whereas negligible reliability was seen in the determination stroke on the immediate post-procedure Dyna CT (κ 0.149, 95% CI -0.243-0.541). Comparison of ICH evaluation between the Dyna CT (Figure 1A) and post-procedural conventional CT (Figure 1B) revealed modest inter-rater reliability (κ 0.432, 95% CI -0.100-0.965), which did not reach statistical significance.

There was no substantive reliability in the evaluation of ICH between the Dyna CT (Figure 1C) and post-procedural MR imaging (Figure 1D)(κ 0.118, 95% CI -0.345-0.580).

Conclusions:

Following mechanical thrombectomy, Dyna CT provides a robust image quality able to detect the presence of ICH with a high degree of reliability, although the detection of ischemic parenchymal changes is limited.



Keywords: Imaging, Ischemic Stroke, Mechanical Thrombectomy, Diagnostic Neuroradiology, Hemorrhagic Transformation

Financial Disclosures: The authors had no disclosures.

Grant Support: None.

Poster

Predictors of Functional Outcome in MCA M2 Occlusions: Analysis from the STRATIS Registry

Kaustubh Limaye, MD¹, Alicia C Castonguay, PhD², Santiago Ortega-Gutierrez, MD, MSc¹, Hisham Salahuddin, MD², Syed Zaidi, MD², Mudassir Farooqui, MD, MPH¹, Nils Mueller-Kronast, MD³, David Liebeskind, MD⁴, Osama O Zaidat, MD⁵, Mouhammad A Jumaa, MD²

¹University of Iowa, Iowa City, Iowa, United States of America; ²University of Toledo, Toledo, United States of America; ³Tenet Florida, Bonyton beach, United States of America; ⁴UCLA, Los Angeles, United States of America; ⁵St. Vincent Medical Center, Toledo, United States of America

Introduction:

Recent studies have demonstrated an acceptable safety and efficacy profile for mechanical thrombectomy of M2 segment middle cerebral artery occlusions; however, the predictors of clinical outcome in this population are unclear. We sought to evaluate the predictors of functional outcome within a cohort of M2 occlusion from the Systematic Evaluation of Patients Treated With Neurothrombectomy Devices for Acute Ischemic Stroke (STRATIS) Registry.

Methods:

The STRATIS Registry was a prospective, multicenter, non-randomized, observational study of AIS LVO patients treated with the Solitaire stent-retriever as the first-choice therapy within 8 hours from symptoms onset. The M2 population with STRATIS was dichotomized into patients with mRS 0-2 (good functional outcome) versus 3-6 (poor functional outcome). Clinical and angiographic outcomes were also assessed. Multivariate logistic regression was performed to identify predictors of functional outcome for M2 occlusions.

Results:

A total of 153 M2 patients were included, of which 89 (58.2%) had mRS \leq 2 and 64 (41.8%) had mRS $>$ 2. M2 patients with poor functional outcomes were older (74.1 \pm 15.0 years, p=0.007), female (59% versus 42%, p=0.03), had higher rates of hypertension (89% versus 71%, p=0.007), and smoking, higher pre-stroke mRS, higher mean baseline NIHSS (7.4 \pm 4.9 versus 14.8 \pm 4.9, p= 0.001) and lower mean ASPECTS scores (8.3 \pm 1.7 versus 9.0 \pm 1.2, p=0.03). There was no difference between mean onset to puncture times with the groups (231.8 \pm 88.3 versus 222.1 \pm 106.1 minutes, p=0.556); however, those with poor functional outcomes had longer mean puncture to revascularization times (51.3 \pm 27.7 versus 40.8 \pm 24.9, p=0.02). Mean number of passes was higher in the poor functional outcome group (1.8 \pm 1.1 versus 1.4 \pm 0.7, p=0.02). The rate of successful revascularization (mTICI \geq 2b) was lower in the poor functional outcome cohort (83% versus 97%, p=0.003). There was a higher rate of sICH in the poor functional outcome group (9% versus 0%, p=0.007) and a high rate of mortality (36% versus 0%, p<0.001). In a multivariate logistic regression model that included univariate significant predictors age, female gender, hypertension, smoking, pre-stroke mRS, baseline NIHSS, ASPECTS, puncture to revascularization time, balloon guide use, and number of passes; hypertension (odds ratio 0.09, 95% CI 0.02-0.49, p=0.005), pre-stroke mRS (odds ratio 0.41, 95% CI 0.19-0.91, p=0.03), baseline NIHSS (odds ratio 0.88, 95% CI 0.80-0.97, p=0.008), and puncture to revascularization time (odds ratio 0.97, 95% CI 0.95-0.99, p=0.002) were significant in the final model as predictors of functional outcome in M2 occlusions.

Conclusions:

In the STRATIS Registry, patients with M2 occlusions who achieved poor functional outcomes had lower rates of successful revascularization, higher rates of sICH, and of mortality. Independent predictors of clinical outcome in M2 occlusions included hypertension, pre-stroke mRS, baseline NIHSS and puncture to revascularization time.

Keywords: Acute Stroke, Endovascular Therapy, Mechanical Thrombectomy

Financial Disclosures: The authors had no disclosures.

Grant Support: None.

Poster

Carotid Stenosis Management During COVID-19 Era – Best Medical Intervention Alone (CASCOM Study)

Anne Abbott, A/Prof¹, Emilie Nøddeskov Eilersen, Dr², Martin Lawaetz, Dr², Athanasios Saratzis, Dr³, Claude Vaislic, Dr⁴, Alun Davies, Prof⁵, Gregory Lip, Prof⁶, Hannah Gardener, Dr⁷, Bibombe Mwipatayi, A/Prof⁸, Oliseneku Uyagu, Dr⁹, Piotr Myrcha, A/Prof¹⁰, Luca Saba, Prof¹¹, Ankur Thapar, Dr⁵, Pier Luigi Antignani, Prof¹², Alisha Oropallo, A/Prof¹³, Tatjana Rundek, Prof⁷, Saeid Shahidi, Prof²

¹Monash University, Melbourne, Australia; ²Zealand University Hospital, Roskilde, Denmark; ³NIHR Leicester Biomedical Research Centre, Leicester, United Kingdom of Great Britain and Northern Ireland; ⁴Hôpital Privé De Parly li - Ramsay Santé, Le Chesnay, France; ⁵Imperial College London, London, United Kingdom of Great Britain and Northern Ireland; ⁶University of Liverpool, Liverpool, United Kingdom of Great Britain and Northern Ireland; ⁷University of Miami Miller School of Medicine, Miami, United States of America; ⁸University of Western Australia | School of Surgery, Perth, Australia; ⁹King Abdullah Medical Complex Jeddah, Jeddah, Saudi Arabia; ¹⁰Medical University of Warsaw, Warsaw, Poland; ¹¹Medical University of Cagliari, Cagliari, Italy; ¹²Vascular Centre, Nuiva Villa Claudia, Rome, Italy; ¹³Department of Vascular Surgery, Northwell Health, Lake Success, New York, United States of America

Introduction:

Carotid endarterectomy (CEA) and carotid stenting (CAS) are often performed for subgroups of patients for whom procedural benefit has not been established in randomised trials and despite evidence of serious procedural risk. Furthermore, there is no current evidence of procedural benefit compared to optimal medical intervention alone (lifestyle coaching and medication) for any individuals. In some places, the COVID-19 pandemic has made it difficult or impossible to perform CEA and CAS. At a minimum, these interventions must be better justified.

Aim/Objectives

1. To measure the rate of ipsilateral stroke, and other arterial disease complications, in individuals with advanced (50-99%) carotid stenosis who, for any reason, are managed using current best medical intervention alone. Reasons for a nonprocedural approach may include insufficient resources caused by the coronavirus pandemic, unproven procedural benefit, anticipated procedural futility and/or net harm, or patient refusal. Hence, we will study patients for whom carotid procedures are not possible or considered unethical.

2. To compare the CASCOM Study rate of ipsilateral stroke for symptomatic patients with that reported in the North American Symptomatic Carotid Endarterectomy Trial (NASCET) and the European Carotid Surgery Trial (ECST), and the CASCOM Study rate of ipsilateral stroke associated with asymptomatic carotid stenosis with that reported in the Asymptomatic Carotid Atherosclerosis Study (ACAS).

Methods:

CASCOM is a prospective cohort study of current best medical intervention alone for stroke prevention. It is also a multi-national, multi-specialty, collaborative, quality assurance and evaluation project. We will separate patients into those who would, and would not, have been eligible for past randomised CEA trials. We plan to study >250 symptomatic patients and >530 asymptomatic patients using 'REDCap' (Research Electronic Data Capture) for case reporting

Results:**Expected Findings and Significance**

In CASCOM we expect at least 50% lowering of the ipsilateral stroke rate compared to that seen with medical intervention alone in past randomised trials. If correct, CASCOM will provide new evidence that past randomised trials of CEA and CAS are outdated and elucidate improved standards for preventing stroke and other arterial disease complications.

Conclusions:

CASCOM study is an excellent opportunity to measure the rate of stroke and other arterial disease complications in symptomatic and asymptomatic individuals with advanced carotid stenosis. Clinicians interested in participating as CASCOM Study investigators are encouraged to contact existing investigators, including those listed in this conference abstract. Information will also be available at www.FACTCATS.org.

Keywords: Carotid, Stroke, Treatment, Atherosclerosis, Carotid Stenting And Angioplasty

Financial Disclosures: Research funding from the National Health and Medical Research Council of Australia

Grant Support: A/Prof Anne Abbott receives fellowship funding from the National Health and Medical Research Council of Australia in support of this study.

Poster

Embolizacion de Aneurisma P1 por carótida interna mediante la comunicante posterior

Lucho E Mendoza, Nweurocirujano Vascular¹, Danny E Fuentes, Neurocirujano², Fiorella L Quequezana, Neurocirujano²

¹EsSalud, Arequipa, Peru; ²EsSalud, Arequipa, Peru

Introduction:

Nuestro propósito es dar a conocer que se puede embolizar un aneurisma cerebral de P1 por carótida interna mediante la comunicante posterior cuando hay persistencia embrionaria carotídeo vertebral con buen resultado clínico-radiológico.

Methods:

El portar un aneurisma cerebral es padecer una enfermedad grave; la morbi-mortalidad por rotura de un aneurisma cerebral es todavía alta. Presentamos el caso clínico de un paciente de 52 años de edad que sufre Ictus; prueba clínica-radiológica: WFNS II Sano II Fisher III, aneurisma del sistema Posterior en su segmento P1 (2.5x7mm) por AngioTEM; se evaluó los dos sistemas arteriales y se optó por el mejor acceso, procedimos a la embolización con bobina de desprendimiento, con buen resultado clínico y angiográfico.

Palabras clave: Aneurisma intracraneal, embolización terapéutica

Results:

Mujer de 52 años de edad, sin antecedentes contributarios, transferido a emergencia del hospital, por haber presentado ICTUS hace 36hs Clinica-Radiologicamente: EG: 12 WFNS II Sano II Fisher III, Aneurisma del complejo del sistema Posterior a nivel de su segmento P1 (2,5x7 mm) por Agio TEM. Se procedió a estudio y tratamiento Endovascular con evidencia de aneurisma indicado con persistencia embrionaria carótida-basilar (presencia de una arteria comunicante posterior prominente) (Figura 2 ^{a, b} flecha roja)

Se evaluó los dos sistemas arteriales (foto 3 ^a -3 ^b) y se optó por el mejor acceso, procediendo a la embolización con coil de desprendimiento de Guglielmi (foto: 5-6-7) por la arteria carótida interna, mediante la comunicante posterior prominente con exclusión adecuada del aneurisma (foto 7-8)

Conclusions:

Se puede embolizar un Aneurisma cerebral de P1 por carótida interna mediante la comunicante posterior cuando hay persistencia embrionaria carotídeo vertebral

Concluimos y consideramos que se haga una buena evaluación anatomo vascular geométrico tridimensional in situ, para el éxito de la cirugía Endovascular.

El tratamiento óptimo no está en polemizar el elegir entre coiling o clipaje, sino en utilizar estas dos armas en contra de nuestro mayor enemigo: el aneurisma.

En la literatura no encontramos embolización de aneurisma P1 por vía carótida interna

Embolización de Aneurisma P1 por carótida interna mediante la comunicante posterior

Resumen

El portar un Aneurisma Cerebral es padecer una enfermedad grave; la morbi-mortalidad por rotura de un aneurisma cerebral es todavía alta. Presentamos el caso clínico de una paciente de 52 años de edad que sufre Ictus; evaluada clínica-radiológicamente: WFNS II Sano II Fisher III, aneurisma del del sistema Posterior en su segmento P1 (2.5x7mm) por AngioTEM; se evaluó los dos sistemas arteriales y se optó por el mejor acceso, procedimos a la embolización con coil de desprendimiento, con buen resultado clínico y angiográfico.

Palabras clave: Aneurisma intracraneal, embolización terapéutica

Introducción:

Nuestro propósito es dar a conocer que se puede embolizar un Aneurisma cerebral de P1 por carótida interna mediante la comunicante posterior cuando hay persistencia embrionaria carotídeo vertebral con buen resultado clínico-radiológico.

Presentación del caso clínico

Mujer de 52 años de edad, sin antecedentes contributarios, transferido a emergencia del hospital, por haber presentado ICTUS hace 36hs Clínica-Radiológicamente: EG: 12 WFNS II Sano II Fisher III, Aneurisma del complejo del sistema Posterior a nivel de su segmento P1 (2.5x7mm) por Agio TEM. Se procedió a estudio y tratamiento Endovascular con evidencia de aneurisma indicado con persistencia embrionaria carótida-basilar (presencia de una arteria comunicante posterior prominente) (Figura 2^{a, b} flecha roja)

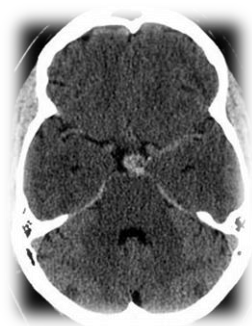

Figura 2

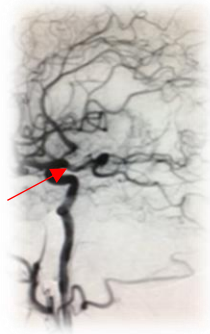

Figura 2^a

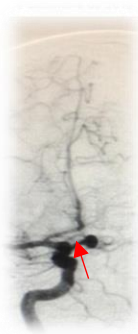

Figura 2^b

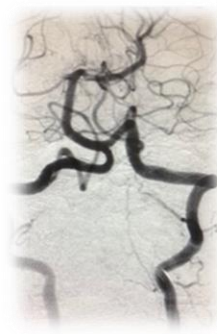


Figura 3^a -3^b

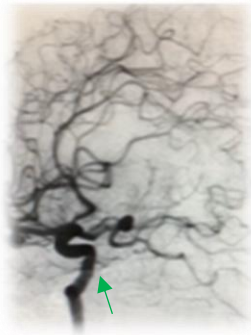


Figura 4

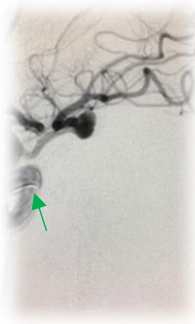


Figura 5

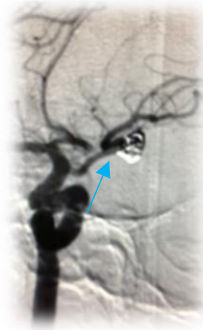

Figura 6

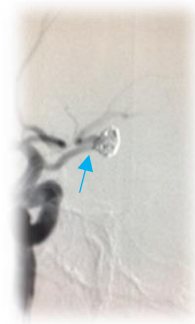

Figura 7

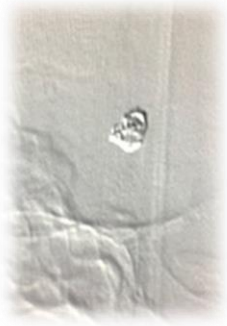

Figura 7

Se evaluó los dos sistemas arteriales (foto 3^a-3^b) y se optó por el mejor acceso, procediendo a la embolización con coil de desprendimiento de Guglielmi (foto: 5-6-7) por la arteria carótida interna, mediante la comunicante posterior prominente con exclusión adecuada del aneurisma (foto 7-8)

Discusión

Los aneurismas de la arteria cerebral posterior y en sus segmentos son raros, en el 0,7% al 2,3% de todos los aneurismas intracraneales

El manejo en la actualidad de los aneurismas cerebrales es Híbrido de acuerdo a los estándares establecidos; nos permite por un lado tener una visión más realista y objetiva del tipo de tratamiento.

Lampert & col. reportaron una morbilidad de 2.8% y una mortalidad, relativa al procedimiento, de 0% en 109 pacientes con aneurismas de circulación posterior tratados con coils.

Conclusión:

Se puede embolizar un Aneurisma cerebral de P1 por carótida interna mediante la comunicante posterior cuando hay persistencia embrionaria carotídeo vertebral

Concluimos y consideramos que se haga una buena evaluación anatómico vascular geométrico tridimensional in situ, para el éxito de la cirugía Endovascular.

El tratamiento óptimo no está en polemizar el escoger entre coiling o clipaje, sino en utilizar estas dos armas en contra de nuestro mayor enemigo: el aneurisma.

En la literatura no encontramos embolización de aneurisma P1 por vía carótida interna

Keywords: Coiling, Endovascular Therapy, Cerebrovascular Disease, Acute Stroke, New Technique

Financial Disclosures: The authors had no disclosures.

Grant Support: None